



ISSN: 2091-2749 (Print)
2091-2757 (Online)

Correspondence

Dr. Rojan Tamrakar
Lecturer, Department of
Orthopaedics
Patan Academy of Health Sciences,
Lalitpur, Nepal
Email: rojantamrakar@gmail.com

Peer reviewed by

Dr. Gehanath Baral

Dr. Sital Bhandari
Patan Academy of Health Sciences

Three lateral divergent pinning for displaced supracondylar humerus fractures in children

Rojan Tamrakar,¹ Pramod Khanal,¹ Balakrishnan M. Acharya,² Nabees Man Singh Pradhan,² Suman Kumar Shrestha²

¹Lecturer, ²Associate Professor

Department of Orthopaedics and Trauma, Patan Academy of Health Sciences, Lalitpur, Nepal

ABSTRACT

Introduction: Cross or two lateral pinnings are the most commonly done procedures for displaced supracondylar humerus fractures in children. A crossed pin is biomechanically stable than lateral pins, but associated with risk of iatrogenic ulnar nerve injury. Recent studies have shown stable fixation with three lateral pin construct. The purpose of this study was to evaluate the efficacy of three lateral divergent pinning for displaced supracondylar humerus fractures.

Methods: Thirty five children with Gartland types III were treated between November 2012 and November 2013. Closed reduction and three lateral divergent pinning was done with image intensifier guidance. Patients were followed up for minimum 6 months. Radiological assessment was done to see union, proper pin placement and loss of reduction. Clinically, patients were assessed by using Flynn criteria.

Results: There were 24 (68.6%) male and 11 (31.4%) female children between 2 to 13 years of age with displaced supracondylar fractures, left side 26 (74.3%) and right nine (25.7%) cases. All were successfully managed with closed reduction and three lateral divergent pins within 2-6 days of injury. One radial and one median nerve palsies sustained at injury recovered spontaneously. No iatrogenic nerve injuries occurred. A comparison of perioperative and final radiographs revealed no loss of reduction. Twenty-seven excellent, five good, two fair and one poor results on Flynn's grading. One patient had a superficial pin-tract infection.

Conclusions: Closed reduction with three lateral divergent pins is safe for stable fixation of displaced supracondylar humeral fractures in children.

Keywords: children, humerus, percutaneous pinning, supracondylar fracture

Plain Language Summary

The study was done to see efficacy of three lateral divergent pinning in displaced supracondylar fracture. Perioperative and final radiographs revealed no loss of reduction. So this method is safe for stable fixation.

INTRODUCTIONS

Supracondylar humeral fracture is the most common type of elbow fracture, accounting for 3% of all pediatric fractures.¹ The standard treatment for displaced fracture is closed reduction and percutaneous pinning.^{1,2} Swenson first described this method.³ Optimal pin configuration and the number of pins required to provide adequate fracture stability to maintain reduction and promote proper union while minimizing the risk of neurovascular injury remain issues of debate. Although biomechanically stable, cross pin construct put the ulnar nerve at risk.⁴ To avoid this complication, many surgeons use only lateral pins to stabilize the displaced fractures. A recent biomechanical analysis showed three lateral divergent pins were as strong as crossed pin and both were stronger than two lateral divergent pins.²

The purpose of this study was to assess the efficacy of lateral divergent pinning using three Kirschner wires for the treatment of displaced supracondylar humeral fractures in children.

METHODS

This was a prospective observational study of management of displaced supracondylar humeral fractures in children at Department of Orthopaedics, Patan Academy of Health Sciences (PAHS), from November 2012 to November 2013. We included children with closed and Type I open (Gustilo Anderson) fractures of Gartland,⁵ types II and III. Exclusion criteria were Gartland type I, open fractures of Gustilo Anderson II and III, fractures associated with vascular injuries, compartment syndrome and patients with previous fractures around the elbow. Informed consent was obtained from the parents.

Surgery was done under general anaesthesia. One dose of intravenous ceftriaxone was given for prophylaxis. Closed reduction was done in a standard technique involving manual traction by surgeon for about two minutes with counter-traction by an assistant, followed by correction of angulatory and rotatory displacements by thumb and fingers manipulation and finally, correction of posterior displacement by thumb pressure over the displaced distal fragment and simultaneously flexion of the elbow. The forearm was then kept in pronation. Reduction was checked in antero-posterior, lateral, internal and external oblique views in image intensifier. When acceptable reduction was observed, the arm was held in maximal flexion

by an assistant. Three Kirschner wires (1.5 to 2 mm) were then inserted from the lateral side. The pin size was subjectively chosen by the surgeon on the basis of the patient's age and size. The K-wires were placed in a divergent manner as possible to stabilize medial and lateral columns. Fracture stability was assessed on image intensifier by screening the fracture under varus/valgus and flexion/extension stresses. The wires were then bent and cut outside the skin, well padded. The limb was immobilized in an above-elbow slab with the elbow at 60 to 90 degrees. All patients were observed in ward for 24 to 48 hours before discharge.

Patients were followed up at the orthopedic outpatient clinic for six months at the interval of 1, 2, 4, 8, 12 and 24 weeks. Clinical inspection of pin tract site and pin migrations was noted during 1st and 2nd weeks. During 4th weeks, plaster slab and pins were removed. Check X-rays was done to see fracture union and alignment. Physiotherapy was started after removal of plaster. As the X-rays were not standardized, we did not measure Baumann's angle. At 8th, 12th and 24th weeks improvement in the range of motion of the elbow was observed. The carrying angles of the injured elbow were measured at 24 weeks. At the final follow up, range of motion and carrying angle of the injured elbow were compared with the contra-lateral normal elbow.

If patients had neurological problems, they were also followed up until the symptoms resolved. We used the Flynn's grading system,⁶ difference in carrying angle (cosmetic factor) and range of motion (functional factor), compared to uninjured elbow. Descriptive analysis was done with SPSS version 11.5.

Table 1. Flynn's Grading System.⁶

Result	Rating	Cosmetic factors: Loss of carrying angle (degrees)	Functional factor: Loss of Motion (degrees)
Satisfactory	Excellent	0-5°	0-5°
	Good	5-10°	5-10°
	Fair	10-15°	10-15°
Unsatisfactory	Poor	>15°	>15°

RESULTS

Among 35 patients, 24 (68.6%) were male and 11 (31.4%) female with left side 26 (74.3%) predominantly involved than the right side nine (25.7%). Age ranged from 2 to 13 years, mean 7.11 years. All 35 were closed

Gartland types III fractures, with 18 types IIIA and 17 IIIB. Twenty three (65.7%) sustained injury due to simple fall from their standing height and remaining 12 (34.3%) had fall from height. Two patients had associated nerve injuries (radial and median nerves) pre-operatively and recovered within 18 and 20 weeks respectively. Fourteen patients (40%) were operated within 48 hours of injury, 10 (28.6%) within 72 hours, and maximum delay was six days. In two patients, we delayed surgery due to gross swelling and blisters around the injured elbow. We used 1.5 mm Kirschner wires in 26 (74.3%) patients and two mm wires in nine (25.7%) patients.

Post-operatively, there was no evidence of ulnar nerve injury. One patient had superficial pin tract infection, which healed with oral antibiotics and dressings. There was no loosening or loss of position of Kirschner wires.

Radiological callus was visible in all patients at the 4th week post-operatively, followed by removal of K-wires. Active mobilization of the elbow joint was started after wires removal under supervision of the physiotherapists. The mean range of elbow motion at 8th week was $9 \pm 4.820^\circ - 121.71 \pm 7.270^\circ$, gradually increased to $2.29 \pm 4.902^\circ - 133.26 \pm 6.740^\circ$ at 12th week and much improved to $0.43 \pm 1.867^\circ - 138.57 \pm 3.720^\circ$ at 24th week, close to the mean range of normal elbows which was $0^\circ - 139.86 \pm 1.717^\circ$. The mean carrying angle at final follow up of the injured elbow was $12.43 \pm 3.165^\circ$ and that of normal elbows was $14.26 \pm 0.657^\circ$. The outcome at 24 weeks was assessed by Flynn criteria, which showed 27 (77.1%) excellent, five (14.3%) good, two (5.7%) fair and 1 (2.9%) poor results. The poor rating of one patient was due to loss of elbow range of motion.

We did not encounter complications like vascular injury, compartment syndrome, myositis ossificans, malunion and non-unions in this series of patients.

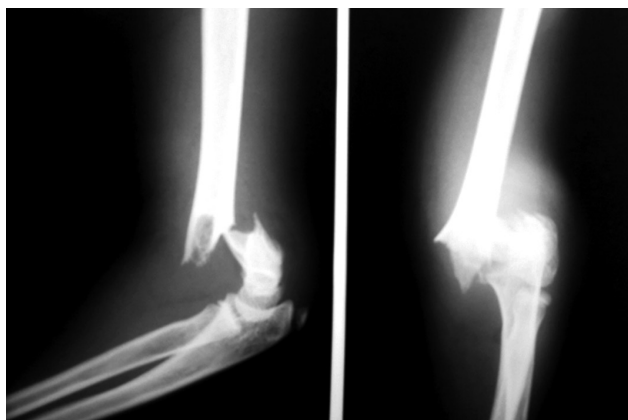


Figure 1. Pre-operative X-rays of elbow – AP and lateral views with displaced humerus fracture in children

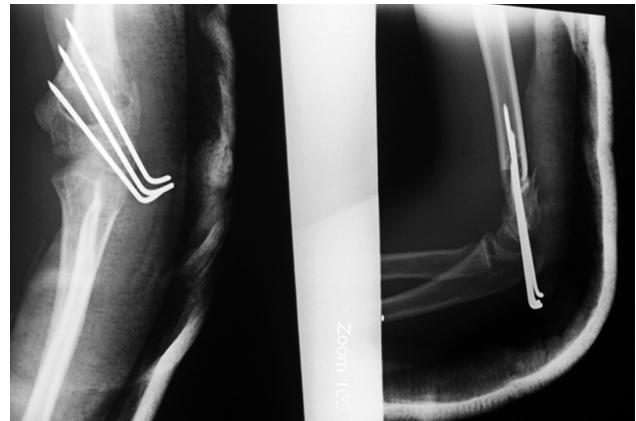


Figure 2. Post-operative X-rays of elbow-AP and lateral views after pinning in displaced humerus fracture in children

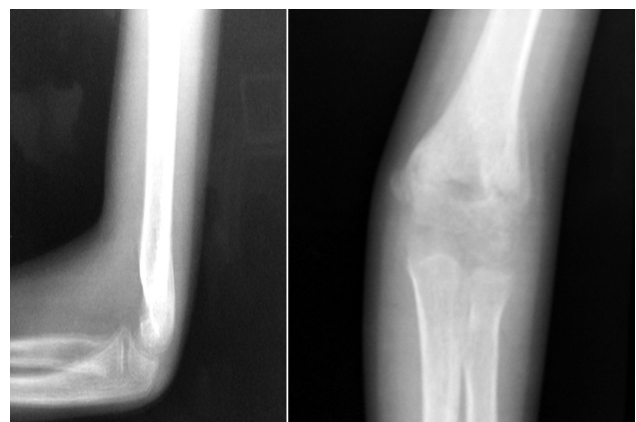


Figure 3. Follow up X-rays of elbow – AP and lateral views, after K-wires removal.

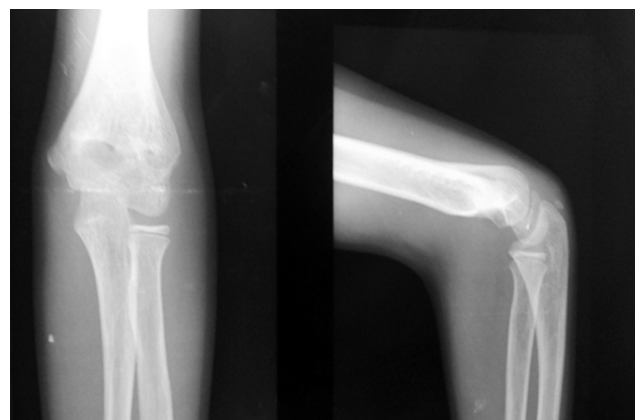


Figure 4. Follow up X-rays of elbow – AP and lateral views, at 6 months

DISCUSSIONS

The main goal in the management of displaced supracondylar humerus fractures are to reduce, immobilize the fracture with a safe creation of a construct that is stable enough to prevent displacements of the

distal fragment and avoid post-operative complications, especially iatrogenic nerve injuries and malunion due to loss of reduction with poor cosmetic and functional outcome. The most debated subject is the optimal pin configurations to hold the reduced fracture. Various pin configurations have been recommended for the treatment of displaced supracondylar humerus fractures on the basis of choice between the stability versus the risk of iatrogenic ulnar nerve injury.⁷⁻¹⁰

The Flynn criteria is widely used for the final assessment in the treatment of supracondylar fracture. According to the Flynn criteria, the final outcome of the treatment in this study showed 34 satisfactory (77.1% excellent, 14.3% good and 5.7% fair results) and only one unsatisfactory result. The unsatisfactory result was due to the poor post-operative range of motion compared to the normal elbow. No one developed cubitus varus deformity. Stephen Paul Guy,⁹ and his colleagues obtained 21 excellent, three good and one poor result among 25 patients on Flynn's grading using three lateral divergent K-wires. Similarly, Lee YH et al,⁷ observed 56 excellent and five good results among 61 patients.

In this study, we treated all 35 patients with three divergent K-wires. Although crossed pinning has been shown more stable than lateral pinning only, the biomechanical studies by Zions et al,⁴ on an adult human cadaver models showed that two crossed pins were 25% more rigid than three lateral pins but without significance ($p > 0.1$). Larson et al,¹¹ in their biomechanical analysis reported three lateral divergent pins were as strong as crossed-pinning and both were stronger than two lateral divergent pins. Some authors believed that the most important factor for biomechanical stability is the maximal separation of the pins at the fracture site, preferably with the greater divergence between the pins to engage both medial and lateral columns.^{7,12,13} With these knowledge, we were very careful while inserting the K-wires, and in all cases we achieved good fixation in divergent manner to engage medial and lateral columns of the distal humerus.

Another important issue with lateral pinning only is the loss of fracture fixation. In this study, we treated all 35 patients with three lateral pinning irrespective of their instability and found no loss of fracture fixation in any cases.

Similar good to excellent results without any loss of fracture fixation with three lateral pinning had shown by Lee YH et al,⁷ as well as Stephen Paul Guy,⁹ and his colleagues. Loss of fixation was found mostly with Gartland type III fractures treated with two lateral pins, but no failures were noted when three pins were used.

Skaggs et al,⁸ reported loss of reduction in eight patients with the use of two lateral pins, whereas no fracture had loss of fixation following the use of three pins. Similarly, another study,¹⁴ revealed loss of reduction in eight (2.9%) of their 279 Gartland type III fractures. Among those eight patients, seven had been treated with two lateral pins and one had been treated with two crossed pins. They found no failure when three lateral pins were used.

Although cross pinning is biomechanically superior to lateral pinning, medial pin placement puts the ulnar nerve at risk, with the reported iatrogenic ulnar nerve injuries ranges from 1.4 to 15.6%.^{15,16} Among 345 extension type supracondylar fractures, Skaggs et al,⁸ reported five percent (seventeen out of 345) of ulnar nerve injuries occurred among crossed pinning group. Woratanarat et al¹⁷ in a meta-analysis of pinning in supracondylar fracture of humerus reported 4.3 times higher risk of iatrogenic ulnar nerve injury in cross pinning compared with lateral pinning. Several authors of retrospective clinical studies have recommended lateral pin fixation to avoid iatrogenic ulnar nerve injury.^{8,12,13,16} As we used only lateral pinning, iatrogenic ulnar nerve injuries had not occurred in all cases. Lee YH et al,⁷ as well as Stephen Paul Guy,⁹ and his colleagues also did not have any iatrogenic nerve injuries in their series using three lateral pinning.

The drawbacks of using three lateral pins are increased chance of pin tract infection,⁸ and technical difficulty of getting three pins in a relatively small area. To address this, studies have recommended the use only of a third pin when the fracture remains unstable after two lateral pins have been used.^{12,18} But we believed that the infection is mainly related to the working environment rather than to the operative technique. We had only one patient with pin tract infection which was superficial infection that healed with oral antibiotics and did not require pin removal. In this study, regardless of degree of instability, we used three lateral divergent pinning with a good success in all our patients.

Few sample size, non-comparative and short duration studies are the limitations of this study. So, large number of cases and comparison with other pin constructs is required to prove its efficacy statistically.

CONCLUSIONS

Based on this study, the closed reduction and percutaneous pinning with three lateral divergent pinning of the displaced supracondylar humeral fractures in children is safe for stable fixation with good functional outcomes without iatrogenic ulnar nerve injury.

REFERENCES

1. Abzug JM, Herman MJ. Management of supracondylar humerus fractures in children: current concepts. *J Am Acad Orthop Surg.* 2012 Feb;20(2):69-77.
2. Skaggs DL, Flynn JM. Supracondylar fractures of the distal humerus. In: Rockwood CA Jr, Wilkins KE, King RE, editors. *Fractures in children.* 7th ed. Philadelphia: JB Lippincott; 2010. p. 496-529.
3. Swenson AL. The treatment of supracondylar fracture of humerus by Kirshner wire transfixation. *JBJS Am.* 1948;30:993-7.
4. Zionts LE, McKellop HA, Hathaway R. Torsional strength of pin configurations used to fix supracondylar fractures of the humerus in children. *J Bone Joint Surg Am.* 1994;76:253-6.
5. Gartland JJ. Management of supracondylar fractures of the humerus in children. *Surg Gynecol Obstet.* 1959;109:145-54.
6. Flynn JC, Matthews JC, Benoit RJ. Blind pinning of displaced supracondylar fracture of humerus in children. Sixteens years' experience with long term follow up. *J Bone Joint Surg Am.* 1974;56:263-72.
7. Lee YH, Lee SK, Kim BS, Chung MS, Baek GH, Gong HS, et al. Three lateral divergent or parallel pin fixations for the treatment of displaced supracondylar humerus fractures in children. *J Pediatr Orthop.* 2008 Jun;28(4):417-22.
8. Skaggs DL, Hale JM, Bassett J, Kaminsky C, Kay RM, Tolo VT. Operative treatment of supracondylar fractures of the humerus in children. The consequences of pin placement. *J Bone Joint Surg Am.* 2001 May;83-A(5):735-40.
9. Guy SP, Ponnuru RR, Gella S, Tulwa N. Lateral entry fixation using three divergent pins for displaced paediatric supracondylar humeral fractures. *ISRN Orthop.* 2011;2011:137372.
10. Srikumaran U, Tan EW, Belkoff SM, Marsland D, Ain MC, Leet AI, et al. Enhanced biomechanical stiffness with large pins in the operative treatment of pediatric supracondylar humerus fractures. *J Pediatr Orthop.* 2012 Mar;32(2):201-5.
11. Larson L, Firoozbakhsh K, Passarelli R, Bosch P. Biomechanical analysis of pinning techniques for pediatric supracondylar humerus fractures. *J Pediatr Orthop.* 2006 Sep-Oct;26(5):573-8.
12. Skaggs DL, Cluck MW, John AM, Flynn M, Kay RM. Lateral entry pin fixation in the management of supracondylar fractures in children. *JBJS Am.* 2004 April;86-A:702-7.
13. Lee SS, Mahar AT, Miesen D, Newton PO. Displaced pediatric supracondylar humerus fractures: biomechanical analysis of percutaneous pinning techniques. *J Pediatr Orthop.* 2002 Jul-Aug;22(4):440-3.
14. Sankar WN, Hebel NM, Skaggs DL, Flynn JM. Loss of pin fixation in displaced supracondylar humeral fractures in children: causes and prevention. *JBJS Am.* 2007 Apr;89(4):713-7.
15. Zamzam MM, Bakarman KA. Treatment of displaced supracondylar humeral fractures among children: crossed versus lateral pinning. *Injury.* 2009 Jun;40(6):625-30.
16. Kalenderer O, Reisoglu A, Surer L, Agus H. How should one treat iatrogenic ulnar nerve injury after closed reduction and percutaneous pinning of paediatric supracondylar humeral fractures? *Injury.* 2008;39:463-6.
17. Woratanarat P, Angsanuntsukh C, Rattanasiri S, Attia J, Woratanarat T, Thakkinstian A. Meta-analysis of pinning in supracondylar fracture of the humerus in children. *J Orthop Trauma.* 2012 Jan;26(1):48-53.
18. Zenios M, Ramachandran M, Milne B, Little D, Smith N. Intraoperative stability testing of lateral-entry pin fixation of pediatric supracondylar humeral fractures. *Journal of Pediatric Orthopaedics.* 2007;27:695-702.