



ISSN: 2091-2749 (Print)
2091-2757 (Online)

Correspondence:

Dr. Kamal Koirala
Department of Surgery
KIST Medical College and Teaching
Hospital, Lalitpur, Nepal
Email: drkkoirala@gmail.com

Peer Reviewed By

Dr. Vivek Todi
Patan Academy of Health Sciences
Email: vivektodi@pahs.edu.np

Dr. Sumana Bajracharya
Patan Academy of Health Sciences
Email: sumanabajracharya@pahs.
edu.np

Perforated Jejunal Diverticulum - an Unusual Presentation

Kamal Koirala,¹ Mahesh Khakurel,¹ Reetu Barai²

¹Department of Surgery, ²Department of Pathology, KIST Medical College and Teaching Hospital, Lalitpur, Nepal

ABSTRACT

Jejunal diverticula are rare and usually asymptomatic. Acute complications may include haemorrhage, diverticulitis, obstruction, abscess formation and perforation.

Here we report a case of 61 years lady who presented with generalized abdominal pain, vomiting and fever. There were features of acute peritonitis on examination. Exploratory laparotomy revealed a perforated jejunal diverticulum. Resection of the jejunal segment containing the perforated diverticulum and primary anastomosis was done. Histopathological examination revealed jejunal diverticulum with pinhole perforation.

Keywords: acute abdomen, diverticular perforation, jejunal diverticulum, small bowel diverticular disease

INTRODUCTIONS

Jejunal diverticula are rare clinical entities.¹ The majority of cases are asymptomatic. Only a few cases present with chronic non-specific abdominal symptoms and acute complications, including haemorrhage, intestinal obstruction, diverticulitis and perforation.²⁻⁵ Because of the rarity of the disease and its complications, diagnosis is difficult and delayed.⁶ We are presenting a rare case of perforated jejunal diverticulum.

CASE REPORT

A 61 years lady with abdominal pain of three days and two episodes of vomiting presented to the emergency department of KIST Medical College, Kathmandu, Nepal. She was ill looking, dehydrated and febrile (101°F) with heart rate of 110 bpm, blood pressure of 90/50 mmHg. There was generalized abdominal tenderness, more prominent at right iliac fossa. White cell count was elevated ($16 \times 10^9/L$) with neutrophils 87%. Other laboratory tests were normal. Supine abdominal X-ray displayed multiple dilated loops of small bowel. Chest X-ray revealed free gas under diaphragm. Ultrasonography of abdomen showed dilated small bowel with minimal pelvic collection. Patient was resuscitated (intravenous fluid, antibiotic Ceftriaxone and Metronidazole, Foley catheterization) for emergency laparotomy with diagnosis of appendicular perforation.

Intra-operative findings revealed a solitary jejunal diverticulum of $5 \times 5 \text{ cm}^2$ with pinhole perforation (Figure.1) at two feet from the duodeno-jejunal flexor, swollen appendix and minimal amount of pus in the peritoneal cavity. Appendectomy, segmental resection of the jejunum and primary jejunum-jejunal anastomosis were carried out. Peritoneal lavage was done with warm normal saline and abdomen was closed with tube drains in pelvis and in vicinity of anastomosis. Histopathology revealed the jejunal diverticulum with pinhole perforation (Figure.2). She made an uneventful recovery and was discharged on the 9th post operative day.

DISCUSSIONS

Our patient was diagnosed with perforated appendix and underwent laparotomy. Only during surgery we found perforated jejunal diverticulum. The diagnosis of complicated or uncomplicated jejunal diverticulitis is seldom made before exploratory laparotomy or diagnostic laparoscopy.^{7, 8} Small bowel diverticula are rare.^{1,4,9} These diverticula are classified as acquired diverticula.¹⁰ They are formed by herniation of mucosa and submucosa through the muscular layer of the bowel

wall and are usually multiple, arising on the mesenteric border where the arteries enter the intestine, contrary to the true congenital Meckel's diverticulum. Their size varies from a few millimetres to more than 10 cm and they occur in greatest number in the oral part of the small bowel and they also tend to be larger.⁶ In our case also, the diverticulum was originating on the mesenteric border of the jejunum and was 5 cm in size with perforation at tip. The predominance of diverticula in the jejunum is attributed to the greater diameter of the penetrating jejunal arteries.¹

Acute complications like infection, haemorrhage, obstruction and perforation require prompt management.²⁻⁵ Most frequent acute complication of the jejunoileal diverticula is diverticulitis with or without perforation, occurring in 2.3 % to 6.4 % of cases.¹ Complications or symptoms requiring surgery have been reported to occur in up to 10 %.¹ Chronic symptoms include abdominal pain, nausea, vomiting, flatulence and diarrhoea or malabsorption, but these are non-specific.^{4,7} The incidence of jejunum-ileal diverticula is reported to be 0.5% to 2.3% in small-bowel contrast studies and 0.3% to 4.5% in autopsy studies.^{3,4} Owing to their mesenteric location, they may frequently be overlooked at operation and autopsy

Jejunal diverticulosis, unlike colonic diverticulosis is not associated with surrounding diverticulitis¹⁰ as we found intra-operatively (Figure 1) and was confirmed on histopathological report (Figure 2).

The elderly woman in our case with rare disease of jejunum-ileal diverticula presented with acute perforation peritonitis and was successfully managed with resection anastomosis during emergency laparotomy.



Figure 1. Cut surface of surgical specimen showing jejunal diverticulum with pinhole perforation

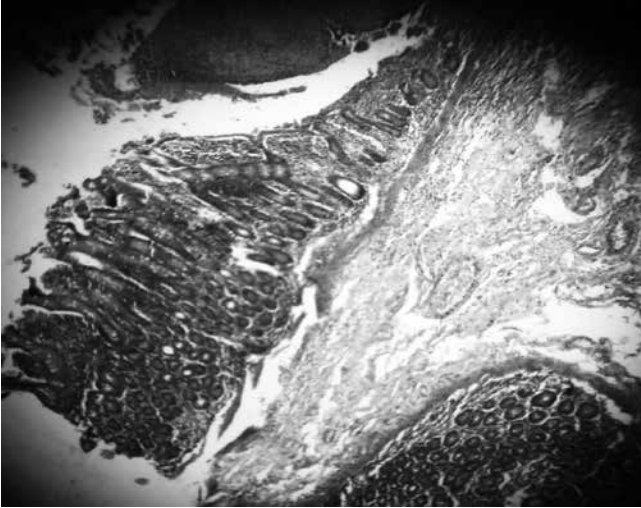


Figure 2. Histopathology of jejunal diverticulum

REFERENCES

1. Tsiotos GG, Farnell MB, Ilstrup DM. Nonmeckelian jejunal or ileal diverticulosis: an analysis of 112 cases. *Surgery*. 1994;116:726–32.
2. Wilcox RD, Shatney CH. Massive rectal bleeding from jejunal diverticula. *Surg Gynecol Obstet*. 1987;165:425–8.
3. Ross CB, Richards WO, Sharp KW, Bertram PD, Schaper PW. Diverticular disease of the jejunum and its complications. *Am Surg*. 1990;56:319–24.
4. Longo WE, Vernava AM 3rd. Clinical implications of jejunoileal diverticular disease. *Dis Colon Rectum*. 1992;35:381–8.
5. de Bree E, Grammatikakis J, Christodoulakis M, Tsiftsis D. The clinical significance of acquired jejunoileal diverticula. *Am J Gastroenterol*. 1998;93:2523–8.
6. Lempinen M, Salmela K, Kemppainen E. Jejunal diverticulosis: a potentially dangerous entity. *Scand J Gastroenterol*. 2004; 39: 905–9.
7. Chiu EJ, Shyr YM, Su CH, Wu CW, Lui WY. Diverticular disease of the small bowel. *Hepatogastroenterology*. 2000;47:181–4.
8. Cross MJ, Snyder SK. Laparoscopic-directed small bowel resection for jejunal diverticulitis with perforation. *J Laparoendosc Surg*. 1993;3:47–9.
9. Gross SA, Katz S. Small bowel diverticulosis: an overlooked entity. *Curr Treat Options Gastroenterol*. 2003;6:3–11.
10. Joseph S Butler, Christopher G Collins, Gerard P McEntee. Perforated jejunal diverticula: a case report. *Journal of Medical Case Reports*. 2010;4:172.