

Snodgrass Tubularized Incised Plate Urethroplasty for Distal and Midpenile Hypospadias

Thapa B¹, Pun M²

Abstract

Introduction: Despite hundreds of repair techniques for hypospadias, the introduction of tubularized incised plate urethroplasty (TIP) by Warren T. Snodgrass has become popular because of good functional and cosmetic outcome. The objective of this study was to share our experience of Snodgrass tubularized incised plate (TIP) urethroplasty for the repair of distal and mid-penile hypospadias. **Materials and Methods:** This prospective study was carried out for a period of 24 months. It included 46 male patients with the mean age of 4.1 years (18 months to 10 years). Proximal hypospadias and those distal with moderate to severe chordee were excluded. All cases underwent TIP urethroplasty as described by Snodgrass and the neourethra was covered by single or double layer of dorsal prepuce layer. The results were analyzed on the basis of duration of surgery, types of postoperative complications like urethrocutaneous fistula, meatal stenosis and wound dehiscence. Functional results assessed with ease of voiding, force and direction of urinary stream and cosmetic with external look of penis. **Results:** The overall complication rate requiring surgical intervention was 8 (17.3%). Mean duration of surgery was 66 minutes (60-80 minutes). Urethrocutaneous fistula occurred in 5 (10.8%), meatal stenosis in 1 (2.1%) and wound dehiscence in 2 (4.3%) patient. The cosmetic appearance was excellent in all patients involved in this study except 2 cases of wound dehiscence. All of them had vertically oriented slit like meatus with straight urinary stream. **Conclusion:** Tubularized incised plate urethroplasty gives good functional and excellent cosmetic results with low rate of complications in distal and mid-penile hypospadias.

Key Words: Hypospadias, Tubularized incised plate urethroplasty, Snodgrass.

Introduction

Hypospadias is one of the most common congenital anomaly of external genitalia in males occurring in approximately 1 in 200~300 live birth. The abnormal urethral opening can be anywhere along the ventral side of penile shaft and down to the perineum. In over 80% of cases, the meatus is located distal to the midshaft^{1,2}.

¹Dr. Bijay Thapa, MBBS, MS, Consultant Paediatric Surgeon, ²Dr. Madhusudan Pun, MBBS, MS, Head of Department and Consultant Paediatric Surgeon. Both from the department of Paediatric Surgery, Kanti Children's Hospital, Maharajgunj, Kathmandu, Nepal.

Address for correspondence

Dr. Bijay Thapa
Consultant Paediatric Surgeon
Kanti Children's Hospital
Kathmandu, Nepal.
Tel: 977-9851029644
E-mail: bijaytapa@hotmail.com

How to cite

Thapa B, Pun M. Snodgrass Tubularized Incised Plate Urethroplasty for Distal and Midpenile Hypospadias. J Nepal Paediatr Soc 2014;34(1):29-33.

doi: <http://dx.doi.org/10.3126/jnps.v34i1.8692>

This work is licensed under a Creative Commons Attribution 3.0 License.



There are over 200 procedures described in literature about hypospadias surgery. The ultimate goal of hypospadias repair is to achieve a functional penis with normal looking cosmetically^{3,4}. Tubularized Incised plate (TIP) urethroplasty by Snodgrass in 1994 has gained popularity and revolutionized the management of different types of hypospadias including proximal hypospadias and in re-operative cases. TIP procedure is technically easy giving a normal looking vertical slit like meatus with low complications like urethrocutaneous

fistula, meatal stenosis^{5,6,7}. The purpose of our study was to share our experience with TIP urethroplasty in the management of distal hypospadias.

Materials and Methods

A total of 46 male children 18 months to 10 years age with penile hypospadias were included in this study from January 2011 to January 2013 in Kanti Children’s Hospital and BP Smriti Hospital. Only distal and mid penile hypospadias with good and wide urethral plate were included. All children underwent tubularized incised plate urethroplasty described by Snodgrass. Hypospadias with moderate to severe chordee were excluded.

Table 1: Types of hypospadias in children (n=46) who underwent Snodgrass Tubularized Incised Plate urethroplasty

Types	No of patients (n)
Coronal	6 (13.04%)
Sub coronal	17 (36.95%)
Distal shaft	15 (32.60%)
Mid shaft	8 (17.39%)
Total	46 (100%)

Table 2: Age distribution of patients (n=46) with hypospadias who underwent Snodgrass Tubularized Incised Plate urethroplasty

Range	No. of patients
0-2 years	10 (21.73%)
2-4 years	20 (43.47%)
4-6 years	8 (17.39%)
6-8 years	5 (10.86%)
8- 10 years	3 (6.52%)
Total	46 (100%)

All the patients did all basic investigations like total blood count, urea, creatinine, urine routine and culture and examined for any other associated anomalies of genito-urinary system by abdominal ultrasound. The operation was performed under general anesthesia along with caudal block. A stay suture was placed in glans to aid in the traction of the phallus. Eight to 10 French Foleys catheter were placed on the basis of patient age and size of phallus. Rubber tourniquet applied at the base of penis and released at 40 minutes interval. A U-shaped incision was made, extending along the edges of the urethral plate approximately 8-10 mm up to the glans and to the healthy skin 2 mm

proximal to the meatus. The plate was freed on both side. Then an incision was added in midline of urethral plate from native meatus up to the glans. The urethral plate was tubularized over the catheter using 6-0 absorbable suture centisorb (poly glycolide-co-lactide) with running sub epithelial stitches. Neourtehra was then covered with one or two vascularised subcutaneous (dartos) flap those harvested from the dorsal prepuce. Glanuloplasty was done by closure of glandular wings and the tip with neourethral plate. The granular wings, mucosal collar and ventral shaft skin were closed in the midline. A light compressive dressing was applied.

Intravenous third generation cephalosporin with 100 mg/kg/day in three divided doses were given for five days and changed to oral. Pain managed with intramuscular pethidine 1mg/kg/dose initially in addition with oral paracetamol (flexon). All cases had dressing opened on 3rd or 4th postoperative day. Neosporin ointment was applied after the dressing was opened regularly. Foleys catheter was taken out on 8th to 10th postoperative days seeing the conditions of healing and patients discharged. Patients were informed for follow ups after two weeks of discharge to see the wound status and see the urinary stream and any other complication.

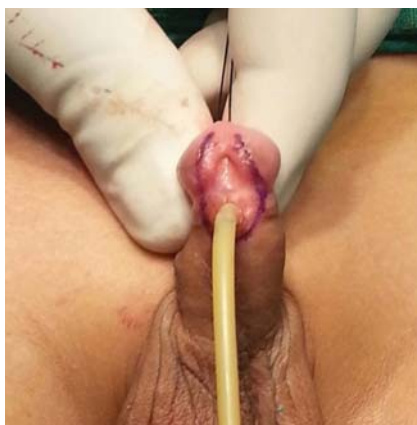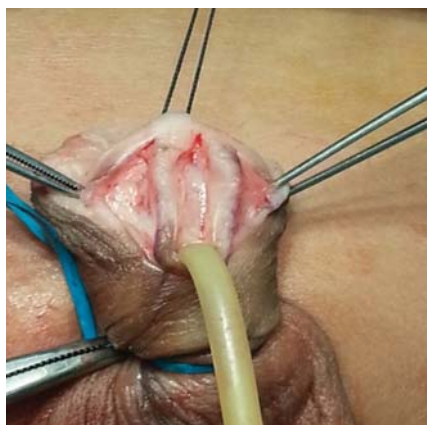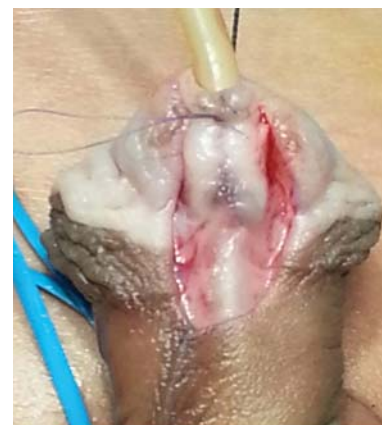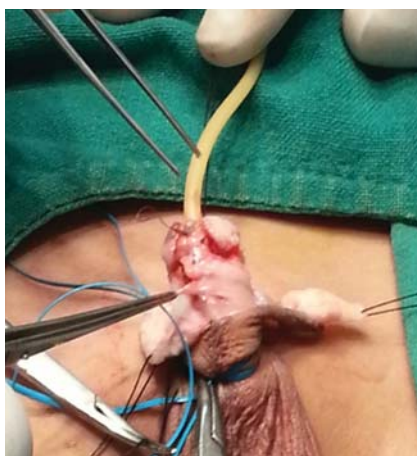
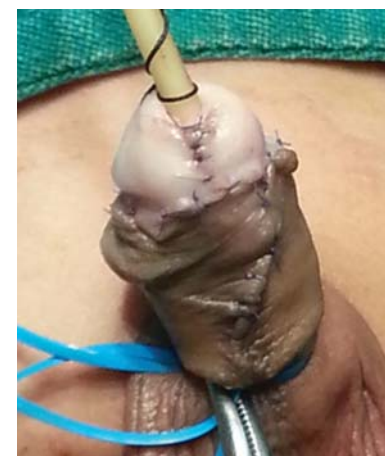Each patient was assessed on the 8th-10th post-operative day after removal of the catheter and during their first follow-up on two weeks after discharge. Assessment was done on the basis complications like urethrocutaneous fistula, meatal stenosis, cosmetic look of penis and glans and urinary stream.

Results

Overall complications occurred in eight patients with the complication rate of 17.3%. Five (10.86%) cases had urethrocutaneous fistula. Out of 5 fistula cases, four urethrocutaneous fistula was seen after the catheter was removed and the remaining one had fistula after two weeks of discharge. Meatal stenosis occurred in one case. In one coronal and subcoronal hypospadias complete wound with glandular dehiscence was seen. Surgery time duration ranged from 60 minutes to 80 minutes with an average 66 minutes. Forty four (95%) cases had a normally situated vertical slit like meatus and voided with a straight urinary stream except with two cases with wound dehiscence. Meatus was almost at the tip of the glans penis with excellent cosmetic looking.

Table 3: Postoperative results after Snodgrass Tubularized Incised Plate urethroplasty (n=46)

Types of hypospadias	No. of pts	Urethrocutaneous Fistula	Meatal stenosis	Wound dehiscence	Good cosmetic appearance
Coronal	6	0	0	1	5
Sub coronal	17	1	0	1	16
Distal shaft	15	2	0	0	15
Mid shaft	8	2	1	0	7
Total	46 (100%)	5 (10.86%)	1 (2.1%)	2 (4.3%)	43 (93.4%)

**Fig 1:** U shape incision over urethral plate**Fig 2:** Midline and parallel plate incision**Fig 3:** Neourethra (tubularization)**Fig 4:** Neourethra coverage by dartos**Fig 5:** Final repair**Fig 6:** Straight urinary stream

Discussion

The technique of tubularized incised plate urethroplasty for distal hypospadias described here has several advantages over other procedures. Meatal advancement and glanuloplasty (MAGPY) was developed to correct a meatus which has urinary stream going downward as its demerits. Mathew, onlay and island pedicle flap procedure has also been widely used with minimal complications but the meatus appearing rounded like fish mouth in contrast to slit like of a normal meatus was their disadvantage. Thiersch-duplay procedure leads to

glanular meatus and is a two stage surgery as its drawback^{3,4}. All drawbacks of these procedures are completely omitted by TIP urethroplasty. The rate of complications like urethrocutaneous fistula, meatal stenosis, ease of surgery and duration is also in favor of TIP urethroplasty.

Rich et al introduced the principle of incising the urethral plate in the midline to improve the cosmetics of a hypospadias repair in 1989⁸. The goal of hypospadias surgery is a penis that is functionally and cosmetically normal. This is achieved by constructing a straight penis with meatus as close as possible to normal site

with proper shape to allow a forward directed stream and normal coitus^{9,10}.

In 1994 Snodgrass used this concept and extended the incision of the urethral plate from the meatus to the TIP of the glans. It has gained popularity so that most surgeons today prefer doing TIP rather than other procedure for distal hypospadias. TIP has better outcome, less complications and good cosmetic looks. The main advantage of TIP is it is technically easy, gives a normal looking vertical slit like meatus which is not achieved in other procedure^{10,11,12,13,14}. Forty three (93.4%) patients in our series had good looking glans and meatus with straight urinary stream. The other main advantage of TIP is a single stage surgery which helps to reduce multiple exposure of anesthesia to the patient. TIP surgery in terms of surgery duration is also shorter with the time range of 60-80 minutes in this series.

Although several modifications and refinements have been made urethrocutaneous fistula still remains the main postoperative complications^{15,16}. Our fistula rate was 5 (10.86%). Various study shows frequency of fistula formation after TIP urethroplasty ranges 0.5% to 16%. Zhou et al had 12.5% and Ahmad K noted 11.8% fistula rate^{17,18}. The rate of fistula formation is markedly less in TIP urethroplasty than other procedure. Anwar et al did a comparative study between TIP and Mathieu and found overall results in terms of fistula and cosmesis, TIP is better for distal hypospadias. Similar report by Muhammad et al in their comparative study between TIP and Mathieu recommended TIP as their primary treatment for distal hypospadias^{19,20}.

This marked decrease in fistula formation is due to the coverage of neourethra by the subcutaneous vascularised layer of dartos taken from dorsal prepuce and shaft skin. It was mentioned in 2003 by Sozibir and Snodgrass. In our cases we also had used single or double layer in between neourethra and skin coverage. Cheng et al have also suggested a two layer closure of the neourethra to minimize the fistula rate^{21,22}.

Some western study shows fistula formation rate less than 2%. It may be due to the development of subspecialty like paediatric urology, paediatric plastic surgery and dedications of surgeons to special field of hypospadias. Our result is also excellent and acceptable in our context where we paediatric surgeon have to deal all sorts of general paediatric and urosurgery cases.

The longitudinal incision on the urethral plate in Snodgrass urethroplasty is an innovation of urethral

plate preservation as the plate is not the cause of chordee. This midline incision in urethral plate helps to make a tension free tabularization to form a neourethra of an adequate size. Baskin et al in their histological study of urethral plate found sub mucosal layer of plate is highly vascularized with good nerve supply. This makes the healing of this incision by re-epithelialization with normal tissue but not by scar formation. This property leads to less chance of urethral stricture resulting good urinary stream^{2,5,8}. In our series we had only one case of meatal stenosis which was managed by meatotomy.

Tubularized incised plate urethroplasty (TIP) can also be used in redo cases as well as proximal and more severe form of hypospadias. A.M. Kamal et al in their series of tip urethroplasty in redo cases showed an excellent cosmetic and functional result²³. Chen et al performed TIP in 40 cases of proximal hypospadias and overall complication rate was 17.5%²⁴. Warren Snodgrass and Selcuk Yucel perform TIP in 65% of all proximal hypospadias with an overall complication rate of 37%. Fistula occurred in 7 out of 35 patients (20%)²⁵. At our initial stage for proximal and severe form of hypospadias we did stage surgeries with orthoplasty (straightening of penis) as first stage and urethroplasty as second stage. Now we have started doing TIP urethroplasty as single stage surgeries for proximal hypospadias.

Conclusion

Tubularized incised plate urethroplasty is a simple, single stage surgery for distal hypospadias. It gives good functional neourethra of normal looking glans and meatus with a low rate of complications like urethrocutaneous fistula, stricture. It is our preferred method of repairing distal and midpenile hypospadias in our institution.

Acknowledgements: Nil

Funding: Nil

Conflict of Interest: Nil

Permission from IRB: Yes

References

1. Daulat Khan. Management of hypospadias in children. *J Surg Pak (International)* 2008;3(2):82-84.
2. Laurence S. Baskin, Michele B. Ebberts . Hypospadias: anatomy, etiology and technique. *J Pediatr Surg* 2006;41:463-72.

3. Hastie K.J et al. Long term follow up of the MAGPI operations for distal hypospadias. *Brit J Urol* 1989;63(3):320-2.
4. Steckler R.E. and Zaontz M.R. Stent free Thiersch-Duplay hypospadias repair with the Snodgrass modifications. *J Urol* 1997;158:1178-80.
5. Snodgrass W. Tubularized incised plate urethroplasty for distal hypospadias. *J Urol* 1994;151:464-65.
6. Warent T. Snodgrass. Tubularized incised plate hypospadias repair: indications, technique and complications. *Urology* 1999;54:6-11.
7. Selami Sozubir and warren Snodgrass. A new algorithm for primary hypospadias repair based on tip urethroplasty. *J Pediatr Surg* 2003;38(8):1157-61.
8. Rich MA, Keating MA, Synder HM. Hinging the urethral plate in hypospadias meatoplasty. *J Urol* 1989;142:1551-3.
9. Al-Saied G, Gamal A. Versatility of tubularized incised plate urethroplasty in the management of different types of hypospadias: 5-year experience. *Afr J Paediatr Surg* 2009;6(2):88-92.
10. Ruziicka Milicevic, Milan Bojanovic et al. Our experience with tubularized incised plate urethroplasty for distal and mid-penile hypospadias. *Ada Media Medianae* 2003; 42:35-37.
11. Hombalkar N.N., Gaurav P.D., Parmar R.R. Snodgrass procedure-Versatile technique for various types of hypospadias repair. *JKIMSU* 2013;2(2):116-22.
12. Mohammed H. Aldabbagh. Evaluation of Snodgrass technique in the management of hypospadias in Heevi hospital. *Duhok Med J* 2011;5(1):41-46.
13. Firas S Attar. Evaluation of the tubularized incised plate urethroplasty (TIP) for repair of distal hypospadias. *Bas J Surg* 2009;15:81-85.
14. S. M. Barrack, S.H. Hamdun et al. Tubularized incised plate urethroplasty for distal hypospadias. *East African Med J* 2001;78(6):327-29.
15. SK Sinha Roy ,K Saha, PK Bhattacharjee, TK Majhi. Short term results of Snodgrass tubularized incised plate urethroplasty in distal and mid penile hypospadias. *J Indian Assoc Pediatr Surg* 2003;8:226-30.
16. Muhammad Ujair, Munir Ahmad, Mussarat Hussain et al. Frequency of urethrocutaneous fistula following Snodgrass hypospadias repair in children. *JPMI* 2013;27(1):74-77.
17. Zhou Y, Lu J, Takahashi G. Snodgrass procedure for primary hypospadias repair: *Int J Urol* 2002; 9:215-8.
18. Ahmed K. Snodgrass repair for distal hypospadias: a review of 75 cases. *Ann Pediatr Surg* 2012;8:12-4.
19. Anwar-ul-Haq, Nadeem Akhter et al. Comparative study of Mathieu and Snodgrass repair for anterior hypospadias. *J Ayub Med Coll Abbottabad* 2006;18(2):50-52.
20. Muhammad Shahzad, Saleem et al. Comparative study between tubularized incised plate (Snodgrass) urethroplasty and reverse flap (Mathieu's) repair in distal hypospadias. *Ann Pak Inst Med Sci* 2012;8(2):96-100.
21. Ahmed M.Aboul, Sherine M. Aboul et al. Modified tabularized incised plate (TIP) hypospadias repair using dartos fascia flap. *Egypt J Plast Reconstr Surg* 2006;30(2):139-42.
22. Cheng EY, Vemulapalli SN, Kropp BP, Pope JC, Furness PD et al. Snodgrass hypospadias repair with vascularised dartos flap: the perfect repair for virgin case of hypospadias. *J Urol* 2002;168:1723-6.
23. A.M. Kamal, S.E. Abou Hashem et al. Tubularized incised plate (TIP) urethroplasty: Extended use in hypospadias re-operation. *African J Urol* 2005;11(1): 15-21.
24. Chen SC, Yang SS, Hsieh CH, et al. Tubularized incised plate for mid shaft and proximal hypospadias repair. *J Urol* 2007;17:698-702.
25. Warren Snodgrass and Selcuk Yucel: Tubularized incised plate urethroplasty for proximal hypospadias. *Brit J Urol Int* 2002;89-90.