

Meckel's Diverticulum with Multiple Ileal Ulcers as a Source of Massive Gastrointestinal Haemorrhage in a Three Year Old Child

Hamid R¹, Wani SA², Shera AH³, Khurshid S⁴, Bhat NA⁵, Baba AA⁶

¹Dr. Raashid Hamid, MBBS, MS, Senior Resident, ²Dr. Sajad A Wani MBBS, MS. Senior Resident, ³Dr. A H Shera, MBBS, MS, Mch Professor, ⁴Dr. Sheikh Khurshid, MBBS, MS. Professor, ⁵Dr. NA Bhat, MBBS. MS. Mch Asst. Prof. ⁶Dr. Aejaz A Baba, MBBS, MS, Mch Asst. Prof. All from the Department of Paediatric Surgery, SKIMS, Srinagar, India.

Introduction

Johann Friedrich Meckel in 1809 first described MD. Meckel's diverticulum is a common anomaly of small intestines that results due to failure of the omphalomesenteric duct to obliterate. Incidence of MD ranges from 1.2 to 1.7%, with a male female ratio of 3:2^{1,2}.

The complications of MD include inflammation, perforation, haemorrhage, intussusception, volvulus, intestinal obstruction and malignant transformation³. Majority of the symptomatic diverticulum present during paediatric age group. Life time complication rate has been reported to be around 4%⁴. Computed Tomography and Ultrasonography (USG) are usually of little value. ^{99m}Tc-pertechnetate gives an accurate diagnosis when uptake occurs in ectopic gastric mucosa⁵. Diagnosis is confirmed by diagnostic laparotomy. We present a 3 year old male child with massive episodic gastrointestinal bleed who was subjected to ^{99m}Tc-pertechnetate scan, the study was positive and subsequently patient was explored, which confirmed the diagnosis of a bleeding Meckel's diverticulum.

The Case

A 3-year old male toddler was referred from medical paediatric department to our surgical department with 6 days history of episodic lower gastrointestinal bleeding having hemoglobin of 3gm/dl. History narrated by the parents revealed that their baby had 3 to 5 episodes of

Abstract

Meckel's Diverticulum (MD) is a frequent congenital anomaly of small bowel often difficult to diagnose. It is usually asymptomatic and can present as bleeding, obstruction and inflammation. We report a case of MD in a 3 year old male child, diagnosed by ^{99m}Tc pertechnetate scan and confirmed on laparotomy. Excised specimen revealed a large MD with multiple ileal ulcers, as a source of massive bleeding per rectum. The clinical features and need for early diagnosis and treatment are discussed.

Key words: Meckel's diverticulum, Bleeding per rectum, Multiple ileal ulcers.

bleeding per rectum per day, dark black in color. Each episode was around 30 to 40 gm in quantity. Bleeding was associated with crampy abdominal pain. There was no history of vomiting, fever, or dysuria. During these six days USG, colonoscopy and dye study of intestines were normal.

The patient's Hb was 3 g/dl, a total leucocyte count of 13000 with a predominance of granulocytes (74%) and a normal platelet count. The coagulation studies revealed PTI of 95% INR;1.4 and Aptt;16 sec, chest and abdominal radiographs were unremarkable. USG abdomen and colonoscopy were also normal. After admission, patient was referred to our Paediatric Surgery Department we subjected the baby to thorough physical examination. Positive findings included gross Pallor, mild diffuse abdominal tenderness. Digital rectal examination confirmed the stool color which was dark black as was described by the parents. There was no other local lesion in peri-anal area or rectum. ^{99m}Tc-pertechnetate scan done, which showed radionuclide activity in right iliac fossa. [Figure 1]

How to cite this article ?

Hamid R, Wani Sajad, Shera AH, Sheikh Khurshid, Bhat NA, Baba AA. Meckel's Diverticulum with Multiple Ileal Ulcers as a Source of Massive Gastrointestinal Haemorrhage in a Three Year Old Child. J Nepal Paediatr Soc 2013;33(3):227-229.

Address for correspondence

Dr. Raashid Hamid

E-mail: drraashidhamid@gmail.com

This work is licensed under a Creative Commons Attribution 3.0 License.



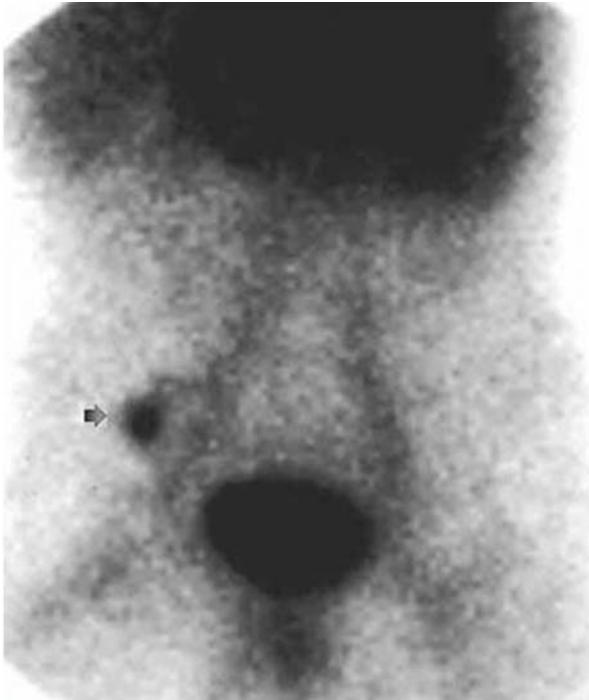


Fig 1: ^{99m}Tc-pertechnetate scan with radionuclide activity in right iliac fossa.

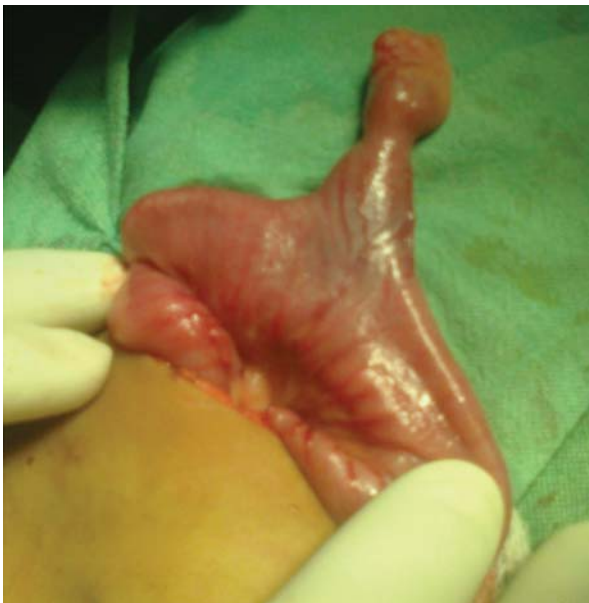

Fig 2: Intraoperative photograph of Meckel's Diverticulum

Baby was explored in emergency operation theatre. A 3.5cm long Meckel's diverticulum was found just 32 cm from ileocecal valve. The diverticulum was broad based. Resection of the ileum was done 5cm proximal and 4cm distal to the diverticulum (Figure 2). The specimen was opened along the antimesenteric boarder which revealed multiple ileal ulcers (Figure 3). Anastomosis was done between the two ends of ileum. Baby did well postoperatively. Histopathology revealed ectopic gastric mucosa in the diverticulum and multiple peptic ulcers in the resected specimen.

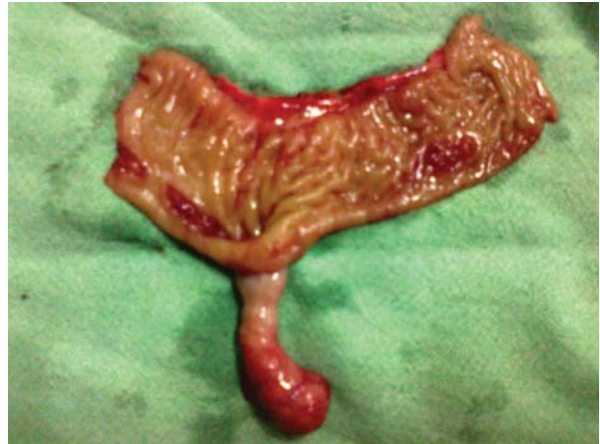

Fig 3: Ileal lumen containing Multiple ileal ulcers.

Discussion

Clinical symptoms arise from complications MD carriers have a 4% life time risk of developing a complication^{1,6}. Haemorrhage results due to ileal mucosal ulceration next to an acid-producing gastric mucosal tissue. Clinical presentation varies from recurrent minimal intestinal bleeding to a massive shock-producing hemorrhage which is usually painless. Other clinical manifestations include perforation, intussusception, diverticulitis, Littre's hernia. Tumors are reported in 0.5-3% symptomatic diverticula in adulthood⁷.

Preoperative diagnosis can be challenging and often difficult to establish. Complicated MD has a spectrum of radiological features but are not always diagnostic. In diagnosing the bleed from Meckel's diverticulum, the upper and lower gastrointestinal endoscopy play no role as they are not able to visualize the ileal lumen. It is very difficult to distinguish an ileal loop from Meckel's diverticulum on ultrasonography and CT. As mentioned our case USG, Upper GI and lower GI endoscopy were normal and these could not help in arriving at diagnosis. Radionuclide ^{99m}Tc-pertechnetate isotope scan may diagnose MD when uptake occurs in ectopic gastric mucosa or by identifying the site of gastrointestinal bleeding. Accuracy reported is around 90% in paediatric patients⁸ and drops to only 46% in adult group⁹. In our case, the ^{99m}Tc-pertechnetate scan was positive after delayed imaging showing radioactivity in right iliac fossa. The correct diagnosis is finally confirmed on laparotomy as in our case. The laparotomy affords the possibility of simultaneous surgical resection which is definitive cure of symptomatic MD. Length and width of the diverticulum are also felt to be determinant in symptomology. Mackey et al found that symptomatic diverticula were more likely to be 2cm or greater in length². Broad based diverticula were less likely to be symptomatic because of lower risk of obstruction. As demonstrated in our case, the length of the Meckel's

diverticulum was 3.5cm and was symptomatic. Hence inferring that long diverticulum may have more chances of bleeding. There is general agreement that symptomatic MD should be resected by either open or laparoscopic procedures.

As our patient presented with bleeding and Meckel's scan was positive after all other investigations were negative. The MD in our case had lead to multiple peptic ulceration of the ileum as shown in the specimen photograph. The probable cause of the massive GI bleed in our case was multiple ileal ulcers which is very rare. The cause of multiple ulcers could be due the delay in diagnosis.

There should not be any delay in having a suspicion of MD as a cause of GI bleed and the patient should undergo a ^{99m}Tc -pertechnetate scan and subsequent laparotomy. These patients should be referred immediately to centres having ^{99m}Tc -pertechnetate scan facility and trained paediatric surgeon which can alter the course of the disease that can sometimes be fatal.

Conclusion

Proper history, clinical examination and early diagnosis and treatment can be life saving. Exploratory laparotomy decreases the time spent for diagnosis and theoretically avoids the morbidity and mortality of delayed diagnosis.

References

1. Daniela Codrich, Andrea Taddio, Jurgen Schleef, Alessandro Ventura, and Federico Marchetti. Meckel's diverticulum masked by a long period of intermittent recurrent subocclusive episodes. *World J Gastroenterol* 2009;15:2809–11.
2. Mackey WC, Dineen P. A fifty-year experience with Meckel's diverticulum. *Surg Gynecol Obstet* 1983;156:54–6.
3. Anderson DJ. Carcinoid tumor in Meckel's diverticulum: laparoscopic treatment and review of the literature. *J Am Osteopath Assoc* 2000;100:432–34
4. Soltero MJ, Bill AH. The natural history of Meckel's diverticulum and its relation to incidental removal. A study of 202 cases of diseased Meckel's diverticulum found in King County Washington, over a fifteen year period. *Am J Surg* 1976;132:168–73.
5. Yinlu Ding, Yong Zhou, Zhipeng Ji, Jianliang Zhang, and Qisan Wang Laparoscopic Management of Perforated Meckel's Diverticulum in Adults. *Int J Med Sci* 2012;9(3):243–47.
6. Martin JP, Connor PD, Charles K. Meckel's diverticulum. *Am Fam Physician* 2000;61:1037–1042, 1044
7. Yamaguchi M, Takeuchi S, Awazu S. Meckel's diverticulum investigation of 600 patients in the Japanese literature. *Am J Surg* 1978;136:247–49
8. Cooney DR, Duszynski DO, Camboa E. et al. The abdominal technetium scan (a decade of experience) *J Pediatr Surg* 1982;17:611–19
9. Schwartz MJ, Lewis JH. Meckel's diverticulum: pitfalls in scintigraphic detection in the adult. *Am J Gastroenterol* 1984;79:611-18.