

Caffey Disease: A Diagnostic Dilemma

Shanti Regmi¹, Sudhir Adhikari¹, Deekshanta Sitaula¹, Ananda Prasad Regmi², Gaurav Neupane², Biraj Parajuli¹ and Sumita Poudel¹

¹Department of Paediatrics, Chitwan Medical College, Bharatpur, Chitwan, Nepal

²Department of Orthopaedics, Chitwan Medical College, Bharatpur, Chitwan, Nepal

Correspondence:

Sudhir Adhikari
Department of Paediatrics,
Chitwan Medical College,
Bharatpur, Chitwan.
Email: sudhiradhikari99@gmail.com

DOI: 10.3126/jnps.v41i2.34893

Submitted on: 2020-06-15

Accepted on: 2020-10-04

Acknowledgements: None

Funding: Nil

Conflict of Interest: None declared

Permission from IRB: Yes

To cite this article: Regmi S, Adhikari S, Sitaula D, Regmi AP, Neupane G, Parajuli B, et al. Caffey Disease: A Diagnostic Dilemma. J Nepal Paediatr Soc. 2021;41(2): 274-7.

ABSTRACT

Caffey disease is a rare, self limiting condition which usually presents in early infancy. The clinical features include fever, irritability, inflammatory swelling of soft tissue due to acute inflammation of the periosteum and subperiosteal new bone formation. Possible differential diagnoses are osteomyelitis, hypervitaminosis A, scurvy, bone tumours, prolonged use of Prostaglandin E₁ (PGE₁) and child abuse. Although self-limiting, it can cause diagnostic dilemma leading to delayed diagnosis and unnecessary investigations. Here, we report a case of two month old male infant presenting with painful left scapular mass.

Keywords: Caffey Disease; Infantile Cortical Hyperostosis; Osteomyelitis



This work is licensed under creative common attribution 3.0 license



INTRODUCTION

Caffey disease or infantile cortical hyperostosis (ICH) is a rare, self-limiting disease characterised by acute inflammation of soft tissues and cortical thickening of underlying bone which usually presents in infants. Clinically, it is characterised by sudden onset of irritability, fever, decreased joint mobility and soft tissue swelling.¹ Even though it has a good prognosis, there will be a diagnostic dilemma as it mimics a wide range of diseases like osteomyelitis, hypervitaminosis, bone tumours, scurvy and child abuse.² The aim here is to emphasise the possibility of Caffey disease while dealing with the case of infantile bony swellings.

CASE REPORT

A two month old male infant presented to Emergency Department of Chitwan Medical College, Chitwan, Nepal on 2020 May with complains of a left shoulder mass with paucity of left arm movement for previous two weeks and fever for four days. There were no accompanying respiratory, gastrointestinal or urinary symptoms. He was born normally at term weighing 3.4 kg at birth. Antenatal period was uneventful and he had received vaccination as per his age. There was no history of Prostaglandin E₁ infusion for ductal patency during neonatal period. There was no family history of similar disease and no history of trauma, intramuscular injections or seizures.

On examination, the infant was febrile and irritable. Vitals were stable except temperature measuring 102 degree Fahrenheit. Anthropometric measurements were normal for his age. There was no pallor, icterus, enlarged lymph nodes or hepatosplenomegaly. A tender mass was noted on

left shoulder over the body of left scapula with soft tissue swelling (Figure 1) and restricted left shoulder movement. Investigations findings are shown in Table 1. USG reported ill-defined heterogeneous changes noted in subcutaneous and myofascial layer over posterior aspect of left shoulder with collection in intramuscular plane. A clinical possibility of cellulitis of scapular region was made and the patient was admitted to Paediatrics Ward. IV antibiotics and antipyretics were started. X-Ray of left shoulder was done which revealed diffuse thickening of left scapula with thickened cortex (Figure 2). On completion of antibiotics, the fever subsided, child was alert and playful but the left scapular mass didn't regress. However, the child was discharged on patient party's persistent request with oral antibiotics.

On follow-up after seven days, the swelling was consistent, with painful restricted left shoulder movement. Orthopaedic consultation was taken where clinical possibility of osteomyelitis was considered and MRI was advised which reported diffuse smooth extensive periosteal reaction involving left scapula with enlarged rotator cuff muscles. Similar but milder changes were also noted in left mandibular body and ramus, right mandibular ramus, medial ends of clavicles, left 8th and right 7th ribs in MRI. On the basis of the age of the patient (< 6 months), clinical course, laboratory findings and radiology, the infant was diagnosed with Caffey disease. Subsequently, he was treated with analgesics with observation on follow-up basis. Swelling and restriction of movement of left

Table 1. Laboratory finding of infant with Caffey disease

Investigation	Findings	Normal Range
Hemoglobin	8.4 g/dl	10.5 - 14 g/dl
Total WBC count	15740 /mm ³	6000 - 14000/mm ³
Platelet count	762000 /mm ³	150000 - 400000/mm ³
CRP	178.61 mg/dl	0.08 - 1.58 mg/dl
ESR	105 mm/hr	0 - 10 mm/hr

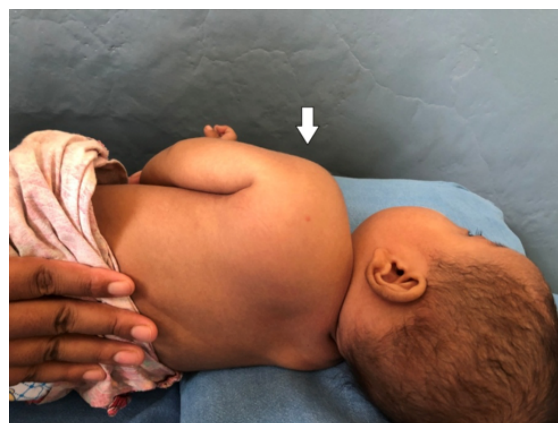

Figure 1. Two months - old male infant with swelling of left shoulder

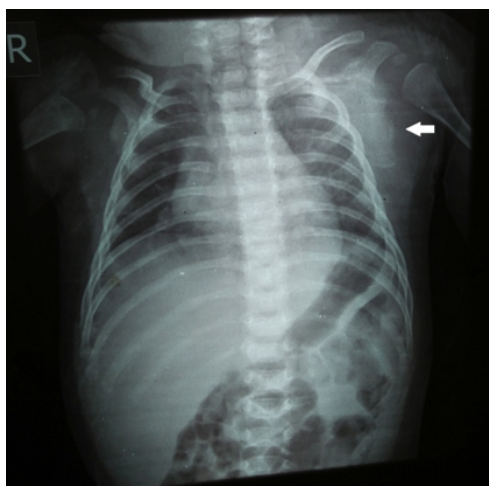


Figure 2. X-ray showing diffuse thickening of left scapula with thickened cortex

shoulder improved over a period of two months. On next follow-up, he was doing well.

DISCUSSION

Caffey Disease was described initially in 1945 by Caffey and Silverman.³ It is a rare, self-limiting disorder which is characterised by an acute inflammation of the periosteum and the covering soft tissues.^{1,4} The characteristic triad of Caffey disease consists of systemic symptoms (irritability and fever), soft tissue swelling and underlying cortical bone thickening.² The exact aetiology of this disorder is still unclear however it has been reported that the autosomal dominant form of Caffey disease is caused by recurrent arginine-cysteine (R836C) substitution in the α_1 chain of type I collagen.⁴

Caffey disease is a disorder of early infancy with its onset within first six months of life which usually resolves by two years of age.¹ The most frequently involved site is mandible (70-90%) followed by clavicle, ribs, scapula and long bones.⁴ Laboratory findings include elevated Erythrocyte Sedimentation Rate (ESR), high level of C-

Reactive proteins (CRP), high alkaline phosphatase, thrombocytosis, anaemia and raised immunoglobulin levels.⁵ As there is no specific laboratory test for its diagnosis, radiography is the most valuable tool.¹ Radiography reveals layers of periosteal new bone formation with cortical thickening beneath the regions of soft tissue swelling.⁶ However, there is a significant possibility of its diagnosis being delayed as it mimics various other conditions like osteomyelitis, hypervitaminosis A, bone tumour, scurvy, child abuse and prolonged PGE₁ infusion.⁶ As this patient was active and thriving and the course of the disease was prolonged without any response to antibiotics, osteomyelitis was ruled out. Also, there were no radiographic findings supporting osteomyelitis. Malignancy and scurvy were also ruled out on the basis of radiographical findings and haematological tests. There was no history and clinical findings suggestive of child abuse so it was also excluded.

Caffey disease is highly self limiting however indomethacin or naproxen can be used for symptomatic cases. If there is poor response to indomethacin, then steroids can be given. Although the prognosis is good, in some cases, recurrence or relapse of cortical hyperostosis during adolescence has also been reported.⁷

CONCLUSIONS

Caffey disease should always be kept in mind while dealing with infantile bony swellings. The aim of this case report is to draw the attention of health care providers about the existence of this rare disease and its clinic-radiological profile in order to avoid unnecessary investigations and treatment in a resource-constrained countries like Nepal.

REFERENCES

1. Siddiqui SA, Siddiqui GF, Maurya M, Shrivastava A, Singh MV. Caffey Disease in Infancy: A diagnostic dilemma for primary care physicians. Sultan Qaboos Univ Med J. 2020;20(1):e109-e11. DOI:10.18295/squmj.2020.20.01.017
2. Kutty N, Thomas D, George L, John TB. Caffey disease or infantile cortical hyperostosis: a case report. Oman Med J. 2010;25(2):134-6. DOI:10.5001/omj.2010.36

3. Caffey J, Silverman W. Infantile Cortical Hyperostosis: Preliminary Report On a New Syndrome. *Am Journal Roentgenol Rad Therapy.* 1945(54):1-16.
4. Nistala H, Mäkitie O, Jüppner H. Caffey disease: new perspectives on old questions. *Bone.* 2014;60:246-51. DOI: 10.1016/j.bone.2013.12.030
5. Kumar TS, Scott JX, Mathew LG. Caffey disease with raised immunoglobulin levels and thrombocytosis. *Indian J Pediatr.* 2008;75(2):181-2. DOI:10.1007/s12098-008-0027-4
6. Ramesh V, Sankar J. Infantile Cortical Hyperostosis of Scapula Presenting as Pseudoparalysis in an Infant. *Indian Pediatr.* 2017;54(2):157-8. DOI: 10.1007/s13312-017-1023-4
7. Navarre P, Pehlivanov I, Morin B. Recurrence of infantile cortical hyperostosis: a case report and review of the literature. *J Pediatr Orthop.* 2013;33(2):10-7. DOI: 10.1097/BPO.0b013e318277d3a2