

Case report

# Vallecular cyst in an infant with stridor: a case report

Nabin Lageju<sup>1\*</sup>, Rajendra Prasad Sharma Guragain<sup>2</sup>

Institute of Medicine (IOM), Kathmandu, Nepal

<sup>1</sup> Consultant, Department of ENT-HNS, Nepal Police Hospital, Nepal

<sup>2</sup> Professor, Department of ENT-HNS, Institute of Medicine, Kathmandu, Nepal

## ABSTRACT

**Background and Objectives:** Vallecular cysts are rare and generally asymptomatic. In infants and children they present with stridor, feeding difficulties, failure to thrive. Treatment is surgical excision with cautery or laser.

**Presentation of Case:** We discuss the clinical, radiological presentation of a 7 months old child with vallecular cyst which was surgically treated with deroofting and marsupialisation with electrocautery. There was no recurrence even up 2 years of follow-up.

**Discussion:** Flexible nasopharyngolaryngoscopic examination was done which showed present of swelling in the left vallecula pushing the epiglottis posteriorly and to the right with narrowed normal endolarynx. Radiological investigations with CT scan showed cystic lesion noted in left side of neck with no septation and solid component. The lesion was extending to ipsilateral vallecula and paraglottic region with narrowing of endolarynx.

**Conclusion:** Vallecular cyst is rare cause of noisy breathing in infants and children. In adults it is usually asymptomatic. Treatment of choice is marsupialization with electrocautery or laser.

**Key words:** electrocautery, marsupialisation, vallecular cyst

## INTRODUCTION

Laryngeal cysts are rare[1]. The first laryngeal cyst published by Abercrombie J in 1881[2]. Vallecular cysts a type of laryngeal cysts have been reported in literature under other names such as mucous retention cyst, pre-epiglottic cyst, epiglottic cyst, base of tongue cyst, ductal cyst [3]. In infants and children vallecular cysts present most commonly with stridor, failure to thrive [4] and feeding difficulty

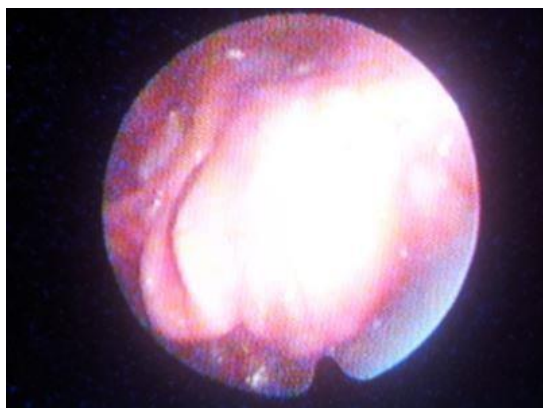
but may cause life threatening airway obstruction and death [3]. Here we are presenting a case of a vallecular cyst presented with noisy breathing.

## Case report

A 7 month old child was brought to outpatient department in department of ENT HNS, TUTH with complains of noisy breathing associated with feeding difficulty. There was no history of fever, cough, fast breathing. The patient was treated with

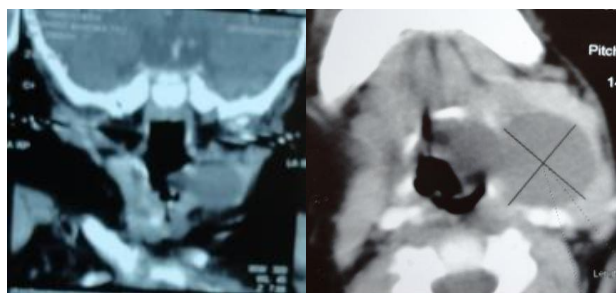
multiple medications with no improvement.

On routine examination all the findings were normal. Flexible nasopharyngolaryngoscopic examination was done which showed present of swelling in the left vallecula of size 3\*3cm pushing the epiglottis posteriorly and to the right with narrowed normal endolarynx (Figure 1).



**Figure 1: Endoscopic picture showing swelling in the left vallecula displacing epiglottis posteriorly**

Radiological investigations with CT scan showed 3.5cm\*2.5cm\*2.5cm cystic lesion noted in left side of neck with no septation and solid component. The lesion was extending to ipsilateral vallecula and paraglottic region with narrowing of endolarynx (Figure 2)



**Figure 2: CT scan of neck showing cystic lesion in left vallecula.**

With the provisional diagnosis of vallecular cyst in the left vallecula patient underwent deroofting and marsupialization of the cyst with electrocautery under general anesthesia. There was no recurrence even after two years follow up.

## DISCUSSION

The cause of a vallecular cyst is thought to be due to either an embryological malformation or obstruction of a mucous gland ducts [5,6]. Lymphatic malformation, angiomatous malformation also postulated as some of the potential causes of a vallecular cyst [7,8]. It usually arises from the lingual surface of epiglottis. It is epithelial lined cystic structure. Dilatation of crypts of the lingual tonsils is also considered another possible etiology. Histologically, it is epithelial lined cystic structure containing respiratory epithelium with mucous glands with an external squamous epithelium[3] often associated with lymphoid tissue. It contains clear, non infected fluid [3,9].

A vallecular cyst causes airway obstruction by its mass effect on hypopharynx [10] and also by posterior displacement of epiglottis resulting supraglottic obstruction[11]. This is significant when it is associated with laryngomalacia where airway collapse caused by negative airway obstruction exacerbated particularly during inspiration [12].

Infants present with sudden airway obstruction, which is observed immediately after birth or during the first weeks of life [3]. The main symptom is the congenital stridor [13] which is present in almost all patients described in the literatures. The mode of presentation

depends on the position and size of the cyst. Inspiratory stridor is the most frequent clinical presentation. Beside stridor dyspnea, feeding difficulties, cough, voice change, failure to thrive are other presentations [14]. Sometimes death has been reported due to severe laryngeal obstruction [15,16]. In literatures it has been mentioned as mortality almost 40% reported if not properly treated [17]. Patients may be asymptomatic at birth, but later develop obstructive symptoms that are occasionally exacerbated by an upper respiratory tract infection [18].

In adults it is usually asymptomatic but can present with globus, voice changes, dysphagia, odynophagia, dyspnea [19]. They can become infected and can result acute epiglottitis with or without abscess formation and life threatening airway obstruction [10,20]. Vallecular cysts may also be discovered during general anaesthesia administration where they may obscure view of glottis and cause difficult endotracheal intubation [21,22]. In such cases simple aspiration followed by intubation with laryngeal mask may help manage difficult airway [23]. Rarely such cyst may present as sudden death in adults. Common differential diagnoses of the vallecular cyst include thyroglossal duct cyst, dermoid cyst, lingual cyst, lingual thyroid, lymphangioma and hemangioma [18, 24].

Diagnosis of a vallecular cyst requires a high index of clinical suspicion. Flexible endoscopy can be done as initial workup but direct laryngoscopy is the main investigation tool for diagnosis of a vallecular cyst, as the presence of the lesion can be confirmed and the degree of airway compromise can be assessed [25]. As a part

of initial workup, the diagnosis can be suggested by a lateral neck radiograph. Ultrasound helps in distinguishing the cystic nature of the lesion while CT scan is helpful in delineation the location and its extent in relation to the base of the tongue, vallecula, thyroid gland and particularly with neurovascular structures helping surgical exploration [25].

Antenatal diagnosis of this condition with ultrasound scanning 28 weeks of gestation and magnetic resonance imaging have been reported and would facilitate appropriate counseling and preparation at delivery [26].

Postnatally direct laryngoscopy can be done to rule out other associated condition like laryngomalacia [12]. These cysts are rarely associated with fetal anomalies. However polyhydramnios, pulmonary hypoplasia, trachea, cervical vessels, hypoglossal nerve compression have been described [27].

Treatment options of vallecular cyst include conservative management (wait and see) for asymptomatic patients [28], cyst aspiration, marsupialization [29], surgical debulking, laser excision [3,11,12,30]. As treatment with aspiration only results more chance of recurrence, it isn't recommended [5].

Marsupialization can be done with electrocautery or CO2 laser [3]. Carbon dioxide laser is reportedly useful as it can vaporize the epithelial lining to prevent recurrence [3]. First marsupialization with diathermy then remaining fragments of the lesion cystic wall using Nd: YAG laser has been described in literatures which allows sharp dissection without oedema and discharge on first postoperative day.

For larger lesions surgical access to base of tongue masses can be achieved transorally but greater exposure is provided via transcervical procedures using a mandibulotomy, lateral pharyngotomy or transhyoid approach. Cyst removal by open surgical resection with external laryngofissure via lateral cervical approach is described in literatures.

Surgical treatment in adults consists of transoral power assisted marsupialization of the cyst using microdebrider is also described in literature [28]. Use of tonsillar snare for excision has also been mentioned [5].

Recurrence of disease is very high. Recurrence with simple excision is due to leaving the cyst wall. In such cases it is mentioned that it is essential to perform a marsupialization of the cyst with laryngeal knife, laser or diathermy.

## CONCLUSION

Vallecular cyst is rare cause of noisy breathing in infants and children. In adults it is usually asymptomatic. Treatment of choice is marsupialization with electrocautery or laser.

## ACKNOWLEDGEMENT

Authors would like to acknowledge to the patient who permitted to get it published.

## AUTHOR'S CONTRIBUTION

**NL, RPSG-** were involved in writing the entire article and did all the literature review. All authors read, finalised and approved the article.

**SOURCE OF SUPPORT:** Department of ENT-HNS, TUTH

**CONFLICT OF INTEREST:** There's no conflict of interest regarding the publication of this paper. It hasn't been presented till date in any forms.

## REFERENCES

1. Pak MW, Woo JKS, van Hasselt CA. Congenital laryngeal cysts: current approach to management. *The Journal of Laryngology & Otol* 1996;110(9):854-6.
2. Abercrombie Congenital cyst in larynx. *Transactions of the Pathological Society of London* 1881;32:33-4.
3. Gutiérrez JP, Berkowitz RG, Robertson CF. Vallecular cysts in newborns and young infants. *Pediatr Pulmonol* 1999;27(4):282-5.
4. Conway EE BM, Wirtshafter K, Gereau S, Bassila M. Epiglottic cyst: An unusual cause of stridor in an infant. *Pediatr Emerg Care* 1991;7:85-6.
5. Bhandary S. Innovative surgical technique in the management of vallecular cyst. *Online Journal of Health and Allied Sci* 2003;2(3).
6. Gaxa L, Hlatshwayo BE, Modishi MH. Vallecular cyst. *Case Reports International (CRINT)* 2015;4:6-10.
7. Cuillier F SS, Testud R, Fossati P. Antenatal diagnosis and management of a vallecular cyst *Ultrasound Obstet Gynecol* 2002;20(6):623-6.
8. Ruben R, Kucinski S, Greenstein N. Case report: Cystic lymphangioma of the vallecula. *Can J Otolaryngol* 1975;4(1):180-4.
9. Yang M, Kang MJ, Hong J, Shin SH, Kim SD, Kim E-K, et al. A case of congenital vallecular cyst associated with gastroesophageal reflux presenting with stridor, feeding cyanosis, and failure to thrive. *Korean journal of pediatrics* 2008; 51(7):775-9.
10. Pandian S, Govarthanaraj A. Symptomatic vallecular cyst—how I do it? *International Journal of Pharma and Bio Sci* 2014;5(2):P348-P51.
11. Hsieh W-S, Yang P-H, Wong K-S, Li H-Y, Wang E-R, Yeh T-F. Vallecular cyst: an uncommon cause of stridor in newborn infants. *Eur J Pediatr*. 2000;159(1-2):79-81.
12. Ku A. Vallecular cyst: report of four cases—one with co-existing laryngomalacia. *The Journal of Laryngology & Otolaryngology*. 2000;114(3):224-6.
13. Breysem L, Goosens V, Vander Poorten V, Vanhole C, Proesmans M, Smet M. Vallecular cyst as a cause of congenital stridor: report of five patients. *Pediatr Radiol*. 2009;39(8):828-31.
14. Oluwole M. Congenital vallecular cyst: a cause of failure to thrive. *The British journal of clinical practice* 1996;50(3):170-2.

15. Porzionato A, Macchi V, Rodriguez D, De Caro R. Airway obstruction by laryngeal masses in sudden and homicidal deaths. *Forensic Sci Int* 2007;171(1):e15-e20.

16. Albert D, Ali Z. Two cases of vallecular cyst presenting with acute stridor. *The Journal of laryngology and otology* 1985; 99(4):421-5.

17. Wong KS, Li HY, Huang TS. Vallecular cyst synchronous with laryngomalacia: presentation of two cases. *Otolaryngology-Head and Neck Surgery* 1995; 113(5):621-4.

18. Mahajan V, Mathew JL, Singh M, Gupta R, Das A. Vallecular cyst-revisited. *The Indian Journal of Pediatrics* 2008;75(10):1081-2.

19. Arens C GH, Kleinsasser O. Clinical and morphological aspects of laryngeal cysts. *Eur ArchOtorhinolaryng* 1997;254:430-6.

20. Berger G, Landau T, Berger S, Finkelstein Y, Bernheim J, Ophir D. The rising incidence of adult acute epiglottitis and epiglottic abscess. *Am J Otolaryngol* 2003;24(6):374-83.

21. Kamble VA LR, Gross JB. Unanticipated difficult intubation as a result of an asymptomatic vallecular cyst. *Anaesthesiol* 1999;3:872-3.

22. Rivo JR M. Asymptomatic vallecular cyst: airway management considerations. *J Clin Anaesth J Clin Anaesth* 2001;13:383-6.

23. Kihara S, Watanabe S, Taguchi N, Brimacombe J. Airway rescue with the intubating laryngeal mask in a patient with an unexpectedly large epiglottic cyst. *AINS-Anästhesiologie· Intensivmedizin· Notfallmedizin· Schmerztherapie* 2000;35(12):774-5.

24. Leonardo GD FM, Sterfania N. Endoscopic treatment of vallecular cyst in newborn. *Int J of Ped Otorhinolaryngology Extra* 2009;4:10-3.

25. Aziz AA, Abdullah AF, Ahmad RAR. Two cases of congenital vallecular cyst: a reminder of the potentially fatal cause of upper airway obstruction in infants. *The Malaysian journal of medical sciences: MJMS* 2010;17(3): 68.

26. Cuillier F, Samperiz S, Testud R, Fossati P. Antenatal diagnosis and management of a vallecular cyst. *Ultrasound Obstet Gynecol* 2002;20(6):623-6.

27. Cullier F, Bidault J. Vallecular cyst. *The Fetus Net* 2001;12:4-15.

28. Pagella F, Pusateri A, Matti E, Tinelli G, Benazzo M. Transoral power-assisted marsupialization of vallecular cysts under local anesthesia. *The Laryngoscope*. 2013; 123(3):699-701.

29. Leibowitz JM, Smith LP, Cohen MA, Dunham BP, Guttenberg M, Elden LM. Diagnosis and treatment of pediatric vallecular cysts and pseudocysts. *Int J Pediatr Otorhinolaryngol* 2011;75(7):899-904.

30. Chen EY, Lim J, Boss EF, Inglis Jr AF, Ou H, Sie KC, et al. Transoral approach for direct and complete excision of vallecular cysts in children. *Int J Pediatr Otorhinolaryngol*. 2011; 75(9):1147-51.

**Correspondence to:**

**Dr. Nabin Lageju**

Consultant

Department of ENT-HNS,

Nepal Police Hospital, Nepal

Email: lagejunabin@gmail.com