

# Supernumerary Nipples, Congenital Scoliosis, Spina Bifida, Diastematomyelia, and Crossed Renal Ectopia in a child: Case Report of a Rare Combination.

Kiran Panthee,<sup>a,d</sup> Kiran Sharma,<sup>b,d</sup> Balkrishna Kalakheta<sup>c,d</sup>

## ABSTRACT:

**Introduction:** Supernumerary nipples are common anomalies which may be associated with several systemic disorders, particularly urinary tract abnormalities. **Case report:** Here we report a case of a 4½ year old male presenting to the pediatric out patient clinic with fever for three days and recurrent sinopulmonary infections. The child had supernumerary nipples over the right side with deformed thoracic cage, congenital scoliosis, diastematomyelia, crossed renal ectopia, and spina bifida. All the conditions present together did not match any syndrome reported till date. **Conclusion:** This was a rare syndrome and did not match fully with any known syndromes till date. This case warranted further investigation for its definite diagnosis but we do not have resources to that extent.

**Keywords:** ectopic • nipples • scoliosis • spina bifida • spinal cord

## INTRODUCTION:

Supernumerary nipples are common anomalies, and their significance is usually limited to cosmetic concerns. However, they are susceptible to hormonal changes and may signify internal disease. A high index of suspicion should be maintained during physical examinations, because any disease process that involves anatomically normal breasts may affect aberrantly located breasts or nipples. These anomalies may be associated with several systemic disorders, particularly urinary tract abnormalities.<sup>1,2</sup> There is a

higher prevalence for the left side and male gender.<sup>3</sup> In addition, it has been shown that supernumerary nipples are also associated with several syndromes including a lethal type of popliteal pterygium syndrome,<sup>4</sup> the Simpson-Golabi-Behmel syndrome,<sup>5</sup> and the Char syndrome.<sup>6</sup> Becker nevus syndrome is also reported to be associated with supernumerary nipples.<sup>7</sup> The association between supernumerary nipples, spina bifida, scoliosis and renal anomalies has been defined in many literatures.<sup>8,9</sup>

## CASE REPORT:

A 4½ year old male child presented to paediatrics out patient clinic with fever for three days and recurrent history of sinopulmonary infections. On general examination, he had supernumerary nipple at the right chest, along the nipple line with deformed thoracic cage and prominence over lumbosacral region. The child's anthropometry were as follows: head circumference 48 cm (3<sup>rd</sup> – 15<sup>th</sup> percentile), weight 13 kg (< 3<sup>rd</sup> percentile), height 81 cm (< 3<sup>rd</sup> percentile), Upper Segment (US): 37 cm, Lower segment (LS): 44 cm and US:LS = 0.84.

a - Lecturer,

b - Resident

c - Associate Professor

d - Department of Pediatrics,

Lumbini Medical College Teaching Hospital, Palpa, Nepal

## Corresponding Author:

Dr. Kiran Panthee

e-mail: keeranpanthee@gmail.com

## How to cite this article:

Panthee K, Sharma K, Kalakheta B. Supernumerary nipples, congenital scoliosis, spina bifida, diastematomyelia, and crossed renal ectopia in a child: case report of a rare combination. Journal of Lumbini Medical College. 2015;3(2):55-7. doi: 10.22502/jlmc.v3i2.74.

There was no consanguinity between the parents. The father was 26 years old and the mother was 22. The patient's birth history were uneventful. He was the second child of the family, first pregnancy was aborted at 1½ months period of gestation due to young age of mother, seven years back. On physical examination, the child had normal facies, supernumerary nipple on the right side (Figure 1), normal left nipple, scoliosis and lumbosacral prominence. Extremities were normal. Urogenital and rectal examinations were also normal. Chest radiology revealed deformation at the second, fourth and fifth ribs and agenesis of the third rib (Figure 2). Ultrasonogram of abdomen and pelvis revealed both kidneys towards the left side with other viscera within the normal location. Complete blood count, renal function test and liver function test were within normal limits. A karyotype of 46, XY was detected. Cardiac findings were normal and so was the cranial MRI. MRI and CT images reveal crossed renal ectopia (Figure 3), lumbar spina bifida with lipomyelocele and diastematomyelia (Figure 4).

**DISCUSSION:**

Solitary or multiple accessory nipples

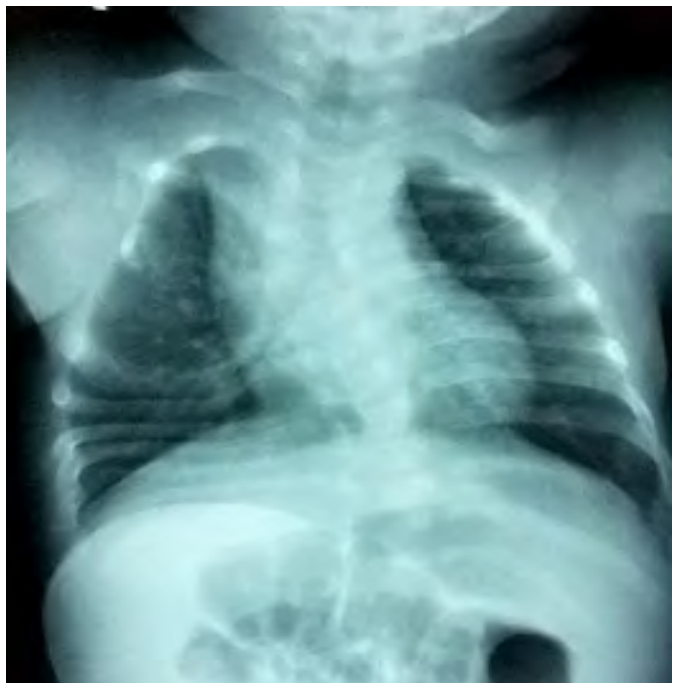

Figure 2: Chest radiology showing deformation at the second, fourth, and fifth rib and the scoliosis.

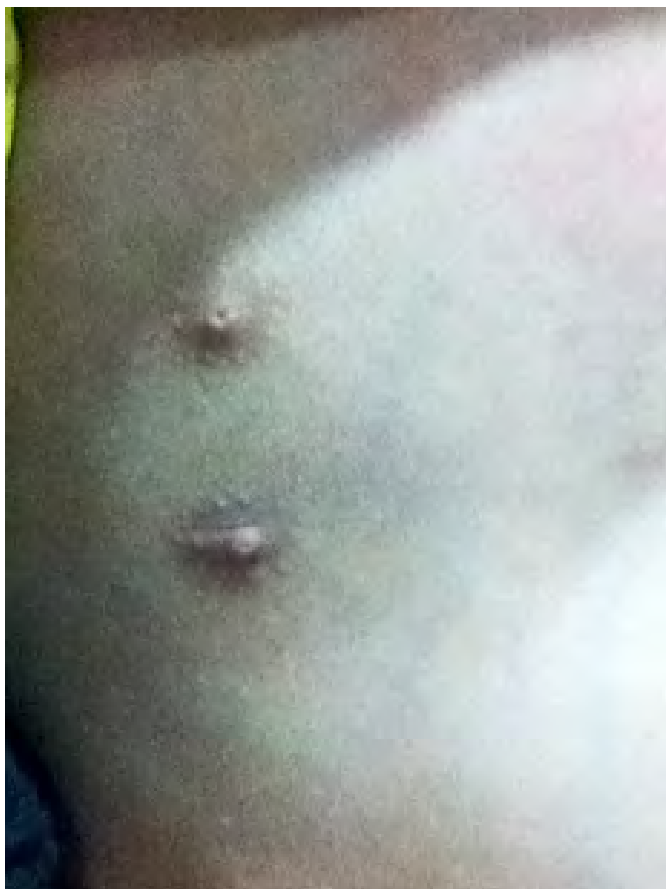

Figure 1: supernumerary nipple on the right side.

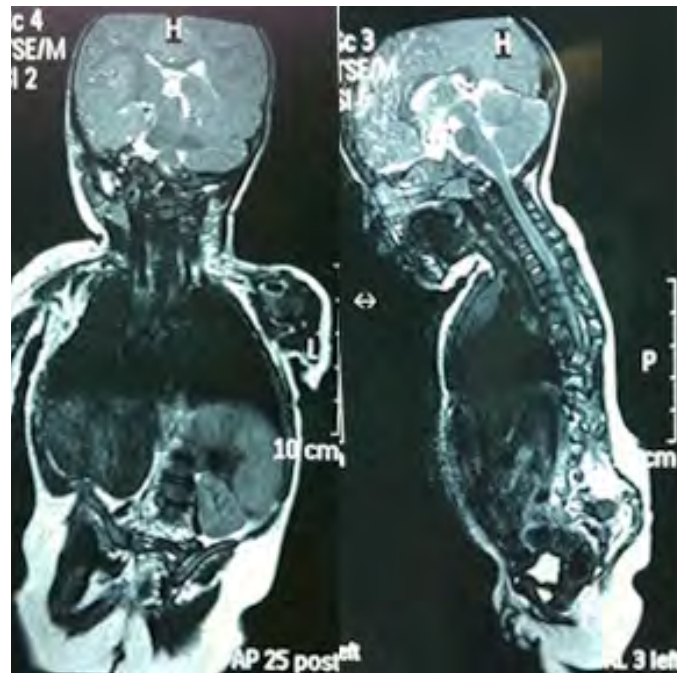


Figure 3: MRI image showing renal ectopia.

Figure 4: MRI image showing lumbar spina bifida with lipomyelocele and diastematomyelia.

may occur in a unilateral or bilateral distribution along a line from the anterior axillary fold to the inguinal area. More common among African-American (3.5%) than white (0.6%) children. Renal or urinary tract anomalies and hematologic abnormalities may rarely occur in children.<sup>10</sup> Several syndromes are reported that are associated with

supernumerary nipples.<sup>4,7</sup> It was not an autosomal dominant inheritance since none of the parents had similar anomalies. Supernumerary nipples was not an isolated entity as it was associated with other anomalies too. Supernumerary nipples and associated renal anomalies also has been identified in many literatures.<sup>8,11,12</sup>

## CONCLUSION:

This was a rare syndrome and did not match completely with any known syndromes. This case warrants further investigation for its definite diagnosis but we do not have resources to that extent.

## REFERENCES:

1. Newman M. Supernumerary nipples. *Am Fam Physician*. 1988 Aug;38(2):183-8.
2. Brown J, Schwartz RA. Supernumerary nipples: an overview. *Cutis*. 2003 May;71(5): 344-6.
3. Schmidt H. Supernumerary nipples: prevalence, size, sex and side predilection-- a prospective clinical study. *Eur J Pediatr*. 1998 Oct;157(10):821-3.
4. Shafeghati Y, Karimi-Nejad A, Karimi-Nejad R. Supernumerary nipples in a Bartsocas-Papas patient in a consanguineous Iranian family. *Clin Dismorphol*. 1999 Apr;8(2):155-6.
5. Hughes-Benzie RM, Hunter AG, Allanson JE, Mackenzie AE. Simpson-Golabi-Behmel syndrome associated with renal dysplasia and embryonal tumor: localization of the gene to Xqcen-q21. *Am J Med Genet*. 1992;43(1-2):428-35.
6. Zannolli R, Mostardini R, Matera M, Pucci L, Gelb BD, Morgese G. Char Syndrome: an additional family with polythelia, a new finding. *Am J Med Genet*. 2000 Nov;95(3):201-3.
7. Urbani CE, Betti R. Supernumerary nipple in association with Becker nevus vs. Becker nevus syndrome: a semantic problem only. *Am J Med Genet*. 1998 Apr;77(1):76-7.
8. Meggyessy V, Mehes K. Association of supernumerary nipples with renal anomalies. *J Pediatr*. 1987 Sep;111(3):412-3.
9. Panigrahi I, Saxena A, Marwaha RK. Congenital scoliosis, supernumerary nipples and spina bifida occulta. *Clin Dymorphol*. 2008 Jul;17(3):215-8. doi: 10.1097/MCD.0b013e3282fc6fdc.
10. Kliegman RM, Stanton BF, St Geme JW III, Schor NF, Behrman RE (eds). *Nelson TextBook of Pediatrics* (20th ed). Philadelphia: Elsevier Inc;2016.p.3119-20.
11. Brown J, Schwartz RA. Supernumerary nipples and renal malformations: a family study. *J Cutan Med Surg*. 2004;8(3):170-2.
12. Grotto I, Browner-Elhanan K, Mimouni D, Varsano I, Cohen HA, Mimouni M. Occurrence of supernumerary nipples in children with kidney and urinary tract malformations. *Pediatr Dermatol*. 2001;18(4):291-4.