

# Evaluation of marginal bone level after implant placement and before loading, by digital radiography

Sapkota B,<sup>1</sup> Upadhyaya C,<sup>2</sup> Rimal U,<sup>3</sup> Mahanta SK<sup>4</sup>

<sup>1</sup>Binam Sapkota, Associate Professor, Department of Prosthodontics; <sup>2</sup>Chandan Upadhyaya, Professor, Department of Oral and Maxillofacial Surgery; <sup>3</sup>Ujjwal Rimal, Lecturer, Department of Prosthodontics; <sup>4</sup>Swagat Kumar Mahanta, Assistant Professor, Department of Community Dentistry, Kathmandu University School of Medical Sciences, Dhulikhel Hospital, Dhulikhel, Kavrepalanchok, Nepal.

## Abstract

**Background:** Marginal bone loss around dental implant is one of the criteria for evaluating implant success.

**Objectives:** To evaluate the marginal bone loss around dental implants using digital radiographs and to determine correlation of mesial and distal bone loss around dental implants with gender and location in either arch in a period of 3-6 months after placement and before prosthetic loading.

**Methods:** An analytical study was undertaken from July 2021 till December 2021, after ethical clearance, in 18 patients on whom 23 implants had been placed at Dhulikhel hospital. After implant placement first radiograph was taken by CE 0297 size 2 PSP plate and Carestream (CS2100) intraoral periapical radiograph machine using paralleling technique (XcpRinn Device) and second at 3-6 months later. The radiographs were viewed using image viewer software (Vistasoft2.0.1) to calculate the bone level. Calculating the difference in bone level at zero month and at 3-6 months gave us the amount of bone loss which was entered in Excel sheet and transferred to SPSS v.22 for analysis and student unpaired-t test was used

**Results:** The mean bone loss was  $0.27 \pm 0.2$  mm on mesial aspect and  $0.13 \pm 0.3$  mm on distal aspect at the end of the study period. No statistically significant bone loss in relation to gender and location of implant placement was found.

**Conclusion:** Within the limitation of the study, no significant difference was found in the mesial and distal aspect of bone loss around dental implant when compared with different parameters.

**Key words:** Bone loss; Distal; Implant; Mesial; Osseointegration.

## Access this article online

**Website:** www.jkmc.com.np

**DOI:** <https://doi.org/10.3126/jkmc.v11i1.45494>

## HOW TO CITE

Sapkota B, Upadhyaya C, Rimal U, Mahanta S. Evaluation of marginal bone level after implant placement and before loading, by digital radiography. *J Kathmandu Med Coll.* 2022;11(1):48-51.

**Submitted:** Feb 16, 2022

**Accepted:** Apr 13, 2022

**Published:** May 24, 2022

## Address for correspondence

Dr. Binam Sapkota  
Associate Professor and Head,  
Department of Prosthodontics,  
Kathmandu University School of Medical Sciences,  
Dhulikhel Hospital, Dhulikhel, Kavrepalanchok, Nepal.  
Email: binamsapkota\_7@hotmail.com

Copyright © 2022 Journal of Kathmandu Medical College (JKMC)

**ISSN:** 2019-1785 (Print), 2091-1793 (Online)



This work is licensed under a Creative Commons Attribution-Non Commercial 4.0 International License.

## INTRODUCTION

People with edentulous mouth and using removable prosthesis may have restricted masticatory efficiency compared with natural dentition.<sup>1</sup> Dental implants serve well to overcome these problems and achieve patients' satisfaction. Dental implants are alloplastic materials having intimate contact with bone which is called osseointegration.<sup>1</sup>

Success or failure of implant depends on multiple factors and follow-ups during healing phase to evaluate the osseointegration, the predominant parameter in implant dentistry.<sup>2-4</sup> The marginal bone loss is the main clinical signs for assessment of implant success, along with alveolar bone loss less than 0.2 mm per year after the first year.<sup>5-7</sup> It has been found radiographically that prosthetic loading may aggravate the crestal bone loss. Conventional X-ray techniques cannot show minor bone changes whereas digital subtraction image (DSI) is a useful technique for detecting small lesions and assessment of bone height and 1-5% bone mineralisation detection.<sup>8</sup>

Amount of bone loss that would occur before prosthetic loading needs further evaluation. However, the most active phase of bone loss during the first few months has not been studied extensively. Keeping this in mind, the authors of this study aimed to evaluate marginal bone loss, occurring 3-6 months after the implant placement, but before prosthetic loading.

## METHODOLOGY

An analytical study was undertaken to evaluate the marginal bone loss on the mesial and distal aspect of implants, using digital radiograph. This study has been conducted among those patients who visited the Dental OPD (Department of Prosthodontics) from July 2021 till December 2021 after ethical clearance. Based on this time period a total of 18 patients on whom 23 implants had been placed were enrolled in this study.<sup>3</sup> Approval was obtained from Institutional Review Committee, Kathmandu University School of Medical Sciences, to conduct the study (Ref. 59/2021). Patients having periodontal disease, poor oral hygiene, insufficient bone with para functional habit, and medically compromised patients were excluded from the study. After screening, subjects were informed about the study and were divided into following groups based on two parameters: implant location (maxilla and mandible) and gender. Detailed medical and dental history with written consent was taken and implant was placed by single surgeon. Then radiographs were taken by using fCE 0297 size 2 PSP plate and Carestream (CS2100) intraoral periapical radiograph machine using paralleling technique (XcpRinn Device) at zero month (baseline, immediately after the implant placement) and again second radiograph at 3-6 months after but before prosthesis placement.

Images were produced by digital imaging technique with constant exposure parameters (Kvp: 60, mA: 7, sec: 0.32). The radiographs were viewed using image viewer software (Vistasoft 2.0.1). After taking coronal surface of implant as reference, a line was drawn perpendicular on mesial and distal side of implant to the first bone to implant contact (Figure 1, 2). The single investigator viewed the radiographs in a same room, same computer screen, under ambient light. Three readings were made and the average value was recorded for both mesial and distal side. Now subtracting the bone level at zero months from bone level at 3-6 months gave the value of bone loss. The data was tabulated in Excel sheet and transferred to IBM SPSS Statistics for Windows, version 22 (IBM Corp., Armonk, N.Y., USA) for analysis and student unpaired-t test was used to compare the measurements (statistical significance constructed at  $p < 0.05$ ).

## RESULTS

A total of 23 implants which were placed in 18 participants were included in the study in which 16 (69.6%) were males and seven (30.4%) were females. The mean bone loss was found to be  $0.27 \pm 0.2$  mm and  $0.13 \pm 0.3$  mm on mesial and distal aspects of dental implants respectively (Table 1). Unpaired t-test shows no significant difference in bone loss at mesial and distal sides ( $p = 0.279$  and  $0.683$  respectively) (Table 1).

Bone level on mesial and distal of implant on both maxillary and mandibular arch were also not statistically significant (Table 2). Mesial and distal bone loss were found to be similar in males at the end of the study (Table 3) but different for females (1.80 mm, 2.01 mm respectively). There is no statistically significant difference in bone loss on mesial and distal aspect when compared between gender ( $p = 0.32$ ,  $p = 0.17$  respectively) (Table 3).

**Table 1: Bone level on mesial and distal aspect of implant and mean bone loss**

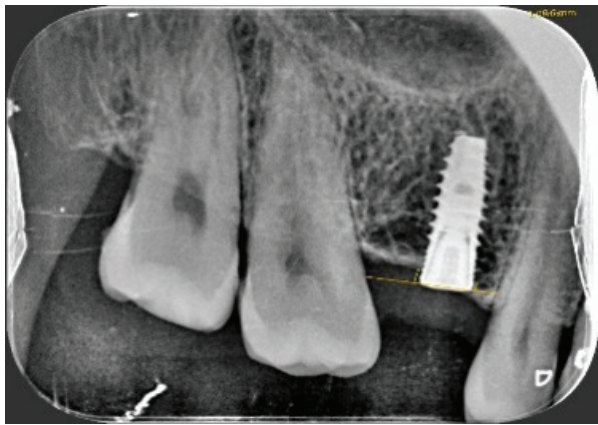
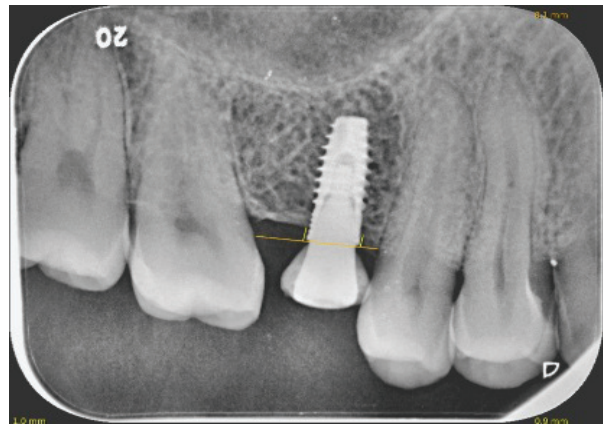
	Baseline (zero month)	3-6 months	Mean bone loss	p-value
Mesial	$1.235 \pm 0.77$ mm	$1.509 \pm 0.91$ mm	$0.27 \pm 0.2$ mm	0.279
Distal	$1.443 \pm 1.12$ mm	$1.574 \pm 1.02$ mm	$0.13 \pm 0.3$ mm	0.683

**Table 2: Bone level measurement for implant location (maxillary and mandibular arch)**

	Baseline (zero month)	3-6 months	p-value
Mesial aspect in maxillary arch	$1.15 \pm 0.74$	$1.36 \pm 0.85$	0.47
Distal aspect in maxillary arch	$1.51 \pm 1.17$	$1.61 \pm 1.16$	0.79
Mesial aspect in mandibular arch	$1.46 \pm 0.96$	$1.90 \pm 1.03$	0.50
Distal aspect in mandibular arch	$1.22 \pm 0.81$	$1.46 \pm 0.33$	0.55

**Table 3: Bone loss based on gender**

	Male	Female	p-value
Mesial	1.38 ± 0.91	1.80 ± 0.89	0.32
Distal	1.38 ± 0.91	2.01 ± 1.18	0.17

**Figure 1: Bone level at implant placement****Figure 2: Bone level after six months**

## DISCUSSION

The use of endosteal implants for rehabilitation represents one of the most technologically advanced form of dentistry available today. Endosteal implants are effective and appropriate for replacing single tooth, as well as for rehabilitating edentulous arches. Considering success and longevity, marginal bone area is usually a significant indicator of implant health.<sup>3</sup> The radiographic evaluation of bone forms a very important and viable means of detecting health and stability of bone around the peri-implant hard tissue. A decrease of crestal bone level indicates that the implant is loosening its bony anchorage.<sup>3,9</sup> It is clear that using precise methods of radiography is very important in the exact assessment of bone height around dental implants for further procedure to carry on.<sup>8</sup> Thus the current study aimed to determine bone loss on dental implant after 3-6 months of placement before prosthesis loading and its correlation between gender and location of implant (maxillary and mandibular arches).

Study done by Nandal et al. showed no significant difference in the bone loss on mesial and distal aspect of implant after a period of 3-6 months and also no significant difference in bone loss in gender as well as in different arch which is similar to the present study.<sup>3</sup>

In the study done by Turk et al.,<sup>10</sup> there was significant impact on bone loss among parameters like location

and gender in which different implant system, different prosthetic material has been used, which is contradictory to the present study in which no relation of bone loss in different parameters taken was found. Study by Bhardwaj et al. showed clinically significant marginal bone loss between the time of implant placement and three months where the implant has been placed following one stage technique which is also contradictory to the results of the current study which followed two stage technique.<sup>11</sup>

There are studies with different parameters showing presence of reduced marginal bone loss (MBL) in implant with microthreaded neck design hence this study recommended use of roughened neck implant to maintain bone level.<sup>12</sup> Likewise, study done by Galindo-Moreno et al.<sup>13</sup> showed internal conical connection implant with less MBL after 12 months follow-up from prosthetic loading. Another study by Lombardi et al.<sup>5</sup> showed early marginal bone (MB) remodelling was significantly influenced by implant insertion depth and factors related to biological width establishment which tended to stabilise and no MB loss after six months of prosthetic loading was observed. Although the time period and parameters are different but the result in the current study is similar which reported no relevant parameters in the development and progression of MBL.

## CONCLUSION

There were no statistically significant differences on marginal bone loss on mesial compared with distal aspect of implant after 3-6 months of placement. Similarly, there was no significant difference on different parameters like gender and location of implant on bone loss at the end of the study. Very few data owing to the limited studies done to evaluate bone loss before prosthetic loading further necessitates research on this area to have deeper knowledge regarding different parameters and their roles in MBL. Present study collected data from limited

pool of patients in specific site that is also the limitation of this study. Therefore, further studies are needed to generalise these results to a broader population and different area of the mouth. Hence continuous follow-up at a regular interval has been planned as a continuation of this study after prosthetic loading to evaluate the bone level.

**Conflict of interest:** None

**Source(s) of support:** None

## REFERENCES

- Zimmermann J, Sommer M, Grize L, Stubinger S. Marginal bone loss one year after implantation: A systematic review for fixed and removable restorations. *Clin Cosmet Investig Dent*. 2019 Jul 16;11:195-218. [[PubMed](#) | [Full Text](#) | [DOI](#)]
- Szymańska J, Szpak P. Marginal bone loss around dental implants with various types of implant-abutment connection in the same patient. *J Preclin Clin Res*. 2017;11(1):30-4. [[Full Text](#) | [DOI](#)]
- Nandal S, Ghalaut P, Shekhawat H. A radiological evaluation of marginal bone around dental implants: An in vivo study. *Natl J Maxillofac Surg*. 2014;5(2):126-37. [[PubMed](#) | [Full Text](#) | [DOI](#)]
- Koller CD, Pereira-Cenci T, Boscato N. Parameters associated with marginal bone loss around implant after prosthetic loading. *Braz Dent J*. 2016 May-Jun;27(3):292-7. [[PubMed](#) | [Full Text](#) | [DOI](#)]
- Lombardi T, Berton F, Salgarello S, Barbalonga E, Rapani A, Piovesana F, et al. Factors influencing early marginal bone loss around dental implants positioned subcrestally: A multicentre prospective clinical study. *J Clin Med*. 2019 Aug 4;8(8):1168. [[PubMed](#) | [Full Text](#) | [DOI](#)]
- Shen XT, Li JY, Luo X, Feng Y, Gai LT, He FM. Peri-implant marginal bone changes with implant-supported metal-ceramic or monolithic zirconia single crowns: A retrospective clinical study of 1 to 5 years. *J Prosthet Dent*. 2021 Feb;S0022-3913(20)30800-3. [[PubMed](#) | [Full Text](#) | [DOI](#)]
- Smith DE, Zarb GA. Criteria for success of osseointegrated endosseous implants. *J Prosthet Dent*. 1989 Nov;62(5):567-72. [[PubMed](#) | [Full Text](#) | [DOI](#)]
- Bittar-Cortez JA, Passeri LA, de Almeida SM, Haiter-Neto F. Comparison of peri-implant bone level assessment in digitized conventional radiographs and digital subtraction images. *Dentomaxillofac Radiol*. 2006 Jul;35(4):258-62. [[PubMed](#) | [Full Text](#) | [DOI](#)]
- Singh P, Garge HG, Parmar VS, Viiswambaran M, Goswami MM. Evaluation of implant stability and crestal bone loss around the implant prior to prosthetic loading: A six month study. *J Indian Prosthodont Soc*. 2006;6(1):33-7. [[Full Text](#)]
- Türk AG, Ulusoy M, Toksavul S, Güneri P, Koca H. Marginal bone loss of two implant systems with three different superstructure materials: A randomised clinical trial. *J Oral Rehabil*. 2013 Jun; 40(6):457-63. [[PubMed](#) | [Full Text](#) | [DOI](#)]
- Bhardwaj I, Bhushan A, Baiju CS, Bali S, Joshi V. Evaluation of peri-implant soft tissue and bone levels around early loaded implant in restoring single missing tooth: A clinico-radiographic study. *J Indian Soc Periodontol*. 2016 Jan-Feb;20(1):36-41. [[PubMed](#) | [Full Text](#) | [DOI](#)]
- Niu W, Wang P, Zhu S, Liu Z, Ji P. Marginal bone loss around dental implants with and without microthreads in the neck: A systematic review and meta-analysis. *J Prosthet Dent*. 2017 Jan; 117(1): 34-40. [[PubMed](#) | [Full Text](#) | [DOI](#)]
- Galindo-Moreno P, Concha-Jeronimo A, Lopez-Chaichio L, Rodriguez-Alvarez R, Sanchez-Fernandez E, Padial-Molina M. Marginal bone loss around implants with internal hexagonal and internal conical connections: A 12-month randomised pilot study. *J Clin Med*. 2021 Nov;10(22):5427. [[PubMed](#) | [Full Text](#) | [DOI](#)]