

Primary amoebic meningoencephalitis due to *Naegleria fowleri*

A. Angrup, L. Chandel, A. Sood, K. Thakur, S. C. Jaryal

Department of Microbiology, Dr. Rajendra Prasad Government Medical College, Kangra at Tanda, Himachal Pradesh, Pin Code- 176001, India.

Correspondence to: Dr. Archana Angrup, Department of Microbiology, Dr. Rajendra Prasad Government Medical College, Kangra, Tanda, Himachal Pradesh, Pin Code-176001, India. Phone no. 09418119222, Facsimile: 01892-267115

Email: archanaangrup@yahoo.com

Abstract

The genus *Naegleria* comprises of free living ameboflagellates found in soil and fresh water. More than 30 species have been isolated but only *N. fowleri* has been associated with human disease. *N. fowleri* causes primary amoebic meningoencephalitis (PAM), an acute, often fulminant infection of CNS. Here we report a rare and first case of PAM in an immunocompetent elderly patient from this part of the country. Amoeboid and flagellate forms of *N. fowleri* were detected in the direct microscopic examination of CSF and confirmed by flagellation test in distilled water, demonstrating plaques /clear areas on 1.5% non nutrient agar and its survival at 42°C.

Keywords: Meningitis, *Naegleria fowleri*, primary amoebic meningoencephalitis

Introduction

Infection of the central nervous system (CNS) in human beings with free living amoebae is uncommon. Among the many different genera of amoebae, *Naegleria spp*, *Acanthamoeba spp* and *Balamuthia spp* are primarily pathogenic to the CNS. These free living amoebae have been isolated from wide variety of fresh and brackish water including that from lakes, ponds, swimming pools, hot springs, heating and air conditioning units, taps etc.¹ PAM caused by *Naegleria fowleri* was first reported in 1965 by Fowler and Carter in Australia.²

Naegleria fowleri is also known as “Brain eating amoeba”. It belongs to Phylum Percolozoa, Class Heterolobosea, Order Schizopyrenida, and Family Vahlkampfiidae. Invasion occurs when the amoebae penetrate the nasal mucosa through the cribriform plate and travel along the olfactory nerves to the brain. *Naegleria fowleri* causes a fulminating meningoencephalitis mostly in children and healthy young adults who have a recent history of swimming in fresh water lakes, pools and ponds.³ Rare cases of infection by inhalation of air borne cysts have also been reported.⁴ To date, 440 cases have been documented worldwide mostly from the United States, Australia and Europe.^{1,5} To the best

of our knowledge, in India, only eight cases have been reported so far.^{1,5-8}

We hereby report a rare case of PAM in elderly immunocompetent patient from the hilly state of Himachal Pradesh (H.P) in Northern India.

Case report

An 85 years old male patient was admitted to the emergency department of Dr. Rajendra Prasad Government Medical College (DRPGMC), Kangra at Tanda, H.P, India with a history of fever, altered sensorium, severe headache, delirium and loss of speech for the last five days. The fever was of high grade (104°F) and associated with chills and rigors. There was no prior history of any medical illness / immune compromise. As per his attendants, there was a history of travel to Goa (western part of the country) a week prior to the onset of disease where he had taken bath in a pond. At that time the region was experiencing an unusually hot summer. On the way back to his home town he became severely ill and was admitted to our hospital.

On general physical examination, he was febrile (104°F), blood pressure and pulse were normal. The patient was unable to respond to commands. There was no evidence of

Primary amoebic meningoencephalitis

any cranial nerve involvement, focal deficits or seizures. Rest of the systemic examination was normal. Laboratory investigations revealed Haemoglobin concentration- 10.4 g/dl, Total Leukocyte Count (TLC) - 6300/mm³, DLC- 70% neutrophils, 28% lymphocytes and 2% eosinophils. Peripheral smear for parasites was negative. The serum electrolyte picture showed sodium- 136mmol/liter, potassium- 3 mmol/litre, HCO₃ - 21 mEq/l and Cl- 100 mEq/l, fasting blood sugar level - 122 mg/dl. Liver and renal function tests were within normal limits. Rapid test for HIV 1 and HIV 2(Comb AIDS™-RS, HIV 1+2 Immunodot kit) was non reactive. MRI of brain revealed cortical atrophy with ischaemic leukoariaosis in the periventricular white mater. Lumbar puncture was done and CSF sent for cytology, biochemistry and microbiological investigations. On gross examination, CSF was slightly turbid. The cell count was 15 cells/mm³ with a predominance of polymorphonuclear cells. Gram staining and culture of CSF were negative for bacteria and fungus. India ink preparation for *Cryptococcus neoformans* was also negative. Biochemical analysis showed sugar level of 80 mg/dl, proteins at a concentration of 125mg/dl and Cl- 120mEq/L. Wet mount of CSF showed actively motile trophozoites (amoeboid and flagellate forms). The amoeboid forms were 10-30µm in diameter, having a clear nucleus and a pseudopodium (Fig. 1). Amoebae undergoing binary fission could also be observed. The flagellate forms were pear shaped (15-30µm) with two flagella that were beating continuously making the organism move forward (Fig. 2). A contractile vacuole was also seen within the cytoplasm of the flagellate form. Giemsa stain showed amoeboid forms. Then the CSF was aseptically inoculated on 1.5% non-nutrient agar preseeded with an unspecified strain of *Escherichia coli* and incubated at 37°C. The plates were viewed daily for a period of one week to see areas of clearing or plaques. The lawn culture showed areas of clearing or plaques after 24 hours of inoculation which increased in size after 48 hours (Fig. 3). On microscopic examination: smooth, round, refractile double walled cystic forms measuring 9-10µm in diameter were seen (Fig. 4). These were transferred to sterile distilled water to induce flagellation. An oval to round, motile flagellated forms of size of 15µm were observed after one hour of inoculation. When the organism was exposed to a temperature of 42°C, it survived which distinguished it from non-pathogenic species of *Naegleria*. Based on clinical history, presence of trophozoites on wet mount of CSF, positive flagellation test, demonstration of plaques in non-nutrient agar plate and survival at 42°C, the organism was identified as *Naegleria fowleri*.⁹

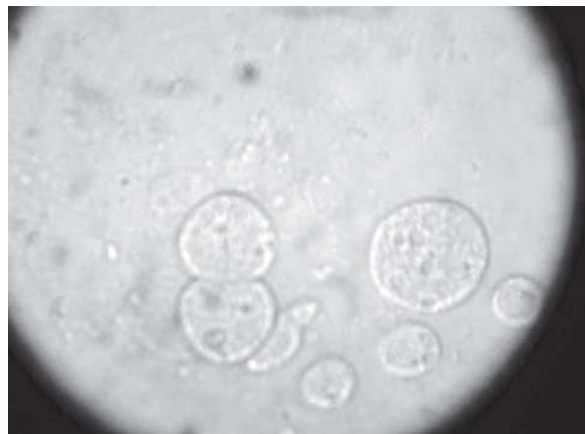

Fig. 1: Amoeboid form of *Naegleria fowleri* undergoing binary fission (arrow).

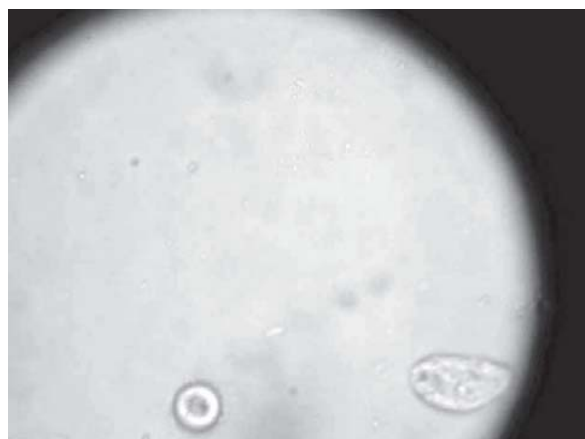

Fig. 2: Flagellate form of *Naegleria fowleri*.

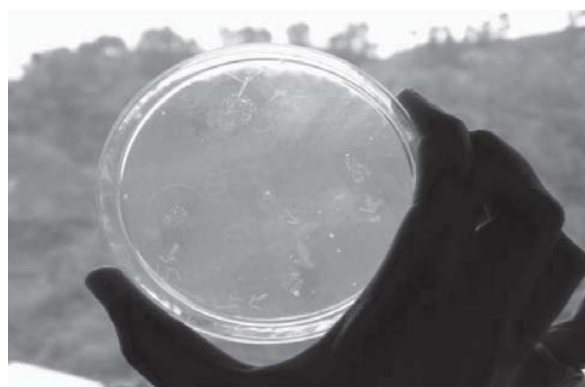

Fig. 3: Culture on 1.5% non nutrient agar showing areas of clearing.

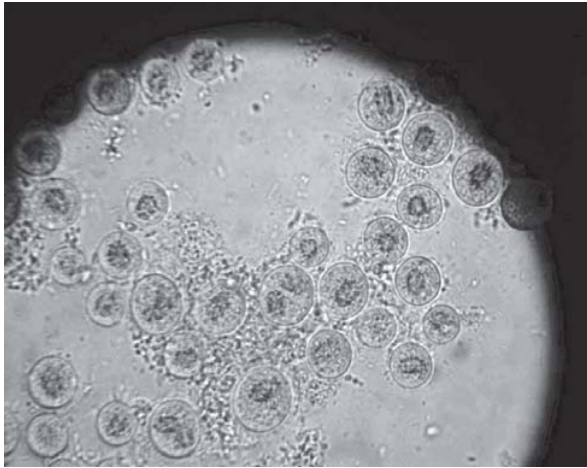


Fig. 4: Cystic forms of *Naegleria fowleri* in culture (10X magnification).

Initially thinking it to be pyogenic meningitis, empiric therapy with ceftriaxone, hydrocortisone, mannitol and azithromycin was started with which the patient showed no improvement. After confirmation of diagnosis of PAM due to *Naegleria fowleri* from our department, the patient was switched on to Amphotericin B and Rifampicin therapy. He showed some improvement in sensorium; became stable and was shifted to another hospital on the request of relatives and therefore could not be followed up further.

Discussion

Primary amoebic meningoencephalitis is still unfamiliar to many clinicians, pathologists and microbiologists. Most human infections with *Naegleria spp.* have been associated with swimming in warm water. The portals of entry for human infection are the nasal passages and the olfactory neuroepithelium which are usually exposed to the flagellate stage during periods of swimming or bathing in hot baths or springs.¹⁰ Incubation period varies from 3 to 8 days with an acute and rapidly fatal course. PAM is difficult to differentiate from acute bacterial meningitis on clinical grounds. Most of the patients die within a week after the onset of the illness.³

PAM occurs chiefly in healthy children and young adults who have recently swum in warm freshwater lakes or ponds. The average age in the eight Indian cases of the PAM was 13.06 years (range 5 months-36 years).¹ Our case is unique as the patient was an 85 years old elderly immunocompetent male, with a history of exposure to pond water. The disease has not been previously reported in such an extreme old age. Patient's survival depends on an initial awareness of

the organism and laboratory confirmation by growing it in a liquid axenic media or 1.5% non-nutrient agar plates, flagellation test, exposition to higher temperature, biochemical and molecular methods.^{11,12} In the present case, the clinical and epidemiologic history demonstrated that the patient contracted PAM seven days after swimming in pond water during the unusually hot summer. Laboratory investigations confirmed the clinical suspicion. The CSF cell count and glucose level in the present case was low as the patient was in the early stages of the disease.¹⁰ To the best of our knowledge, this is the first diagnosed occurrence of PAM in an elderly immunocompetent patient in H.P, India.

The majority of reports of PAM are from the developed countries. This is not because of greater incidence of the disease in developed countries but due to a greater awareness among the clinicians and microbiologists. Previously only few clinicians and microbiologists in India were aware of the potential danger presented by these free living, pathogenic species of amoebae and therefore, many cases may have gone undiagnosed. But for the last 9-10 years, cases are being reported from India also, it shows the increasing awareness towards the disease among the medical fraternity.

The prognosis of this entity is poor with a mortality rate as high as 95%.¹⁰ Though CDC has recommended treatment with Amphotericin B but the survival rate remains less than 1% in PAM cases.¹³ Only four patients are known to have survived till date in India who were treated with Amphotericin B, rifampicin, miconazole and ketoconazole.⁸ The duration of treatment varied from 9 days to 6 weeks.¹ In our case the patient could not be followed up as he was referred to another nearby centre for further management.

It is emphasized that an increase in surface temperature of water will create ideal niches for the thermophilic *N.fowleri*.¹⁴ Here in our case also the infection was acquired during the summer month. Persons who swim, bathe or dive in pools or freshwater basins will increase their chances of coming in contact with *N.fowleri* and contracting PAM.

PAM occurs so rarely that active surveillance for *N.fowleri* in public swimming lakes is probably not justified as a public health measure. However, because of the occurrence of clusters of patients with PAM with common environmental exposures, health officials should consider closing the implicated water sources to swimming.¹⁵

In conclusion, although PAM is a rare disease with a poor prognosis, it should be considered in any patient with purulent CSF but no bacteria on Gram's staining and on culture of CSF. Wet mount of CSF therefore becomes mandatory in such cases to detect amoebae for timely

Primary amoebic meningoencephalitis

diagnosis and therapy with Amphotericin B to reduce morbidity and mortality. The present case report highlights the importance of including amoebic meningoencephalitis in differential diagnosis of pyogenic meningitis/encephalitis when CSF examination is negative for routine organisms and treatment with conventional anti meningitic drugs has failed.

References

1. Kaushal V, Chhina DK, Ram S, et al. Primary amoebic meningoencephalitis due to *Naegleria fowleri*. JAPI 2008;56:459-62.
2. Carter RF. Primary amoebic meningoencephalitis. An appraisal of present knowledge. Trans R Soc Trop Med Hyg 1972;66:193-208.
3. Warhurst DC. Water: infection caused by free living amoebae. In: P.E.C. Manson-Bahr, D.R. Bell, editors. Manson's tropical diseases. 19th ed. London, United Kingdom: ELBS Balliere Tindall; 1985.
4. Shenoy S, Wilson G, Prashanth HV, et al. Primary Meningoencephalitis by *Naegleria fowleri*: First reported case from Mangalore, South India. J Clin Microbiol 2004; 40:309-10.
5. Qvarnstrom Y, Visvesvara GS, Sriram R, et al. Multiplex real-time PCR assay for simultaneous detection of *Acanthamoeba* spp, *Balamuthia mandrillaris* and *Naegleria fowleri*. J Clin Microbiol 2006;44:3589-95.
6. Pan NR, Ghosh TN. Primary amoebic meningoencephalitis in two Indian children. JIMA 1971;56:134-7.
7. Singh SN, Patwari AK, Dutta R, et al. *Naegleria meningitis*. Indian Pediatrics 1998; 35:1012-5.
8. Jain R, Prabhakar S, Modi, et al. *Naegleria meningitis*: A rare survival. Neurology India 2002;50:470-2.
9. Martinez AJ. Free-living amoebas: Natural history, prevention, diagnosis, pathology and treatment of disease. Boca Raton Fla; CRC Press; 1985.
10. Mandall GL. Free- living amebas. In: Mandall, Douglas and Bennett's Principles an Practice of Infectious Diseases. 6th ed. London: Elsevier Churchill Livingstone; 2005. p. 3111-20.
11. Bottone EJ. Free-living amebas of the genera *Acanthamoeba* and *Naegleria*: an overview and basic microbiologic correlates. Mt. Sinai J. Med 1993;60:260-70.
12. Pougard et al. Rapid detection and enumeration of *Naegleria fowleri* in surface waters by solid-phase cytometry. Applied and Environmental Microbiology 2002; 68(6):3102-07.
13. Matthews S, Ginzl D, Walsh D. Primary amoebic meningoencephalitis- Arizona, Florida, and Texas.. Mort Morb Wkly Rep. 2007;57(21):573-7.
14. Paola EC, Scaglia M, Gatti S, et al. Fatal *Naegleria fowleri* meningoencephalitis, Italy. Em Infect Dis 2004;10:1835-7.
15. Dos Santos JG. Fatal primary amebic meningoencephalitis. A retrospective study in Richmond, Virginia. Am J Clin Pathol 1970;54:737-42.