

Polyneuritis cranialis: A rare variant of Guillain Barré syndrome

Elina Maharjan^{1*}, Namrata Pandey¹, Sunil Maharjan¹, Niranjan Acharya¹, Rochak Kansakar²

¹Civil Service Hospital, Kathmandu, Nepal, ²Kathmandu Neuro and General Hospital, Kathmandu, Nepal

ABSTRACT

Polyneuritis cranialis is a rare variant of Guillain-Barré Syndrome. We hereby report a thirty-year-old male with symptoms of headache, vomiting, and blurred vision. Polyneuritis Cranialis was confirmed after considering clinical findings, examinations, and laboratory tests while ruling out other differentials. Intravenous Immunoglobulin treatment over five days led to gradual improvement and discharge on the twentieth day post-admission.

Keywords: Cranial nerve palsies, Guillain barré syndrome, polyneuritis cranialis.

*Correspondence:

Dr. Elina Maharjan
Civil Service Hospital, Kathmandu, Nepal
Email Id: eelinamhr@gmail.com
ORCID iD: 0000-0002-3095-1603

Submitted: January 19, 2024

Accepted: June 10, 2024

To cite: Maharjan E, Pandey N, Maharjan S, Acharya N, Kansakar R. Polyneuritis cranialis: A rare variant of Guillain Barré syndrome. JGMC Nepal. 2027;17(1):100-2.
DOI: 10.3126/jgmcn.v17i1.60144

INTRODUCTION

Polyneuritis Cranialis is one of the rare variants of Guillain Barré Syndrome (GBS).¹ Based on the clinical features the GBS spectrum is classified into three groups. They are GBS, Miller-Fisher Syndrome (MFS), and GBS-MFS interface.² Polyneuritis cranialis falls under the GBS-MFS interface due to the overlapping clinical features it shares with both GBS and MFS. It is characterized by the rapid development of symmetrical cranial nerve palsies, particularly bilateral facial palsy, without the presence of limb weakness, sensory involvement, ataxia, or loss of deep tendon reflexes. The nerves usually affected in Polyneuritis Cranialis are IV, V, VI, and VII.³ Its etiology has been contributed to many categories such as inflammatory, infectious, autoimmune, toxins, and idiopathic.³

This case study aimed to contribute to the existing knowledge on polyneuritis cranialis by presenting a detailed case report of a patient's clinical presentation, investigations, and management.

CASE REPORT

A thirty-year-old male presented to the Emergency ward with headache and vomiting for two days. Headache was gradual on onset, progressive, located at the occipital region associated with blurring of vision and slurring of speech followed by vomiting. On physical examination, he was afebrile and hemodynamically stable. Bilateral ptosis was observed, but there were no signs of weakness or numbness in the limbs, areflexia, signs of meningism, other neurological deficits, or systemic symptoms. Initial investigations, including complete blood count, C-reactive protein, erythrocyte sedimentation rate, and basic metabolic panel yielded normal results. A lumbar puncture was performed and cerebrospinal fluid analysis showed albumin-cytological dissociation with increased protein and normal glucose levels. Tuberculosis polymerase chain

reaction and cryptococcus antigen test were negative as shown in Table 1.

Table 1: Laboratory reports

Investigations	Reports
Complete blood count	Normal
C- Reactive Protein	Normal
ESR	Normal
Basic Metabolic Panels	Normal
	Total count: normal
	Protein: high
	Glucose: Normal
	ADA: Normal
CSF Routine Analysis	Negative
CSF TB PCR	Negative
CSF Cryptococcus antigen	Negative
Plain CT -Head	Normal
Ultrasonography of the abdomen and pelvis	Normal

The patient was admitted and treated with intravenous ceftriaxone at a dosage of two grams administered twice daily, along with maintenance intravenous fluid. On the second day of admission, MRI brain screening and MRV brain were done which showed no abnormal findings as shown in Figure 1. To prevent viral illness, intravenous Acyclovir at a dosage of 750 micrograms three times a day was given. However, on the third day of admission, the patient developed dyspnea and restlessness, with subsequent progression to an inability to swallow and excessive drooling. Clinical examination revealed an absent gag reflex. His oxygen saturation suddenly dropped with a GCS of 3/15. The patient was intubated and placed on mechanical ventilation in VC mode. Additional investigations, including complete blood count, serum electrolytes, thyroid function tests, pan culture, fever profile, and Anti-HCV antibody, ice-pack test, ACh receptor antibody (Ab), ASKA antibody test, and Anti-MUSK antibody test were sent. All of these tests yielded negative results. Additionally, the Serum Aquaporin and Anti-MOG antibody tests, levels of Anti-nuclear antibody (ANA) and Serum angiotensin converting enzymes were within the normal range, as indicated in Table 2. The diagnosis of polyneuritis cranialis was made based on the diagnosis of exclusion and cerebrospinal fluid analysis reports.

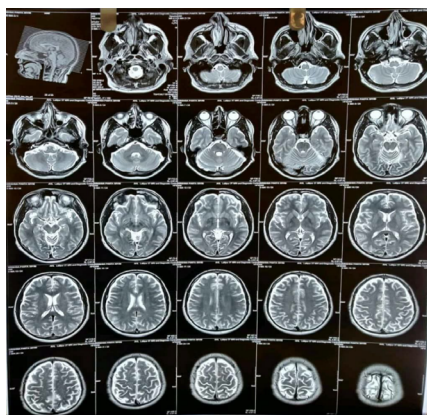


Figure 1: MRI scan head showing normal findings (29/04/2023)

Table 2: Laboratory reports

Investigation	Reports
ACh receptor Ab	Negative
ASKA antibody test	Negative
Anti-Musk Ab test	Negative
Serum Aquaporin and Anti-MOG antibody	Negative
Anti-nuclear Antibody (ANA)	Normal
ACE level	Normal

He was treated with intravenous Immunoglobulin (IVIG) @2g/kg on a divided dose for five days. After three days of IVIG course completion, on clinical assessment gag reflex was present, bilateral ptosis was absent and the patient was extubated. The patient was discharged on the 20th day of admission. He was followed up after one week. A nerve conduction test was done which showed mild motor axonopathy affecting the bilateral lower limb as shown in figure 2.

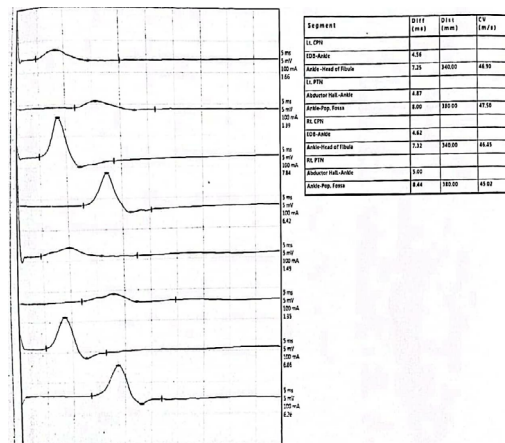


Figure 2: Nerve conduction test showing mild axonopathy in bilateral limb (19/05/2023)

DISCUSSION

The rarity of polyneuritis cranialis made it difficult to establish a definitive diagnosis. Progressive weakness of more than one limb and loss of tendon jerk are the key features of Classical GBS.^{2,3} These features were observed in a 65 years old male from Iran.⁴ However, our patient did not exhibit any abnormalities in deep tendon reflexes. Miller Fisher is another variant of GBS that presents similarly as polyneuritis cranialis. The presence of ophthalmoplegia, ataxia, and areflexia is typical for Miller-Fisher Syndrome.⁵ These findings were seen in a 42-year-old woman from New York, USA.⁶ Its absence made the diagnosis unlikely in our patient.

Considering the presence of ptosis, myasthenia gravis was considered as a possible diagnosis similar to a finding in a 65-year-old female from USA.⁷ However, the Neostigmine test and measurement of acetylcholine esterase antibodies were done and the results concluded negative with regards to our patient. Isolated cranial nerve palsies in multiple

sclerosis are not frequent; however, the presence of normal MRI findings and negative autoantibodies like ANA in our patient excluded the possibility of multiple sclerosis.

We confirmed as, he presented with cranial nerve palsies affecting the III, VII, and XII cranial nerves and his CSF analysis showed albumin-cytological dissociation with increased protein and normal glucose levels. His radiological findings were normal, similar to the case report of a 62-year-old man from Japan.⁸ Unfortunately, the nerve conduction test could not be done in initial phase due to the unavailability of such testing facilities in our center. IVIG is a practical, safe, and effective treatment for Guillain-Barre Syndrome.⁹ In our case, the patient showed significant improvement from the third day of Immunoglobulin therapy. An acute relapse following initial recovery with IVIG sometimes occurs and needs to be detected early to prevent life-threatening complications.¹⁰

CONCLUSIONS

Here, we present the case of polyneuritis cranialis of idiopathic etiology involving III, VII, and XII cranial nerves in Nepal. Atypical nature of the disease, along with its resemblance to other disorders makes it a diagnostic challenge. Therefore, physicians must be well aware of this condition for timely intervention and prompt initiation of treatment in order to improve outcomes.

ACKNOWLEDGEMENT

We would like to thank the doctors and nursing teams of the critical care unit, at Civil Service Hospital for their support.

CONFLICTS OF INTEREST: None declared

SOURCE OF FUNDING: None

AUTHORS' CONTRIBUTION

EM contributed in proposal design and manuscript writing. SM contributed in literature review. RK contributed in discussion writing. NP designed the abstract and NA contributed as a chief editor. Final editing and confirmation has been given by all the authors.

PATIENT CONSENT

Informed written consent was obtained for the study and publication of this case report along with the attached images.

REFERENCES

1. Wakerley BR, Yuki N. Polyneuritis cranialis—subtype of Guillain–Barré syndrome. *Nature Reviews Neurology*. 2015;11(11):664 DOI: 10.1038/nrneurol

PMID: 26369515.

2. Wakerley BR, Uncini A, Yuki N, GBS Classification Group. Erratum: Guillain–Barré and Miller Fisher syndromes—new diagnostic classification. *Nature Reviews Neurology*. 2014;10(11):612. DOI: 10.1038/nrneurol PMID: 25072194.
3. Asbury AK, Cornblath DR. Assessment of current diagnostic criteria for Guillain-Barré syndrome. *Annals of Neurology: Official Journal of the American Neurological Association and the Child Neurology Society*. 1990;27(S1):S21-4 DOI: 10.1002/ana.410270707 PMID: 2194422.
4. Sedaghat Z, Karimi N. Guillain Barre syndrome associated with COVID-19 infection: a case report. *Journal of Clinical Neuroscience*. 2020;76:233-5 DOI: 10.1016/j.jocn PMID: 32312628.
5. Fisher M. An unusual variant of acute idiopathic polyneuritis (syndrome of ophthalmoplegia, ataxia and areflexia). *New England Journal of Medicine*. 1956;255(2):57-65. DOI: 10.1056/NEJM195607122550201 PMID: 13334797.
6. Shah SS, Rodriguez T, McGowan JP. Miller Fisher variant of Guillain-Barré syndrome associated with lactic acidosis and stavudine therapy. *Clinical Infectious Diseases*. 2003;36(10):e131-3. DOI: 10.1086/374935 PMID: 12746793.
7. Sriwastava S, Tandon M, Kataria S, Daimee M, Sultan S. New onset of ocular myasthenia gravis in a patient with COVID-19: a novel case report and literature review. *Journal of Neurology*. 2021;268:2690-6 DOI: 10.1007/s00415-020-10263-1 PMID: 33047223.
8. Arakawa M, Yamazaki M, Toda Y, Ozawa A, Kimura K. An oculopharyngeal subtype of Guillain-Barré syndrome sparing the trochlear and abducens nerves. *Internal Medicine*. 2020;59(9):1215-7. DOI: 10.2169/internalmedicine.3395-19 PMID: 32023583.
9. Van der Meché FG, Schmitz PI, Dutch Guillain-Barré Study Group*. A randomized trial comparing intravenous immune globulin and plasma exchange in Guillain-Barré syndrome. *New England Journal of Medicine*. 1992;326(17):1123-9 DOI: 10.1056/NEJM199204233261705 PMID: 1552913.
10. Ojha R, Karn R. Clinical outcome of intravenous immunoglobulin in the treatment of Guillain Barre Syndrome in a Nepalese tertiary centre. *Nepalese Medical Journal*. 2019;2(1):133-7 DOI: 10.3126/nmj.v2i1.24000.