

The outcome of Transversus Abdominis Release for complex ventral hernia: A one-year of follow-up experience

Sagar Khatiwada*¹, Narayan Prasad Belbase¹, Suman Baral², Hari Prasad Upadhyay³, Sushim Bhujel¹, Nishnata Koirala¹

¹Department of Gastrointestinal and General Surgery, College of Medical Sciences, Teaching Hospital, Bharatpur, Chitwan, Nepal, ²Department of Surgery, Dirghayu Pokhara Hospital Ltd, Pokhara, Nepal, ³Department of Statistics, Birendra Multiple Campus, Bharatpur, Chitwan, Nepal

ABSTRACT

Introduction: Transversus Abdominis Release is a noble technique for the repair of complex ventral hernia, where the posterior component separation allows a huge pre-peritoneal space advantageous for the placement of large-sized mesh. It has less wound morbidity as compared to anterior component separation due to the preservation of skin perforators. The main objective of this study was to evaluate one-year follow-up results in terms of recurrence, wound morbidity, and various techniques for managing complications of Transversus Abdominis Release. **Methods:** This is a descriptive cross-sectional study that was conducted at the department of surgery, College of Medical Sciences Teaching Hospital. Among 41 patients with complex ventral hernia, 34 patients met the inclusion criteria. Demographic data, intra-operative events like bleeding, operative duration, intraoperative complications, post-operative events like duration of hospital stay, wound morbidity, and follow-up data were analyzed. **Results:** Posterior rectus sheath closure at midline was possible in 30 (88.2%) patients. In patients, where posterior rectus sheath closure was not possible, the peritoneum of hernia sac was tailored to patch the defect or in some omentum was placed below the raw surface of mesh. The average operative duration and blood losses were 130±12 minutes and 301±133 ml respectively. The semilunar line injury occurred in one case that was diagnosed and repaired at the same time and the TAR plane was re-established. Wound morbidity occurred in three cases that were managed by dressing with commercially available collagen and mupirocin granule. No recurrence was observed in one-year follow-up. **Conclusions:** Transversus Abdominis Release has a better result with no recurrence in short term follow up and fewer complications which are easily manageable.

Keywords: Hernia, incisional hernia, transverse abdominis release, ventral hernia.

*Correspondence:

Dr. Sagar Khatiwada
College of Medical Sciences Teaching Hospital
Bharatpur, Chitwan, Nepal
Email: sagarkhatiwada2064@gmail.com

Submitted: August 9, 2022

Accepted: December 26, 2022

To cite: Khatiwada S, Belbase NP, Baral S, Upadhyay HP, Bhujel S, Koirala N. The outcome of Transversus Abdominis Release for complex ventral hernia: A one-year of follow-up experience. JGMC Nepal. 2022;15(2):173-8. DOI: 10.3126/jgmcn.v15i2.48971

INTRODUCTION

After midline laparotomy, ventral hernia occurs in 9 to 22% of patients while after surgical repair of ventral hernia the recurrence rate is as high as 37%.^{1,2} In 1970, Rives and Stoppa described the retro-rectus repair of ventral hernia. The fusion fibers at linea semilunaris prevented the space to be generated beyond this landmark.³ Hence, midline fascial closure in a wider ventral hernia was difficult. Ramirez and colleagues addressed this issue by introducing anterior component separation (ACS) by division of external oblique and separating it from internal oblique muscles which allows midline shift and closure of linea alba even in wider hernia. However, ACS required creation of large lipo-cutaneous flaps sacrificing skin perforators resulting into flap necrosis, increased risk of surgical site infection (SSI) and the recurrence rate remained as high as 30%.⁴

In 2012, Novitsky et al. described Transversus Abdominis Release

(TAR) technique that generates huge extra-peritoneal space without raising lipocutaneous flaps and thereby reducing wound morbidity.^{5,6} A durable technique with a low recurrence rate, less wound morbidity, low and manageable complications are necessary. Therefore, the main objective of this study was to evaluate intraoperative challenges and recurrences in one year.

METHODS

A descriptive cross-sectional study was carried out by the department of surgery of College of Medical Sciences-teaching hospital (COMS-TH) among the patient who underwent TAR from March 1, 2019 to February 28, 2021. Data were collected from May 6 to June 17, 2022 after getting ethical approval from Institutional review committee (COMSTH-IRC/2022-015). Before data collection, informed and written consent were taken from patients. All the collected data was entered and analyzed by using statistical package for social sciences version 20.0.

Preoperative protocol of TAR

All patients were advised to abstain from smoking one month prior to surgery. In diabetic patients, glycemic control with glycosylated hemoglobin (HbA1c) was achieved at less than 6%. Hypothyroid and hypertensive patients were medically optimized, and each patient was operated on after the cardiac risk assessment from the cardiology department. Pre-operative CT-Scan was performed to assess the hernia sac volume. Segmentation and abdominal volumetry were also performed. We considered loss of domain as the major indicator of TAR, and calculation was performed as per Sabbagh.⁷ If the ratio of hernia sac volume (HSV) to total peritoneal volume (TPV) was more than 20%, the primary closure of rectus sheath was not possible or if it was possible, the risk of intra-abdominal hypertension remained.

Figure 1 shows CT-Scan image of 66 years old lady with ventral hernia. Figure 1A shows 9.4 cm of defect. Figure 1B shows the segmentation of CT-image, here after volume rendering, the ratio of HSV to TPV was more than 20%, suggesting the loss of domain. Confirmation of volumetry was done with radiologist.

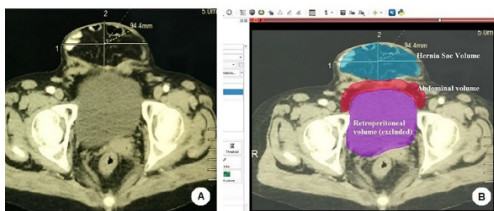


Figure 1: CT-Scan image of 66 years lady with a ventral hernia.

Surgical techniques

All patients were operated on under general anesthesia. After midline laparotomy and adhesiolysis, abdominal cavity was packed. We performed posterior approach where the intraperitoneal incision was given along the edge of posterior rectus sheath to create retro-rectus space.⁸ Retro-rectus dissection was carried out till the neurovascular bundle. An incision of Transverse abdominis muscle fibers known as Madrid modification along musculoaponeurotic transition (see figures 2d and 2e) was given.⁹ A wide pre-peritoneal space was created that connected space of Retzius and the space of Bogros caudally, laterally along the lateral border of the psoas muscle, and cranially at the edge of the diaphragm. Special care was taken to prevent injury of the neurovascular bundle, prevent the disruption of linea semilunaris, and inadvertent injury of diaphragmatic muscle fiber while entering the fibrofatty triangle. After creating pre-peritoneal space, the posterior rectus sheath at the midline was closed. In those cases whom posterior rectus sheath closure was not possible, PRS was bridged. To achieve this, either peritoneum from hernia sac was tailored to cover the defect or when sac can't be utilized due to Swiss cheese defect or recurrent hernia, omentum was laid just below the raw surface of mesh. After completion of this, a huge synthetic Polypropylene mesh was placed and fixation of mesh was done on both sides of the anterior superior iliac spine (ASIS), caudally floating ribs (coastal fixation), and midline respectively. After fixation of mesh, two negative pressure drain was placed and anterior rectus sheath was closed.

For giant lumbar hernias, after midline incision, on contralateral side of hernia, dissection was carried out till the edge of psoas muscle. But, on ipsilateral side, we started TAR from midline and stop the dissection when we reach the edge of hernia. Further dissection on the ipsilateral side of hernia was added only after changing patient in lateral decubitus position. After positioning patient in lateral decubitus a lumbar incision was added, the sac was dissected and finally, the retroperitoneal dissection was continued where it was left during supine position. Retroperitoneal space was extended till the lateral border of the psoas muscle. Synthetic polypropylene mesh was placed and fixed. The muscular defect of hernia just anterior to mesh was closed, and at the midline ARS was also approximated with suture. Finally wound was closed. Some of the cases required resection of the bowel and anastomosis, usually when the bowel was found trapped or sutured in the previous repair. We removed the previous mesh on all cases of recurrent hernias.

Assessment of recurrences

Hernia recurrences were evaluated through clinical examination and ventral hernia recurrence inventory (VHRI) questionnaires.¹⁰ All patients were asked about the bulge and physical symptoms/pain at the incision site.

Figure 2 shows surgical technique, figure 2a shows posterior approach where linea alba is held by forceps and retracted and a linear incision is given along the posterior rectus sheath, 2b shows posterior rectus sheath was held by artery forceps and pushed downward while the anterior rectus sheath was held by Allis forceps and retracted upward, 2c shows entry to the space between rectus abdominis muscle and posterior rectus sheath 2d shows a line of musculoaponeurotic transition (dashed line) that was incised releasing the transverse abdominis muscle fiber and entering the pre-peritoneal space, 2e clarifies the anatomy and 2f shows entry to the pre-peritoneal space with excellent medialization of posterior rectus sheath.

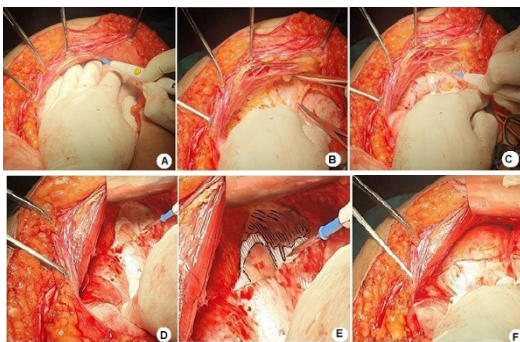


Figure 2: Surgical techniques

Two negative pressure drains were placed on either side which were placed for at least ten days and dressing was done on alternate days, and sutures were removed on the fourteenth post-operative day.

RESULTS

During the period of study, a total of 41 patients underwent an open abdominal wall reconstruction using the TAR technique. Among them, only 34(83%) were included in the study as seven patients failed to report on follow-up. All patients in this study presented with pain and an enlarging hernia interfering with daily activities. The average age of patients was 55 ± 3.85 years ranging from 48 to 61 years. Four patients had wounds at the hernia site, two of them were with mesh infection and sinus while two had pressure ulcers for primary ventral hernia. Demographics and other characteristics of the respondents are presented in table no 1. Table 2 shows the peri-operative details of patients who have undergone TAR.

Table 1: Demographics and other related characteristics of respondents (n=34)

| | | | |
|-----------------------------------|--------------------|-----------------|-----------------|
| Location of hernia | Midline | Above umbilicus | 9 |
| | | Below Umbilicus | 18 |
| Hernia grade | Lateral | | 7 |
| | Grade 1 | | 6 |
| | Grade 2 | | 16 |
| | Grade 3 | | 8 |
| | Grade 4 | | 4 |
| Wound | Clean wound | | 28 |
| | Contaminated wound | | 6 |
| Defect size diameter (cm) | | | 11.64 ± 1.2 |
| Intraoperative duration (minutes) | | | 130 ± 11.9 |
| Average blood loss (ml) | | | 301 ± 133 |
| Button defect of pre-peritoneum | | | 13 |
| Neurovascular injury | | | 1 |
| Injury of linea semilunaris | | | 1 |

Table 2: Peri-operative surgical details of patients who have undergone TAR

| | | |
|--|--|-------------|
| Sex | Male | 8 (23.5%) |
| | Female | 26 (76.47%) |
| BMI (kg/m²) | 23 to 24.9 | 11 |
| | 25 to 29.9 (Pre-Obese) | 6 |
| | 30 to 40 (Obese-I) | 17 |
| Comorbidities | Diabetes Mellitus type 2 | 5 |
| | Hypothyroidism | 6 |
| | Hypertension | 4 |
| | Cholecystectomy-Surgical site infection (SSI) | 2 |
| Prior surgical history or trauma | Nephrectomy-SSI | 2 |
| | Gunshot injury (colostomy) | 1 |
| | Fall injury (trauma) | 1 |
| | Hysterectomy | 2 |
| | Exploratory laparotomy (various causes) | 17 |
| Primary ventral hernia (no previous surgical history) | | 9 |
| Incisional Hernia (non-recurrent) | | 11 |
| Recurrent ventral Hernia | | 14 |
| Past Smoker | | 7 |
| Wound on initial presentation | Ulcer of hernia (due to long-standing disease) | 2 |
| | Mesh infection or sinus tract formation | 2 |

Complete posterior fascial closure was not achieved in four cases. Among which in one patient the peritoneum from hernia sac was tailored to patch fascial defect (figure 3a). In remaining three cases omentum was placed. Free edge of unclosed PRS was sutured to omentum to prevent bowel herniation (figure 3b).

We don't leave button defect unclosed because it risks bowel adhesion with mesh and bowel entrapment (figure 3c). One case had an inadvertent injury of linea semilunaris that was diagnosed at the same time and repaired by Polypropylene suture and finally, TAR plane was re-established (figure 3d). The repaired defect observed was with a mean diameter of 11.64 ± 1.2 cm. The average estimated blood loss was 301 ± 133 ml (minimum 100 ml, maximum 650 ml). The average

duration of surgery was 130 ± 12 minutes ranging from 110 to 150 minutes.

Figure 3 shows techniques to overcome various complications of TAR. 3a shows posterior bridging mesh managed by tailoring peritoneum of hernia sac, 3b shows omentum placement for bridging mesh, 3c shows closure of button defect and 3d shows inadvertent injury of linea semilunaris.

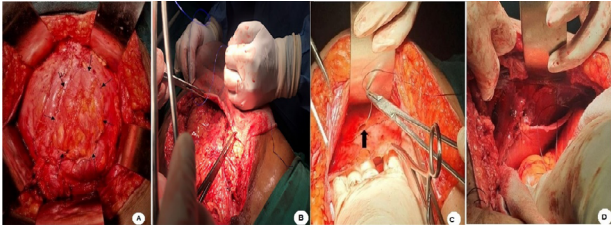


Figure 3: Techniques to overcome various intraoperative complications

Postoperative events

The mean duration of hospital stay within the study group was 11.7 ± 1.3 days ranging from 10 to 14 days. Two cases had surgical site infections during their hospital stay. For both cases twice daily dressing was done in the 1st week with antibiotics based upon culture and sensitivity of the swab from the wound site. Dressing was continued once daily and we used mupirocin and collagen granules for dressing, and as the wound narrowed, skin closure was done. None of the patients required procedural intervention but, it took nearly seven weeks for complete resolution of SSI. Seroma occurred in one of the cases. None of the patients showed clinical signs of symptoms of recurrence in our study after surgery during the follow-up for one year.

DISCUSSION

Complex ventral hernias present surgeons with various challenges for repair, as these hernias have high recurrence rates and wound morbidities. The posterior component separation with TAR as described by Novitsky et al. has recently been identified as the technique of choice for the repair of complex ventral hernias. The technique has been widely accepted for its comparable outcome regarding wound morbidity and recurrence rate.

Novitsky et al. showed a recurrence rate of only 4.7%. In our study out of 34 patients, no recurrences have been yet reported in a one year follow-up period. Punjani et al. published a retrospective review of 100 cases who underwent TAR for complex ventral hernias, they also had no recurrence in a follow-up time of 20.2 months.^{3,5} During the period of study, nearly two cases developed

superficial SSI, and one case presented with a seroma. For one who had recurrent seroma, studies suggests to use multiple aspirations, use of doxycycline, re-operation, and obliteration of pseudocapsule formation around seroma.¹⁴ In our patient, we aspirated multiple times by syringe under aseptic precaution and ultrasound guidance and seroma resolved in four weeks.

Injury of linea semilunaris is said to be the most devastating complication of TAR like permanent laxity of the abdomen due to denervation, spigelian hernia etc.¹¹ We also observed injury in a patient, soon intra operative diagnosis was made and was repaired by suture. The TAR plane was re-established. This patient was aggressively followed up and scrutinized to see any signs of abnormalities of abdominal domain, laxity, and spigelian hernia. But, no such problems were observed, questioning if the injury of linea semilunaris is over-emphasized, or at least if diagnosed and repaired at the time of surgery it may be harmless. As our study is of a short period of one-year follow-up and such intra-operative complication is observed in only one case, drawing a conclusion based on this study is yet difficult.

Vascular injury, one case of recurrent ventral hernia had profuse bleeding due to bleeding from the inferior epigastric vessel just 3 to 4 cm from its origin. The inferior epigastric vessel was isolated and ligated by suture. Postoperatively, there were no features of ischemia or wound complications, probably multiple collateral vessels helped. Though vascular injury is not being described in literature during TAR, but when there is an imbalance of traction and counter traction injury by retractor is possible. So we suggest a balanced retraction.

Fascial medialization or approximation of posterior rectus sheath was able in the majority of cases up to 31(89%). For those in whom fascial medialization was not possible, omentum was placed below the bridging mesh and suture secured to prevent bowel contact. These patients did not show delayed bowel movement suggesting omental placement may be feasible (See figure 3b). Similarly in one of the patients, the fascial gap was patched by peritoneum of hernia sac, tailored to close the defect (figure 3a). We realized this could be another option. A similar problem was encountered by Alkhatib et al. which they managed by placing bio-synthetic composite mesh.¹² Button defect due to peritoneal breach during dissection occurred in 38.2% (n=13), each button defect was closed by vicryl 3-0 and no defects were left without closure as described by Kushner et al.¹³

Two cases had gone resection and anastomosis. Among

them, one case was a recurrent hernia whose previous mesh was sutured with bowel where removal of mesh without resection of bowel was impossible. In the next case of a huge lumbar hernia, though medial fascial closure was possible, but due to suspicion of abdominal compartment syndrome, resection of the bowel was done. Both patients had no surgical site occurrence and they had dramatic outcomes, so remaining in a controlled environment and well handling bowel content, mesh placement is still feasible. During trauma surgery it have shown by many studies that mesh placed in even contaminated field yields a good result and if mesh is infected, it can be managed by local debridement above mesh. Removal of whole infected mesh is overstated.¹⁵

CONCLUSIONS

The use of TAR as a standard technique for repair of a complex ventral hernia could be beneficial to patients as the recurrence is minimum, wound morbidity is low with manageable complications, but, since this study is a single centered, follow-up time of only one year, done among small number of cases, further study using larger sample size and longer follow up are necessary to validate the efficacy in the management of complications of TAR.

ACKNOWLEDGEMENT

We are grateful to all the participants who took part in the study.

CONFLICTS OF INTEREST: None declared

SOURCE OF FUNDING: None

REFERENCES

1. Fink C, Baumann P, Wente MN, Knebel P, Bruckner T, Ulrich A, et al. Incisional hernia rate 3 years after midline laparotomy. *Br J Surg.* 2014;101(2):51-4. DOI: 10.1002/bjs.9560 PMID: 24915797.
2. Helgstrand F, Rosenberg J, Kehlet H, Strandfelt P, Bisgaard T. Reoperation versus clinical recurrence rate after ventral hernia repair. *Ann Surg.* 2012;256(6):955-8. DOI: 10.1097/SLA.0b013e318254f5b9 PMID: 22580941.
3. Punjani R, Arora E, Mankeshwar R, Gala J. An early experience with transversus abdominis release for complex ventral hernias: a retrospective review of 100 cases. *Hernia.* 2021;25(2):353-64. DOI:10.1007/s10029-020-02202-w PMID: 32377962.
4. Wegdam JA, Thoolen JMM, Nienhuijs SW, de Bouvy N, de Vries Reilingh TS. Systematic review of transversus abdominis release in complex abdominal wall reconstruction. *Hernia.* 2019;23(1):5-15. DOI: 10.1007/s10029-018-1870-5 PMID: 30539311.
5. Novitsky YW, Elliott HL, Orenstein SB, Rosen MJ. Transversus abdominis muscle release: a novel approach to posterior component separation during complex abdominal wall reconstruction. *Am J Surg.* 2012;204(5):709-16. DOI: 10.1016/j.amjsurg.2012.02.008 PMID: 22607741.
6. Haskins IN, Prabhu AS, Jensen KK, Tastaldi L, Krpata DM, Perez AJ, et al. Effect of transversus abdominis release on core stability: Short-term results from a single institution. *Surgery.* 2019;165(2):412-6. DOI: 10.1016/j.surg.2018.08.005
7. Sabbagh C, Dumont F, Robert B, Badaoui R, Verhaeghe P, Regimbeau JM. Peritoneal volume is predictive of tension-free fascia closure of large incisional hernias with loss of domain: a prospective study. *Hernia.* 2011;15(5):559-65. DOI: 10.1007/s10029-011-0832-y PMID: 21584816.
8. Gibreel W, Sarr MG, Rosen M, Novitsky Y. Technical considerations in performing posterior component separation with transverse abdominis muscle release. *Hernia.* 2016;20(3):449-59. DOI: 10.1007/s10029-016-1473-y PMID: 26898842.
9. Reinbold W. Transversus abdominis muscle release: Technique, indication, and results. *International Journal of Abdominal Wall and Hernia Surgery.* 2018;1(3):79-86. DOI: 10.4103/ijawhs.ijawhs_27_18
10. Baucom RB, Ousley J, Feurer ID, Beveridge GB, Pierce RA, Holzman MD, et al. Patient reported outcomes after incisional hernia repair establishing the ventral hernia recurrence inventory. *Am J Surg.* 2016;212(1):81-8. DOI: 10.1016/j.amjsurg.2015.06.007 PMID: 26319337.
11. Zolin SJ, Fafaj A, Krpata DM. Transversus abdominis release (TAR): What are the real indications and where is the limit? *Hernia.* 2020;24(2):333-40. DOI: 10.1007/s10029-020-02150-5
12. Alkhatib H, Tastaldi L, Krpata DM, Petro CC, Fafaj A, Rosenblatt S, et al. Outcomes of transversus abdominis release (TAR) with permanent synthetic retromuscular reinforcement for bridged repairs in massive ventral hernias: a retrospective review. *Hernia.* 2020;24(2):341-52. DOI: 10.1007/s10029-019-02046-z PMID: 31549325.
13. Kushner B, Holden S, Blatnik J. Surgical "error traps"

- of open posterior component separation-transversus abdominis release. *Hernia*. 2021;25(6):1703-14. DOI: 10.1007/s10029-020-02321-4 PMID: 33079331.
14. Damiani GR, Lombardi C, Pulerà E, Loizzi V, Villa M, Schonauer LM, et al. Management of abdominal wall recurrent subfascial seroma after pelvic surgery. *Acta Biomed*. 2020;91(4):e2020092. DOI: 10.23750/abm.v91i4.9024 PMID: 33525299.
15. Como J, Gunter O, Diaz J, Ho V, Miller P. Use of posterior component separation and transversus abdominis release in trauma and emergency general surgery patients: A case report and review of the literature. *Trauma Surgery & Acute Care Open*. 2019;4:e000268. DOI:10.1136/tsaco-2018-000268 PMID: 30793037.