



# Clinical Study of Hearing Outcome After Type-I Tympanoplasty Using Temporalis Fascia as Graft

Damodar Kandel<sup>1</sup>, Apar Pokharel<sup>2</sup>, Ramesh Bhandari<sup>1</sup>, Bivek Aryal<sup>1</sup>, Chhanya Bhandari<sup>3</sup>, Bibek Sharma<sup>3</sup>

<sup>1</sup>Department of Otorhinolaryngology & Head and Neck Surgery, Bharatpur Hospital, Bharatpur, Chitwan, Nepal,

<sup>2</sup>Department of Otorhinolaryngology & Head and Neck Surgery, Civil Service Hospital, Kathmandu, Nepal, <sup>3</sup>Department of

Otorhinolaryngology & Head and Neck Surgery, College of Medical Sciences, Bharatpur, Chitwan, Nepal.

## ABSTRACT

### Background

Chronic suppurative otitis media is a longstanding infection of the middle ear cleft characterized by persistent or recurrent aural discharge, deafness and perforation of tympanic membrane. Type I tympanoplasty is a surgical procedure that corrects tympanic membrane perforation.

### Methods

There were a total of 62 patients of age group 11-40 years of Chronic otitis media, mucosal type who underwent type I tympanoplasty in College of Medical Sciences, Bharatpur, Chitwan during a period of one year. Pure tone audiometry of the patients was done before the surgery and one month and three months following surgery and the hearing improvement was assessed in each case.

### Results

In this study, graft uptake was highest (95%) in posterior perforations, 75% in anterior perforations and lowest (63.64%) in combined perforations. The mean hearing improvement one month following surgery was 7.16 dB and three months following surgery, it was 7.78 dB.

### Conclusions

Chronic otitis media is a treatable cause of hearing loss. Type-I tympanoplasty is a safe and effective method to remove the disease of the middle ear and reconstruct the tympanic membrane perforation.

**Keywords:** type I tympanoplasty; tympanic membrane; graft uptake; hearing improvement.

## INTRODUCTION

Chronic suppurative otitis media (CSOM) is a long-standing middle ear infection, characterized by recurrent ear discharge, hearing loss, and tympanic membrane perforation. Small perforations may heal naturally, but larger ones, especially with stratified squamous epithelium around the edges, become permanent. Tympanoplasty, including Type-1, is used to repair these perforations. Type-1 tympanoplasty is performed when there's no ossicular damage, typically involving grafting with temporalis fascia and sometimes combined with mastoidectomy.<sup>1</sup> The size and location of the perforation significantly impact

hearing loss, with larger or posterior perforations causing greater impairment. Chronic discharge can also worsen hearing over time.<sup>2</sup> This study evaluates the hearing outcomes of Type-1 tympanoplasty using temporalis fascia in Chitwan, where CSOM is prevalent. The research aims to assess hearing improvements, identify influencing factors, and compare the results with similar studies. The study is the first of its kind in Chitwan, focusing on functional outcomes of tympanoplasty surgery.

## METHODS

This is a prospective interventional study conducted from 1<sup>st</sup> January 2017 to 31<sup>st</sup> December 2017. The

**Correspondence:** Dr. Damodar Kandel, Department of Otorhinolaryngology & Head and Neck Surgery, Bharatpur Hospital, Bharatpur, Chitwan, Nepal. Email: damsonkandel1@gmail.com, Phone: +977-9855047061. **Article received:** 2024-05-16. **Article accepted:** 2024-11-15. **Article published:** 2024-12-31.

ethical clearance was obtained from the institutional review board. Informed consent was taken from the patient before conducting the study. There was a total of 62 patients of age group 11-40 years. The inclusion criteria were a safe variety of chronic suppurative otitis media with a central perforation dry for at least 3 months with conductive hearing loss and a good cochlear reserve, and healthy middle ear mucosa. The exclusion criteria were all the cases of ASOM, Otosclerosis, Adhesive otitis media, CSOM with mixed or sensorineural hearing loss, congenital hearing disorder, cholesteatoma, intracranial and intratemporal complications of CSOM, chronic otitis externa, and, patients with systemic illness. After taking relevant history and doing clinical examination and investigation, diagnosis was made. Hearing was assessed with pure tone audiometry preoperatively, written consent was taken and considered for Type 1 Tympanoplasty through post aural approach using autologous temporalis fascia graft by underlay technique under general anesthesia. Pure tone audiometry was done to assess hearing during post-operative follow up at 1 month and 3 months. The operation was considered to be successful if patient had intact tympanic membrane at 1 and 3 months follow up periods.

### Surgical Technique

**Steps:** Postaural approach was used to access the tympanic membrane under general anesthesia. Patient was kept in reversed Trendelenburg position on the operating table, with the head supported on rubber ring and rotated to the opposite side. Antiseptic dressing with betadine & draping were done. Post-aural region + 4 quadrants of external auditory canal was infiltrated with 2 % Lignocaine mixed with 1:2 lakh adrenaline.

**Instrumentation:** A suitable sized aural speculum was inserted into the EAC. Microscopic examination was done to confirm findings. Margin of the tympanic membrane perforation was freshened with straight needle and removed with cupped forceps. Chorda tympani was identified and preserved. Handle of malleus was skeletonized. Medial surface of tympanic

membrane remnant was made raw with circular knife avoiding injury to Eustachian tube orifice. Temporalis fascia graft was harvested and kept for drying.

**Underlay Myringoplasty:** An incision was made in posterior canal skin with a round knife extending from 12 o'clock position superiorly to 6 o'clock position inferiorly, bleeding was controlled by a Rosen suction tube. Posterior canal skin was reflected forwards with blunt angled elevator, the skin flap was reflected forwards until the fibrous annulus was identified. The fibrous annulus was elevated from the bony sulcus and mesotympanum was exposed. Graft was placed carefully under the handle of malleus & tympanic membrane remnant, tympanomeatal flap was replaced and external auditory canal was packed with gel foam pieces followed by antibiotic soaked ribbon gauze. Facial nerve function was tested clinically.

### Postoperative Care

Postoperative management was continued with systemic IV antibiotic (ceftriaxone 1 gram IV-BD), Intranasal steroid spray, Antihistamine (fexofenadine 120 mg, PO, HS), PPI (Pantoprazole 40 mg IV OD) and analgesic. Dressing was done on day 1, 3, 5 and 7 over incised area and discharged on day 7 with oral antibiotics.

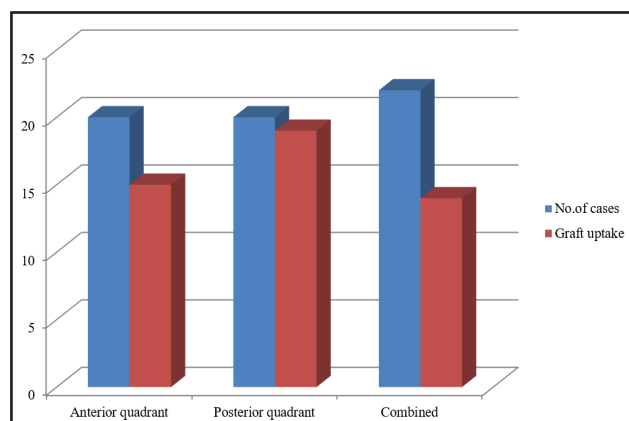
After hospital discharge, the patients were reviewed in the OPD at 1 week, 1 month and 3 months. During these visits, assessment was done by otoscopic examination and PTA was done at 1 month and 3 months.

## RESULTS

In this study, among the total of 62 cases, minimum age was 11 years, maximum 40 years, and the maximum number of cases were in the age group 21-30. Mean age was 26.61 years (Table 1).

Variables	Frequency (%)
<b>Age (years)</b>	
11-20	16(25.80)
21-30	27(43.54)
31-40	19(30.64)
<b>Sex</b>	
Female	28(45.16)
Male	34(54.84)

Among the patients (n=62) who underwent type I tympanoplasty in our hospital, female were 28 (45.16 %) and male were 34 (54.84 %) (Figure 1).



**Figure 1. Site of perforation and graft uptake.**

In our study, anterior perforation cases were 20(32.25%), posterior 20(32.25%) and combined 22(35.48%). Graft uptake was 95% (19 out of 20) in case of posterior perforation, while it was 75% (15 out of 20) in case of anterior perforations, and 63.64% (14 out of 22) in case of combined perforations.

#### **Hearing Improvement One Month after Surgery:**

The mean hearing loss in the pre-operative period was 41.05 dB conductive hearing loss. One month after surgery, the mean hearing loss was 33.89. *t* test was done, the two-tailed *p*-value was 0.0002, the difference was considered to be extremely statistically significant (Table 2).

**Table 2. Summary statistics of hearing improvement one and three months after surgery.**

Parameters	Pre-operative hearing loss	One month post-operative hearing loss	Three months post-operative hearing loss
Mean	41.047	33.887	33.269
SD	11.177	9.385	9.681
Standard error of mean	1.42	1.192	1.229

#### **Hearing Improvement Three months after Surgery:**

Three months after surgery, the mean hearing loss was 33.27 dB conductive hearing loss. The *p*-value was less than 0.0001. The difference was considered to be extremely statistically significant.

## **DISCUSSION**

In our study, the mean age of the cases was 26.61 years with maximum number of the patients in the age group 21-30. In a study by Adkins and White, the age of the patients ranged from 4 to 67 years with the mean age of 25 years.<sup>3</sup> In a similar study by Sarker et al., the mean age (n=60) was 30 years and the majority of the cases fell under age group 26-35.<sup>4</sup> In our study, anterior perforation cases were 20 (32.25%), posterior 20(32.25%) and combined 22(35.48%). Study by Sarker et al. showed most of the patients(61.67%) had central malleolar perforations, 28.33% had posterior central and 10% had anterior central perforations.<sup>4</sup> In our study, anterior perforations were large, while posterior were medium sized. Graft uptake was 95% (19 out of 20) in case of posterior perforation, while it was 75% (15 out of 20) in case of anterior perforations, and 63.64% (14 out of 22) in case of combined perforations. Study by Alzoubi et al. showed success rate of 100 % in medium sized perforations, while 64.7% in large and 78% in total perforations.<sup>5</sup> Our study showed that the mean hearing improvements one month and three months following surgery were 7.16 dB and 7.78 dB respectively. Kouchi et al. found that the ABG decreased from  $28.1 \pm 10.1$  dB to  $11.8 \pm 8.9$  dB in the temporalis fascia graft group. In 87.5% of the patients, the gap was less than 20 dB after surgery.<sup>6</sup> The success rate in various studies ranges from 80 to 95 %.<sup>7</sup> Pelva reported 97 % success of tympanic membrane repair and air-bone gap of <20 dB in 69 % of the cases undergoing type-1 tympanoplasty.<sup>8</sup> Many studies have concluded that hearing outcome after cartilage tympanoplasty are comparable to those after type I tympanoplasty using temporalis fascia.<sup>9</sup> However, in some studies, results of cartilage tympanoplasty were not good.<sup>10</sup>

## **CONCLUSIONS**

Chronic otitis media is a treatable cause of hearing loss. Type I tympanoplasty is a safe and effective method to remove the disease of the middle ear and reconstruct the tympanic membrane perforation.

**Conflict of interest:** None

**Funding:** None

## REFERENCES

1. Batni G, Goyal R. Hearing outcome after type I tympanoplasty: a retrospective study. *Indian J Otolaryngol Head Neck Surg.* 2015;67(1):39–42. [[PubMed](#)]
2. Vaidya S, Sharma JK, Singh G. Study of outcome of tympanoplasties in relation to size and site of tympanic membrane perforation. *Indian J Otolaryngol Head Neck Surg.* 2014;66(3):341–346. [[PubMed](#)]
3. Adkins WY, White B. Type I tympanoplasty: influencing factors. *The Laryngoscope.* 1984;94(7):916–8. [[PubMed](#)]
4. Sarker MZ, Ahmed M, Patwary K, Islam R, Joarder AH. Factors affecting surgical outcome of myringoplasty. *Bangladesh J Otorhinolaryngol.* 1970;17(2):82–7. [[Link](#)] [[DOI](#)]
5. Alzoubi FQ, Tarifi AA, Khader Y, de Carpentier J. Comparison between transtympanic and elevation of tympanomeatal flap approaches in tympanoplasty. *Otol Neurotol.* 2010; 31(5):773–5. [[PubMed](#)]
6. Kouhi A, Khorsandi Ashtiani MT, Jalali MM. Results of type I tympanoplasty using fascia with or without cartilage reinforcement: 10 years' experience. *Iran J Otorhinolaryngol.* 2018; 30(97):103–6. [[PubMed](#)]
7. Fadl FA. Outcome of type-I tympanoplasty. *Saudi Med J.* 2003;24(1):58–61. [[PubMed](#)]
8. Palva T. Myringoplasty and tympanoplasty. *Acta Otolaryngol.* 1987;104:279–284. doi: 10.3109/00016488709107329. [[PubMed](#)]
9. Gerber, Dornhoffer et al (2000) Hearing results after primary cartilage tympanoplasty. *Laryngoscope* 111(12):1994–1999. [[PubMed](#)]
10. Effat KG. Results of inlay cartilage myringoplasty in terms of closure of central tympanic membrane perforations. *J Laryngol Otol.* 2005;119(8):611–613. [[PubMed](#)]

**Citation:** Kandel D, Bhandari R, Aryal B, Pokharel A, Bhandari C, Sharma B. Clinical Study of Hearing Outcome after Type-I Tympanoplasty Using Temporalis Fascia as Graft. *JCMS Nepal.* 2024; 20(4): 364-67.