

## Outcome of Immobilization in External Rotation Position after Closed Reduction in Traumatic Anterior Shoulder Dislocation

Suraj Bidary<sup>1</sup>, Roshani Aryal<sup>2</sup>, Prabal KC<sup>2</sup>, Kushal Bhattarai<sup>3</sup>, Hemant Gupta<sup>1</sup>, Suresh Pandey<sup>1</sup>

<sup>1</sup>Department of Orthopaedic, College of Medical Sciences and Teaching Hospital, Bharatpur, Chitwan, Nepal,

<sup>2</sup>Department of Orthopaedic, Kathmandu Medical College and Teaching Hospital, Kathmandu, Nepal, <sup>3</sup>Department of Biochemistry, College of Medical Sciences and Teaching Hospital, Bharatpur, Chitwan Nepal.

### ABSTRACT

**Background:** As documented in many studies, anterior shoulder dislocation can be effectively immobilized in both external and internal rotation positions, with favorable outcomes. However, controversy exists about the superiority of the technique of immobilization to achieve the reduced rate of re-dislocation. We conducted this study to assess the functional outcome of immobilization of shoulder in external rotation position after relocation in patients with acute anterior shoulder dislocation.

**Methods:** This is hospital based prospective study in total of 36 patients of primary anterior dislocation of shoulder. They were managed with closed reduction and immobilization in external rotation position and followed up for up to twelve months. Functional outcome (including re-dislocation rate) during each follow-up visit was assessed by using ROWE Score.

**Results:** The mean age of the participants was 29.6±7.9 years (range: 17-44 years). Of them, 89.9% were male; and 55.6% were involved in risky jobs. Similarly, 50% of them sustained injury due to slip and fall, 72.2% presented to the hospital within 12 hours; and 69.4% had their right side involved. All the patients were compliant with treatment regime; 77.8% tolerated the brace well and the redislocation rate was 8.3%. ROWE score was found to be significantly increased between subsequent follow-up visits ( $p < 0.05$ ), except between six months and 12 months ( $p > 0.05$ ). Overall, ROWE score varied significantly across the total follow-up period ( $p < 0.05$ ).

**Conclusions:** Immobilization in external rotation position in traumatic anterior shoulder dislocation is a simple and easy method of conservative treatment with good patient compliance, less incidence of re-dislocation and good functional outcome.

**Keywords:** anterior shoulder dislocation; brace compliance; external rotation; ROWE score.

### INTRODUCTION

Shoulder joint is one of the most frequently dislocated large joints in the human body<sup>1</sup> with an overall incidence of 1.7% in the general population.<sup>2,3</sup> Anterior shoulder dislocation is the most frequent type of joint dislocation accounting for more than 95 percent of cases.<sup>4</sup> It affects all age groups being common in young adults and rare after 45 years.<sup>5,6</sup> The mechanism of injury for anterior shoulder dislocation includes abduction, extension, and external rotation of the upper arm.<sup>7</sup> Rarely it may be due to a direct blow.<sup>8</sup> Athletic injuries are more common in younger patients,<sup>9,10</sup> and fall injuries are typical in older patients.<sup>11</sup>

Such type of dislocation can be immobilized after relocation, in either internal or external rotation position. Although immobilization in internal rotation is a common practice,<sup>12,13</sup> recently many studies affirm the benefits of external rotation in terms of functional outcome. In one of such studies, Itoi et al challenged the traditional position of immobilization and demonstrated that the anterior shoulder dislocation after reduction, if

immobilized in external rotation leads to decreased rate of recurrence.<sup>14</sup>

The objective of our study was to assess the functional outcome of immobilization of shoulder (in terms of ROWE score) in external rotation position after relocation in patients with acute anterior shoulder dislocation. Additionally, we aimed to compare this score across the different follow-up visits. ROWE score encompasses the quantification of stability, range of motion and functional limitation of the affected joint and we anticipated increased values of this score over the different follow-up visits.

### METHODS

It was a hospital based cross-sectional study conducted at the department of Orthopaedic Surgery, Kathmandu Medical College and Teaching Hospital (KMCTH), Kathmandu, Nepal, for a period of one and a half year (July 2014 to Jan 2016). Ethical clearance was obtained from the Institutional Review Committee of

**Correspondence:** Dr. Suraj Bidary, Department of Orthopaedic Surgery, College of Medical Sciences and Teaching Hospital Bharatpur, Chitwan, Nepal. **E-mail:** bidary.suraj@gmail.com. **Phone:** +977-9851208022.

**Article received:** 2020-1-27. **Article accepted:** 2020-07-18.

KMCTH. The study population comprised of the patients who presented with traumatic shoulder dislocation to the hospital. Census type of sampling method was employed, wherein, the total patients visiting the hospital with the condition during the six-month period (from July-December, 2014) were considered for the study. Of these, 36 patients who fulfilled the inclusion criteria were selected. After obtaining written informed consent, adolescents and adult patients (17–45 years old) of both gender groups (male/female) who presented with the traumatic anterior shoulder dislocation for the first time were included. Patients were excluded if they had any history of recurrent dislocation and surgery around the shoulder. Similarly, patients with multiple trauma and associated fractures around the shoulder were also excluded.

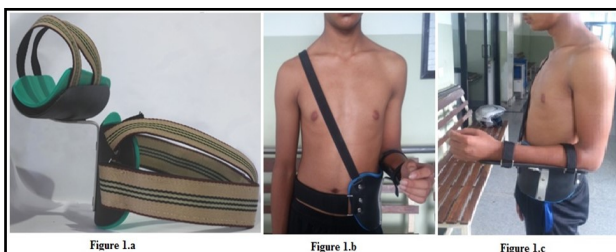
Patients who attended Emergency or Orthopaedic outpatient department of KMCTH with the history of trauma to the shoulder joint followed by pain and inability to move the joint were evaluated clinically and radiographically for dislocation. Proforma was filled up with the identification of the patients including address, telephone number. Detailed history was taken, noting down the socio-demographic profile (gender, geographic residence of the patients, occupation and participation in outdoor activities). Next, mode of injury, time of presentation after the injury and the side involved (right/left) were also recorded. On local examination, the clinical signs, distal neurovascular status, soft tissue injury and other associated injuries were assessed. Radiological investigation was performed to confirm the dislocation and any associated fracture. Radiographs of the shoulder in antero-posterior and lateral views were taken.

Next, reduction was performed after explaining the procedure to the patient and subsequently, brace was applied. For the reduction of dislocation, an intra-articular injection of xylocaine was given taking strict aseptic precautions. The patient was asked to relax in the supine position for about 5 minutes and closed reduction was performed. Reduction was checked clinically with normal shoulder contour, feeling the head rotating in the glenoid during passive range of motion, decrease in pain and tenderness. After clinical confirmation, external rotation brace was applied, check x-ray was taken and neurovascular status was reevaluated before discharge and all findings were recorded. Immobilization was done in 10 degree of external rotation position for three weeks with the help of an external rotation brace. Patients received analgesics as and when required.

The external rotation brace was developed locally for each patient by a certified Orthotist. The

materials used for fabrication of brace are: High Density Polyethylene (HDPE) for pelvic rest and forearm plate; Ethyl Vinyl Acetate (EVA) foam for soft inner lining of brace, Aluminum for positional bar and cotton straps for suspension. It has curved part which fits to the trunk and straight part with the angulation of 10 degrees which fits to the forearm. To ensure the proper position of the brace and to prevent internal rotation, the distance from the umbilicus to the tip of the brace was measured. The distance between the umbilicus to the tip of brace was marked in the string by making a knot. Patient was instructed to measure the distance daily to maintain the shoulder in same position. Increase in length (brace tip to umbilicus) than previous record will indicate external rotation and decrease in length than previous indicates internal rotation of brace.

All patients were given instructions and the dates



**Figure 1. External rotation brace (1.a) and its application in a study patient (1.b and 1.c)**

for follow-up. They were instructed to keep the brace in the same position as far as possible, not to rest or sleep on the affected side for 3 weeks. This was followed by brace removal and subsequent physiotherapy. The total follow-up duration was 12 months, with the regular follow-ups being scheduled at 3 weeks, 6 weeks, 3 months, 6 months and 12 months from the time of initial shoulder reduction.

During each follow-up, patients were assessed for various parameters and ROWE scores were calculated from them.<sup>15</sup> These parameters included stability (recurrence/redislocation, subluxation, apprehension) of the shoulder, range of motion (external rotation, internal rotation and elevation), and functional limitation. Different sub-scores were given for each parameter, and these were totaled to get the ROWE score.

### Statistical analysis

Data was initially entered and cleaned in Microsoft Excel 2007. Further, data was analyzed using Statistical Package for Social Sciences (SPSS), version 16 software. The various categorical variables were described and presented as frequency and percentage and depicted in suitable tables. Continuous variable (ROWE score) was presented as mean with standard deviation and median with interquartile interval (first

quartile-third quartile). As the distribution of ROWE score was significantly deviated from normal, non-parametric tests were used to compare the ROWE score across the overall follow-up period (Wilcoxon Signed Ranks Test) and between the subsequent follow-up periods (Friedman Test). Statistical significance was set at p-value less than 0.05 (p<0.05).

**RESULTS**

Total 44 patients were included in the study initially. Of them, six were cases of recurrent dislocation and two were cases of shoulder dislocation with fracture of greater tuberosity of the humerus. Out of two fracture dislocation cases, one patient also had brachial plexus injury. So, total eight cases were excluded from the study. After exclusion, 36 patients remained in the study.

The participants had the mean age of 29.6 years (SD: 7.9 years), and ranged from 17-44 years. Demographic parameters of the patients have been presented in the table 1 below. Regarding the occupation, 55.6% (n=20) were involved in jobs with considerable risk for injury and included students, farmers and manual laborers. Almost half (52.8%) of the patients did not participate in any outdoor activities/sports, whereas the remaining used to do so occasionally (Table 1).

**Table 1. Socio-demographic profile of the study participants with shoulder dislocation.**

Variables	Frequency (N)	Percentage (%)
<b>Gender</b>		
Female	04	11.1%
Male	32	88.9%
<b>Geographic Location</b>		
Inside Kathmandu	24	66.7%
Outside Kathmandu	12	33.3%
<b>Occupation (Risk Involvement)</b>		
No/Minimal Risk	16	44.4%
Considerable Risk	20	55.6%
<b>Participation in Outdoor Activities</b>		
No	19	52.8%
Yes (occasional)	17	47.2%

Out of the total patients, 50% (n=18) sustained injury due to slip and fall, including fall from height. The others sustained injury due to road traffic accidents (RTA), recreational activities and physical assault. After the injury, 72.2% (n=26) presented to the hospital within 12 hours. On examination, it was found that right side was involved in 69.4% (n=25) of the patients. All 36 patients were compliant with the treatment regime. They used immobilizer on a full time basis except when taking a bath for three weeks. Most of them (77.8%, n=28) tolerated the brace well; remaining patients (22.2%, n=8) tolerated the brace with some discomfort. During the course of treatment, stiffness of the involved shoulder was observed in 8.3% (n=3) of the patients, which resolved with two

months of physiotherapy. None of the patient had subluxation/re-dislocation till six-month follow-up while three patients (8.3%) had re-dislocation and two patients (5.6%) had subluxation between the periods of 7-10 months. The ages of the patients with re-dislocation were 25, 27 and 28 years respectively and the ages of the patients with subluxation were 26 and 33 years respectively (Table 2).

**Table 2. Clinical profile of the study participants with shoulder dislocation.**

Variables	Frequency (N)	Percentage (%)
<b>Mode of Injury</b>		
Slip and Fall	18	50.0%
RTA and others	18	50.0%
<b>Time of presentation</b>		
Within 12 hours	26	72.2%
After 12 hours	10	27.8%
<b>Side Involved</b>		
Right	25	69.4%
Left	11	30.6%
<b>Brace Tolerance</b>		
Well Tolerated	28	77.8%
Tolerated with discomfort	08	22.2%

Table 3 illustrates the variation in ROWE scores of the patients during different time periods of follow-up. As shown, median ROWE score gradually increased from third-week follow-up till 12-months follow-up. However, the mean score increased from three-weeks to six months follow-up, slightly decreasing at 12 months follow-up.

**Table 3. ROWE scores of the study participants during different time periods of follow-up.**

ROWE Score	Mean	SD	Median	Interquartile Range (Q <sub>1</sub> – Q <sub>3</sub> )
3 Weeks	54.9	10.5	60.0	45.0–65.0
6 Weeks	70.4	13.1	75.0	61.3–80.0
3 Months	84.0	11.0	90.0	75.0–95.0
6 Months	87.6	9.8	90.0	75.0–95.0
12 Months	84.6	26.1	95.0	91.3–95.0

Table 4 compares the ROWE score between different follow-up periods. As the distribution of the ROWE scores were significantly deviated from the normal distribution, we used non-parametric tests to compare the score between subsequent follow-up periods and during the overall follow-up for one year. Wilcoxon Signed Ranks test result

**Table 4. Comparison of ROWE score between different follow-up periods.**

Comparison of ROWE Scores	Wilcoxon Signed Ranks Test		Friedman Test
	Z-Score	Significance(p)	
3 Weeks vs. 6 Weeks	5.277	<0.001	Chi Square = 102.416 df= 4 Significance (p)<0.001
6 Weeks vs. 3 Months	4.684	<0.001	
3 Months vs. 6 Months	3.482	<0.001	
6 Months vs. 12 Months	0.820	0.412	

showed the ROWE score to be significantly increased between subsequent follow-ups ( $p < 0.001$ ), except between six months and 12 months, where there was no statistically significant increase in the score ( $p > 0.05$ ). However, the overall comparison of the ROWE score variation using Friedman test showed statistically significant result ( $p < 0.001$ ).

## **DISCUSSION**

The shoulder is the most common joint to dislocate in the human body.<sup>16</sup> The recurrence rate after an initial dislocation ranges between 20% and 48%.<sup>17-20</sup> The aim of treatment for primary dislocation of the shoulder is to prevent subsequent recurrent dislocation. The traditional method of management is by immobilization in internal rotation.<sup>21</sup> Although, this method has been shown to be ineffective in lowering the incidence of recurrent dislocation,<sup>11,22</sup> still it is widely used.<sup>21</sup> However, in the recent years, immobilization in external rotation has been studied by several authors.<sup>14,23,24</sup> Seybold et al. performed a study to evaluate the effect of the external rotation position of the shoulder on different types of labroligamentous lesions in patients with first-time traumatic anterior shoulder dislocation by using MRI and they concluded that placing the shoulder in external rotation significantly improves the position of the labro-ligamentous lesion on the glenoid rim.<sup>24</sup>

Further in this regard, findings of some studies suggest external rotation to be superior to the internal rotation. Itoi et al. used MRI to assess the position of the labral tear after dislocation of the shoulder and concluded that displacement of the labrum from the anatomical position is less when the shoulder is in external rotation and greater when in internal rotation.<sup>25</sup> In a subsequent randomized prospective study, they recorded a lower recurrence of dislocation in patients treated by external rotation bracing compared with those managed in internal rotation.<sup>26</sup> Liavaag et al. compared the position of the labrum in patients treated with immobilization in external rotation or internal rotation and they found that immobilization in external rotation resulted in improved coaptation of the labrum to the glenoid after primary traumatic shoulder dislocation.<sup>23</sup> In view of above literature review, the design of our study was prompted by the prospects of possible benefits of the external rotation.

We included patients with traumatic anterior shoulder dislocation. These patients were then treated with closed reduction followed by immobilization in external rotation position and followed over different time intervals for one year (3 weeks, 6 weeks, 3 months, 6 months and 12 months).

Majority of the patients in our study were male (88.9%,  $n=32$ ). This preponderance of male population is in concordance with the study by Itoi et al<sup>14</sup> (68.8%) and Liavaag et al<sup>23</sup> (74.5%). The higher prevalence of shoulder dislocation in male patients could be attributed to the level of activities such as participation in sports and outdoor activities, thereby making them more susceptible to injury of the shoulder. Other modes of injury like RTA, physical assault and fall from height are more common in male patients compared to female. The similar lifestyle in males contributing to increased risk of shoulder dislocation was also suggested by Robinson et al.<sup>27</sup> Most of the patients (66.7%) were from inside Kathmandu valley, and had relatively easier access to the hospital within the same geographical location.

In our study, 55.6% ( $n=20$ ) were involved in jobs with considerable risk for injury and included students, farmers and manual laborers. Students, being young and active, are involved in various risky activities and sustain injury due to variety of mechanisms like slip and fall, recreational activities, RTA, fall from height, etc. Street et al<sup>28</sup> and Lenaway et al<sup>29</sup>, in separate studies, reported the higher likelihood of shoulder dislocation in the students, mainly as a result of sports injuries. More than half of the patients (52.8%) were not involved in any sports/outdoor activities while the remaining patients (47.2%) in this study were occasionally involved in sports/outdoor activities, which is in contrast to the results of Zacchilli et al<sup>10</sup>, in which sports or recreation related injuries were more common.<sup>10</sup> This could be attributed to the differences in the characteristics (e.g., socio-economic status) between the two populations.

In our study, slip and fall (including fall during walking and fall from height) accounted for the mechanisms of injury in half ( $n=18$ ) of the patients. The other half sustained injury in road traffic accidents, recreational activities and physical assaults. Zacchilli et al<sup>10</sup> reported falls (58.8%) and direct blow (8.9%) as the most common mechanism of injury. However, in their study, approximately half of all dislocations were caused by sports or recreational activities. In developing countries such as ours, people need to climb trees for various occupational reasons and sustain shoulder dislocation due to fall which is not common in developed countries.

A majority (72.2%,  $n=26$ ) of the patients presented within 12 hours of injury. Most of these patients were from inside the Kathmandu Valley and most of the patients who presented after 12 hours of injury were from outside the Kathmandu Valley. In a study by Baykal et al,<sup>30</sup> the mean time of presentation to emergency department after injury



was 61.5 minutes. This is different from the time of presentation in our study. The probable reason for this may be the lack of proper roads and transportation facilities in Nepal, thus presenting a major impediment to accessing adequate health care facilities on time.

Dislocations were more common in the right side (69.4%, n=25) among the patients, which is similar to the study by Itoi et al,<sup>26</sup> where right sided dislocation was present in 60.4% of the cases. All 36 patients were compliant with the treatment regime. They used immobilizer on a full time basis except when taking a bath for three weeks. Most of them (77.8%, n=28) tolerated the brace well; remaining patients (22.2%, n=8) tolerated the brace with some discomfort. In the studies by Itoi et al<sup>14</sup> and Whelan et al<sup>1</sup>, compliance rates in the patients similarly treated as in our study were 72% and 87%, respectively. Likewise, the rate was 100% in the studies by Finestone et al<sup>21</sup> and Huseyin et al,<sup>31</sup> which is similar to our findings. Such a high compliance rate in our study could possibly be attributed to proper counseling and strong motivational effort to ensure compliance with the brace.

Associated with immobilization in external rotation included stiffness of the involved shoulder in 8.3% (n=3) of the patients which resolved with physiotherapy. The finding is similar to the study by Itoi et al,<sup>14</sup> where shoulder stiffness was present in 7% (6 out of 85) of the patients. No other complications like fracture during reduction or neurological impairment after reduction were seen in our study. According to Cunningham, the axillary nerve was the most commonly injured nerve in antero-inferior shoulder dislocation (3%). Other injuries like brachial plexus and other isolated nerve injury can also occur.<sup>32</sup> Perron et al<sup>2</sup> reported neurologic deficit (traction injury to the axillary nerve) in 12.6% (N=190) of patients. Pre-reduction brachial plexus injury was noted in one of the initial cases in our study which was excluded due to associated greater tuberosity fracture. Such a low rate of neurovascular complication in our study was probably due to a small sample size.

Age is an important factor that influences the probability of recurrent dislocations, with recurrence rate of more than 90% reported in patients younger than 20 years old compared with a recurrence rate of about 10% in patients older than 40 years old.<sup>33</sup>

None of the patients in our study had subjective subluxation/re-dislocation till six-months follow-up. However, three patients (8.3%) had re-dislocation and two patients (5.6%) had

subjective subluxation between the periods of 7-10 months. The ages of the patients with re-dislocation were 25, 27 and 28 years respectively and the ages of the patients with subluxation were 26 and 33 years respectively. According to a study by Finestone et al., re-dislocation was 37% (10 out of 27) in mean of 33.4 months follow-up.<sup>21</sup> In a similar study by Whelan et al<sup>1</sup>, re-dislocation was found to be 37% (10 out of 27) in mean of 25 months follow-up. Similar results were reported in a study done by Itoi et al., where re-dislocation was 26% (22 out of 85) in a mean of 25.6 months follow-up.<sup>14</sup> However, in a study by Huseyin et al., re-dislocation was 6.3% (1 out of 16) and in a mean of 20.8 months follow-up.<sup>31</sup> Re-dislocation in our study is comparable with the study by Huseyin et al., but less than findings of Finestone et al<sup>21</sup>, Whelan et al<sup>1</sup> and Itoi et al.<sup>14</sup> The probable reason may be the lesser number of patients under 20 years of age in our study and younger age groups are more likely to have re-dislocation, as suggested by Phillips.<sup>33</sup> Another possible reason may be the shorter total follow-up period in our study (i.e., one-year) which clearly poses the possibility of missing many dislocations which occur after one year. According to Rowe, 70.5% of all recurrent shoulder dislocations occur within the first two years and 18.7% occur from two to five years of initial injury.<sup>6</sup>

Mean ROWE Score gradually increased from third week (54.86) follow-up till six months (87.64) follow-up. At twelve months (84.58) follow-up, mean ROWE Score is slightly less compared to mean ROWE Score at six-month follow-up probably because of re-dislocation in three patients and subjective subluxation in two patients between the periods of 7-10 months. However, these changes in ROWE score probably did not affect the median score which increased from 6 months to 12 months, although the increase was not statistically significant ( $p < 0.05$ ). Moreover, ROWE score increased significantly between each subsequent follow-up visit up to 6 months; and there was significant increase in this score at the end of one year.

Limitations of this study are relatively small sample size and shorter duration of follow up. So, study involving larger sample size and longer duration of follow up is recommended to further validate the results of this study.

## **CONCLUSIONS**

As indicated in the result of our study, immobilization in external rotation position in traumatic anterior shoulder dislocation is a simple and easy method of conservative treatment with good patient compliance, less incidence of re-dislocation and good functional outcome.

**REFERENCES**

1. Whelan DB, Litchfield R, Wambolt E, Dainty KN. External rotation immobilization for primary shoulder dislocation: a randomized controlled trial. *Clin Orthop Relat Res.* 2014;472(8):2380-6.
2. Perron AD, Ingerski MS, Brady WJ, Erling BF, Ullman EA. Acute complications associated with shoulder dislocation at an academic emergency department. *J Emerg Med.* 2003;24(2):141-5.
3. Hovelius L. Incidence of shoulder dislocation in Sweden. *Clin Orthop Relat Res.* 1982;166:127-31.
4. Vavken P, Sadoghi P, Quidde J, Lucas R, Delaney R, Mueller AM, et al. Immobilization in internal or external rotation does not change recurrence rates after traumatic anterior shoulder dislocation. *J Shoulder Elbow Surg.* 2014;23(1):13-9.
5. Turek SL. *Orthopaedics principles and their applications.* 6th ed: Lippincott Williams and Wilkins; 2005. p. 387-94.
6. Rowe CR. Prognosis in Dislocations of the shoulder. *J Bone Jt Surg Am.* 1956;38-A(5):957-77.
7. Beeson MS. Complications of Shoulder Dislocation. *Am J Emerg Med.* 1999;17:288-95.
8. Jawa A, Ricchetti ET. Glenohumeral instability In: Court-Brown CM, Heckman JD, McQueen MM, Ricci WM, Tornetta P, editor. *Rockwood and Green's Fractures in Adults.* 8th ed: Wolters Kluwer; 2015. p. 1503-34.
9. Owens BD, Duffey MI, Nelson BJ, et al. The incidence and characteristics of shoulder instability at the united states Military Academy. *Am J Sport Med.* 2007;35(7):1168-73.
10. Zacchilli MA, Owens BD. Epidemiology of shoulder dislocations presenting to emergency departments in the United States. *J Bone Jt Surg Am.* 2010;92(3):542-9.
11. Henry JH, Genung JA. Natural history of glenohumeral dislocation: revisited. *Am J Sport Med.* 1982;10:135-7.
12. Murrell GAC. Treatment of shoulder dislocation: is a sling appropriate? *Med J Aust.* 2003;179(7):370-1.
13. Momenzadeh OR, Pourmokhtari M, Sefidbakht S, Vosoughi AR. Does the position of shoulder immobilization after reduced anterior glenohumeral dislocation affect coaptation of a bankart lesion? an arthrographic comparison. *Journal of Orthopaedics and Traumatology.* 2015;16(4):317-21.
14. Itoi E, Hatakeyama Y, Sato T, Kido T, Minagawa H, Yamamoto N, et al. Immobilization in external rotation after shoulder dislocation reduces the risk of recurrence: a randomized controlled trial. *J Bone Joint Surg Am.* 2007;89(10):2124-31.
15. Rowe CR, Patel D, Southmayd WW. The Bankart procedure: a long-term end-result study. *J Bone Joint Surg Am.* 1978;60(1):1-16.
16. Kazar B, Relovszky E. Prognosis of primary dislocation of the shoulder. *Acta Orthop Scand.* 1969;40(2):216-24.
17. Simonet WT, Cofield RH. Prognosis in anterior shoulder dislocation. *Am J Sport Med.* 1984;12(1):19-24.
18. Hovelius L, Augustini BG, Fredin H, Johansson O, Norlin R, Thorling J. Primary anterior dislocation of the shoulder in young patients: a ten-year prospective study. *J Bone Joint Surg Am.* 1996;78(11):1667-84.
19. Kralinger FS, Golser K, Wischatta R, Wambacher M, Sperner G. Predicting recurrence after primary anterior shoulder dislocation. *Am J Sport Med.* 2002;30:116-20.
20. Rowe CR, Sakellarides HT. Factors related to recurrences of anterior dislocations of the shoulder. *Clin Orthop.* 1961;20:40-8.
21. Finestone A, Milgrom C, Radeva-Petrova DR, Rath E, Barchilon V, Beyth S, et al. Bracing in external rotation for traumatic anterior dislocation of the shoulder. *J Bone Jt Surg Br.* 2009;91(7):918-21.
22. Hovelius L, Eriksson K, Fredin H, Hagberg G, Husenius A, Lind B, et al. Recurrences after initial dislocation of the shoulder: results of a prospective study of treatment. *J Bone Joint Surg Am.* 1983;65-A:343-9.
23. Liavaag S, Stiris MG, Lindland ES, Enger M, Svenningsen S, Brox JI. Do Bankart lesions heal better in shoulders immobilized in external rotation? A randomized single-blind study of 55 patients examined with MRI. *Acta Orthop.* 2009;80(5):579-84.
24. Seybold D, Schliemann B, Heyer CM, Muhr G, Gekle C. Which labral lesion can be best reduced with external rotation of the shoulder after a first-time traumatic anterior shoulder dislocation? *Arch Orthop Trauma Surg.* 2009;129(3):299-304.
25. Itoi E, Sashi R, Minagawa H, Shimizu T, Wakabayashi I, Sato K. Position of immobilization after dislocation of the glenohumeral joint. A study with use of magnetic resonance imaging. *J Bone Joint Surg Am.* 2001;83-A(5):661-7.
26. Itoi E, Hatakeyama Y, Kido T, Sato T, Minagawa H, Wakabayashi I, et al. A new method of immobilization after traumatic anterior dislocation of the shoulder: a preliminary study. *J Shoulder Elbow Surg.* 2003;12(5):413-5.
27. Robinson CM, Howes J, Murdoch H, Will E, Graham C. Functional outcome and risk of recurrent instability after primary traumatic anterior shoulder dislocation in young patients. *The Journal of bone and joint surgery.* 2006;88-A(11):2326-36.
28. Street EJ, Jacobsen KH. Prevalence of sports injuries among 13 to 15 year old students in 25 low- and middle-income countries. *J Community Health.* 2017;42(2):295-302.
29. Lenaway DD, Ambler AG, Beaudoin DE. The epidemiology of school-related injuries: new perspectives. *Am J Prev Med.* 1992;8(3):193-8.
30. Baykal B, Sener S, Turkan H. Scapular manipulation technique for reduction of traumatic anterior shoulder dislocations: experiences of an emergency department. *Emerg Med J.* 2005;22(5):336-8.
31. Taskoparan H, Tunay S, Kilincoglu V, Bilgic S, Yurttas Y, Komurcu M. Immobilization of the shoulder in external rotation for prevention of recurrence in acute anterior dislocation. *Acta Orthop Traumatol Turc.* 2010;44(4):278-84.
32. Cunningham NJ. Techniques for reduction of anteroinferior shoulder dislocation. *Emerg Med Australasia.* 2005;17:463-71.
33. Phillips BB. Recurrent Dislocations. In: Canale ST, Beaty JH, editor. *Campbell's Operative Orthopaedics.* 12th ed: Elsevier Mosby; 2013. p. 2271-5.

**Citation:** Bidary S, Aryal R, KC P, Bhattarai K, Gupta H, Pandey S. Outcome of Immobilization in External Rotation Position after Closed Reduction in Traumatic Anterior Shoulder Dislocation. *JCMS Nepal.* 2019; 16(3):146-51.