

Patterns of palatal rugae as an indicator of identification in young adults of Nepal

Ashish Shrestha¹, Sushmita Shrestha², Vinay Marla³, Navin Agrawal²

¹Department of Oral Pathology, ²Department of Conservative Dentistry and Endodontics, BP Koirala Institute of Health Sciences, Dharan, Nepal

³Department of Oral Pathology, Dhulikhel Hospital, Kavre, Nepal

Correspondence

Dr. Ashish Shrestha
Associate Professor
Department of Oral Pathology
BP Koirala Institute of Health
Sciences, Dharan, Nepal

Email:

ashish.shrestha@bpkihs.edu

ORCID ID:

<http://orcid.org/0000-0002-1317-0522>

DOI: <http://dx.doi.org/10.3126/jcmsn.v13i2.17711>

Article received: 7th February 2016

Article accepted: 27th June 2017

ABSTRACT

Background & Objectives: The current study was conducted to identify and determine the association between gender and characteristics of palatal rugae in Nepalese population. **Materials & Methods:** Characteristics of palatal rugae including number, length, shape, direction and unification were analyzed in 100 maxillary dental plaster casts. Association between palatal rugae and gender were tested using chi square analysis and statistical descriptors were identified using SPSS 10.0 keeping the level of statistical significance at $p < 0.05$. **Results:** A total of 997 rugae were traced. Females were found to have more rugae than males though statistically not significant. In the present study significant difference in secondary ($p = 0.012$), fragmentary ($p = 0.005$), straight ($p = 0.001$) and perpendicular directed ($p < 0.0001$) palatal rugae were observed, which were higher among females. Forward directed followed by backward were predominantly observed and more among females. Wavy followed by curved, straight and circular rugae was the most prevalent shape. **Conclusion:** No two individual had similar rugae pattern. They can be used to identify people and differentiate between males and females in addition to other tools of identification and has great application in forensic science.

Key words: Forensic science; identification; palatal rugae; rugoscopy

Citation: Shrestha A, Shrestha S, Marla V, Agrawal N. Patterns of palatal rugae as an indicator of identification in young adults of Nepal. *JCMS Nepal*. 2017;13(2):241-5.

INTRODUCTION

Palatal rugae are asymmetrical and irregular elevations of the mucosa. Palatal rugae also called as transverse palatine folds are located in the anterior third of the hard palate. It is made from the lateral membrane of incisive papilla and arranged in transverse direction from palatine raphe located in mid-sagittal plane.¹ It is formed in the third month in-utero from the hard connective tissue covering the bone. The orientation of it is formed around 12th to 14th week of prenatal life and remains stable until the oral mucosa degenerates after death.^{2,3} Physiologically palatal rugae helps in swallowing of food, taste perception, speech and suction in children; and also in the medico-legal identification process.⁴

Teeth have been used as an important tool in both the ante-mortem and post-mortem identification. Post-mortem dental identification at times is not

possible especially in edentulous individuals. The study of palatal rugae; palatoscopy can be used as an alternate method of identification which was first proposed in 1932 by Trobo Hermosa.⁵ The significance of palatal rugae in identification lies with its individuality.⁶ As well stated by Sassouni⁷ that no two palates are identical in their configuration and not alter during growth. Palatal rugae pattern are also found to differentiate racial groups, facilitating in the population identification.⁸⁻¹⁰ Although debated, rugae are considered to be stable throughout the life and have ability of regeneration to the previous size and shape.^{11,12} Palatal rugae have been well established as a reference landmark during forensic identification.² They are well protected by the lips, cheek, tongue, buccal pad of fat and teeth during incidents of fire and high impact trauma.¹² After mass disaster or road traffic accidents when there is difficulty in

identifying a person according to fingerprints or other dental records, rugae pattern may be helpful.^{13,14}

Most of the studies have used various morphological parameters of rugae for personal identification. In Nepalese population few studies are on sexual dimorphism. The present study has been conducted to identify the characteristics of rugae pattern and analyze its association between genders.

MATERIALS AND METHODS

The study was carried out in Department of Oral Pathology, BP Koirala Institute of Health Sciences, Nepal. A total of 100 maxillary casts (50 males & 50 females) belonging to 18 to 23 years were considered. Maxillary casts were retrieved from archives of the department, which were obtained from students of the institution after taking consent. The maxillary casts selected were fully dentate, free of voids and air bubbles and those exhibiting severe malocclusion, history of previous orthodontic treatment and/or palatal asymmetries, trauma were excluded. Ethical clearance was obtained from Institute Ethics Review Board, BP Koirala Institute of Health Sciences.

Method of identification of rugae

The palatal rugae of the casts were traced using a sharp graphite pencil under adequate light and magnification (Figure 1). Number, length, shape, direction and unification of the palatal rugae were recorded based on the classification by Thomas and Kotze¹⁰ and Kapali et al (Figure 2).¹⁵

Based on length

- ◆ Primary: ≥ 5 mm
- ◆ Secondary: 3-5mm
- ◆ Fragmentary: (2-3mm)
- ◆ Rugae less than 2 mm were not considered for any categorization

Based on shape

- ◆ Straight: rugae ran directly from origin to termination
- ◆ Curved: simple crescent shape that curved gently
- ◆ Wavy: serpentine or slightest bend at the termination or origin of curved rugae
- ◆ Circular: rugae with definite continuous ring formation

Based on direction (For primary rugae; based on angle between line joining origin and termination and line perpendicular to mid palatine raphe)

- ◆ Forward: positive angle

- ◆ Backward: negative angle
- ◆ Perpendicular: with zero degree angle

Based on unification (Rugae joined at origin or termination)¹⁵

- ◆ Divergent: two rugae began from same origin but immediately diverge
- ◆ Convergent: rugae with different origin join on lateral portions

The data were recorded in Microsoft Excel 2007 and association between number and shape of rugae with gender was tested applying chi square and statistical analysis were done using SPSS 10.0 for each parameters keeping level of significance at $p < 0.05$.

RESULTS

A total of 997 rugae were traced from 100 study models. Among the study population, the mean age of males was 22.3 ± 0.82 years and 21.5 ± 1.26 years of females. No correlation of rugae patterns to age was elicited. Though not significant more number of palatal rugae was found in females. (Table 1) A significant difference in secondary ($p=0.012$), fragmentary ($p=0.005$), straight ($p=0.001$) and perpendicular directed ($p<0.0001$) palatal rugae were observed, which were higher among females. The predominant direction of primary rugae was forward directed followed by backward. The most prevalent shape was wavy followed by curved, straight and circular; among which wavy and circular was more in males (Table 2).

DISCUSSION

Palatal rugae refers to the ridges on anterior part of palatal mucosa on each side of median palatine raphe.¹⁶ The study of rugae is one of the important tools in identification especially of edentulous individuals when ante- mortem and post-mortem dental records are present.¹² The number of rugae has been found to be unchanged up to the age of

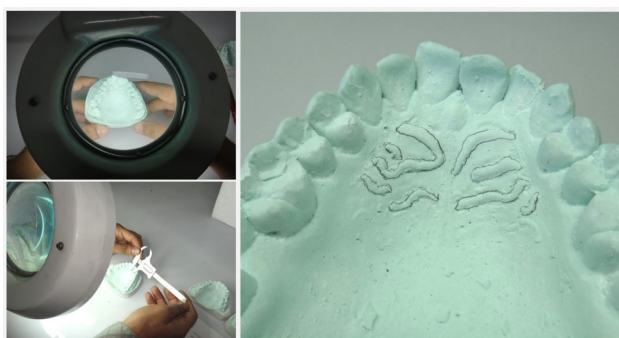

Figure 1: Tracing of palatal rugae

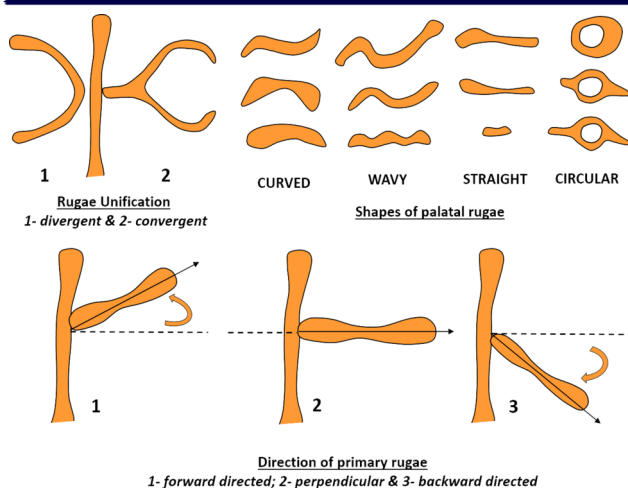


Figure 2: Classification of rugae

twenty three years and then decreases.¹⁷ The length of the rugae changes with age which has been correlated with the underlying growth of the palate.^{17,18} However, the anterior rugae has not found to increase in length after ten years of age, hence highlighting its stability and importance in identification.¹⁹ Limited studies have highlighted the sexual dimorphism in palatal rugae.²⁰ The present study reported differences in secondary, fragmentary, straight and perpendicular directed palatal rugae, which were significantly higher among females.

The numbers of rugae were more in females compared to males, which is in consistency with the study by Gondivkar et al¹ and Kotrashetti et al.²¹ The observations from our study is not in consistent with other wherein females had fewer rugae and more rugae on right.^{9,20,22} In our study primary rugae was most commonly observed however did

not show any significant differences between the genders which is in consistent to the conclusion drawn by Bajracharya et al¹⁰ in Nepalese population, Kapali et al²³ in Austalian Aborigines and Mahabalesh et al²⁴ in Indian population. Furthermore Acharya et al²⁵ from a statistical perspective has showed up to 99.2% in identifying gender on analyzing the shape of the palatal rugae. Wavy pattern was the predominant rugae observed in our study which were similar in Australian aborigines, Nepalese and Egyptian population.^{10,24,26} However the least observed pattern is circular type which is in contrast to the study in Australian aborigines, wherein straight pattern was least observed.¹⁰ Similar observations were also reported in the study on Nepalese and Indian population.^{24,27} The second most common pattern was curved which was in consistent to study by Bajracharya et al²⁴ but in contrast to the findings by Kallianpur et al²⁸ who reported straight type as second predominant pattern in Nepalese population. The predominant direction of the palatal rugae was forward directed compared to backward which were more in females as consistent with the study by Gondivkar et al.¹ Similarly the backward directed pattern were more among females though statistically not significant. Another finding in our study wherein converging pattern was more in females is in concordance with the study by Fahmi et al²⁷ in Saudi population, but contrary to the study in Indian population.²⁹

Even though according to Ohtani et al.,³⁰ three situations complicate identification based on the palatal rugae viz. changes in rugae height, the presence of flat or poorly accentuated ridges, and

Table 1: Frequency distribution of morphological characteristics of rugae

Characteristics	Total N=100	Males		Females	
		No.	%	No.	%
Total number of rugae	997	483	48.45%	514	51.55%
Primary	806	413	51.2%	393	48.8%
Secondary	155	61	39.3%	94	60.7%
Fragmentary	36	9	25.0%	27	75.0%
Straight	243	96	39.25%	147	60.75%
Wavy	427	225	52.69%	202	47.21%
Curved	278	129	46.4%	149	53.6%
Circular	49	34	69.38%	15	30.62%
Forward	475	230	48.4%	245	51.6%
Backward	286	140	48.9%	146	51.1%
Perpendicular	45	8	17.7%	37	82.3%
Converging	21	7	33.33%	14	66.67%
Diverging	17	10	58.83%	7	41.17%

Table 2: Correlation of palatal rugae with gender

SN	Characteristics	Males		Females		p value
		Mean	SD	Mean	SD	
1	Total number of rugae	9.66	1.8	10.2	2.4	0.20
2	Primary	8.26	1.61	7.86	2.06	0.28
3	Secondary	1.22	1.58	1.88	1.63	0.012
4	Fragmentary	0.18	0.62	0.54	0.97	0.005
5	Straight	1.88	1.68	2.94	1.57	0.001
6	Curved	4.44	2.2	4.04	2.28	0.213
7	Wavy	2.64	1.84	2.98	1.70	0.366
8	Circular	0.70	1.18	0.3	0.67	0.06
9	Forward	4.6	1.49	4.9	1.77	0.36
10	Backward	2.80	1.87	2.92	1.4	0.72
11	Perpendicular	0.16	0.37	0.74	0.85	0.0001
12	Convergent	0.14	0.40	0.28	0.49	0.06
13	Divergent	0.20	0.49	0.14	0.40	0.74

the absence of uncomplicated patterns, the percentage accuracy of identification based on the palatal rugae was found to be around 94%.

Palatal rugae are used in identification not only because of their singularity and unchangeable nature, but also due to low utilization costs.^{31,32} Hence if the records are kept properly palatal rugoscopy could be conveniently used, in situation where proper facility for forensic sciences is still evolving and inadequate.

There has been a significant development in the field of rugoscopy and forensic sciences. Digital techniques to compare ante and post-mortem records of rugae have been utilized. Not only limited to two dimensional but also three dimensional evaluations of palatal rugae using digital study models are found to be more useful and specific.³³ Advanced digital technique using Palatal Rugae Comparison Software to match the clinical photographs is used where the accuracy rate of identification is 99%, with a minimal error rate of 2%.³²

Many features of palatal rugae in our study were comparable to the studies done in different population but none of it matched accurately, which could be attributed to the variation in genetic factors. Population differences of rugae patterns have been reported by several comparative studies; which highlights the role of genes and environment in the variation. Previous studies reported that, environmental factors are unlikely to affect formation of rugae. The share of rugae is said to be

genetically controlled. This was supported by studies which have revealed that rugae pattern has an underlying genetic basis.³⁴ Even though some of the morphological character matched; there was variation in one or the other pattern of palatal rugae. Hence rugoscopy can be considered as one of the important tools for identification provided the ante-mortem dental record exists.

CONCLUSION

Palatal rugae are complex and non-identical between any two individuals and are useful only when the dental records are available. Hence, we should encourage keeping a proper dental record in the form of a dental cast or photographing such that it can be used for future reference. Though the study has highlighted the importance of palatal rugae in forensic sciences, the results and interpretation are limited by the sample size and encourages extensive study of palatal rugae among Nepalese population.

ACKNOWLEDGEMENT

We would like to thank Dr. Ashith B Acharya, Department of Forensic Odontology, SDM College of Dental Sciences and Hospital, Dharwad, India for his guidance to conduct this study.

REFERENCES

- Gondivkar SM, Patel S, Gadbaal A R, Gaikwad R N, Chole R PR. Morphological study of the palatal rugae in western Indian population. *J Forensic Leg Med* 2011;18(7):310–2.
- Sandler TW. *Langman's medical Embryology*. Williams and Wilkins, Baltimore; 1990. 316-20 p.

3. Patil MS, Patil SB, Acharya AB. Palatine Rugae and Their Significance in Clinical Dentistry. *J Am Dent Assoc.* 2008;139(11):1471–8.
4. Venegas VH, Valenzuela JS, Lopez MC, Galdames IS. Palatal rugae: Systematic analysis of its shape and dimensions for use in human identification. *Int J Morphol.* 2009;27:819–25.
5. Pueyo VM, Garrido BR, Sanchez JS. *Odontologia legalmente forense*, Masson, Barcelona. 1994;23:277–92.
6. English WR, Robison SF, Summitt JB, Oesterle LJ, Brannon RB, Morlang WM, et al. Individuality of Human Palatal Rugae. *J Forensic Sci.* 1988;33:718–26.
7. Sassouni V. Palatoprint and roentgenographic cephalometry as new method in Human identification. *J Forensic Sci.* 1957;2:428–42.
8. Thomas CJ, Kotze TJ. The palatal ruga pattern in six southern African human populations. Part-II. Inter-racial differences. *J Dent Assoc South Afr.* 1983;38:166–72.
9. Shwetha KS, Shalini K, Karthikeya P, Mahima VG. Palatal rugae pattern in Mysorean and Tibetan. *Indian J Dent Res.* 2005;16:51–2.
10. Kapali S, Townsend G, Richards L, Parish T. Palatal rugae patterns in Australian Aborigines and Caucasians. 1997; (May 1996):129–33.
11. Almeida MA, Phillips C, Kula K, Tulloch C. Stability of the palatal rugae as landmarks. *Angle Orthod.* 1995;65:43–8.
12. Shafer, Hine L. *Shafer's Textbook of Oral Pathology*. 6th ed. Rajendran R SB, editor. Elsevier; 2010. 878-879 p.
13. Carrera JU. Gaumenfalten-fotostenogramme, ein neues identifizierungsverfahren. *Dtsch Zahnärztl Z.* 1955;10:11–7.
14. O'Shaughnessy PE. Introduction to forensic science. *Dent Clin North Am.* 2001;45:217–27.
15. Thomas CJ, Kotze TjvW and Nash JM. Papillarity of the palatal mucosa. 1985;12:491–7.
16. Bhullar A, Kaur RP, Kamat MS. Palatal Rugea – an Aid in Clinical Dentistry. 2011;2(3):2–5.
17. Lysell L. Plicae palatinae transversae and papilla incisiva in man: a morphologic and genetic study. *Acta Odont Scand.* 1955;13:Suppl:1–137.
18. Hauser G, Daponte A, Robertst MJ. Palatal rugae. 1989;237–49.
19. van der Linden FP. Changes in the position of posterior teeth in relation to ruga points. *Am J Orthod.* 1978;74:142–61.
20. Dohke M, Osato S. Morphological study of the palatal rugae in Japanese 1. Bilateral differences in the regressive evaluation of the palatal rugae. *Jap J Oral Biol.* 1994;36:125–40.
21. Kotrashetti VS, Hollikatti K, Mallapur MD, Hallikeremath SR KA. Determination of palatal rugae patterns among two ethnic populations of India by logistic regression analysis. *J Forensic Leg Med.* 2011;18(8):360–5.
22. Sunita K, Grant T, Richards L, Tracey P. Palatal rugae patterns in Australian, Aborigines and Caucasians. *Aus Dent J.* 1997;42:129–33.
23. Mahabalesh S, Premalatha K. Study of Palatal Rugae Pattern among the Student Population in Mangalore. *J Indian Acad Forensic Med.* 2011;33:112–5.
24. Bajracharya D, Vaidya A, Thapa S, Shrestha S. Palatal Rugae Pattern in Nepalese Subjects. *Orthod J Nepal.* 2013;3(2):36–9.
25. Acharya AB, Prabhu S. Odontometric sex assessment from logistic regression analysis. 2011;199–204.
26. Azab SMS, Magdy R, Deen MAS EL. Patterns of palatal rugae among adult Egyptian population. *Egypt J Forensic Sci.* 2015;6(2).
27. Jibi PM, Gautam KK, Basappa N, and Raju OS. Morphological Pattern of Palatal Rugae in Children of Davangere. *J Forensic Sci*, Sept. 2011;56:1192–7.
28. Kallianpur S, Desai A, Kasetty S, Sudheendra U JP. An anthropometric analysis of facial height, arch length, and palatal rugae in the Indian and Nepalese population. *J Forensic Dent Sci.* 2011;3:33–7.
29. Fahmi FM, Al-Shamran SM, Talic YF. Rugae pattern in Saudi population sample of males and females. *Saudi Dent J.* 2001;30:92–5.
30. Ohtani M, Nishida N, Chiba T, Fukuda M, Miyamoto Y, Yoshioka N. Indication and limitations of using palatal rugae for personal identification in edentulous cases. *Forensic Sci Int.* 2008;176:178–82.
31. Thomas CJ, van Wyk CW. The palatal rugae in identification. *J Forensic Odontostomatol.* 1988;6:21–5.
32. Hemanth M, Vidya M, Shetty N, and Karkera BV. Identification of individuals using palatal rugae: Computerized method. *J Forensic Dent Sci.* 2010;2(2):86–90.
33. Taneva ED, Johnson A, Viana G, Evans CA. 3D evaluation of palatal rugae for human identification using digital study models. *J Forensic Dent Sci.* 2015;7(3):244–252.
34. Gaurav A. *Cheiloscopy and palatoscopy*. N. Jain (Ed.), Textbook of forensic odontology. Jaypee Brothers Medical Publishers, Panama, India; 2013. 167 p.