

CASE REPORT

VAGINAL EXTRUSION OF HUGE DECIDUAL CAST: AN EXCEPTIONAL CASE REPORT

Apariharya Rana¹, Manisha Bhardwaj², Sarmila Prajapati³, Ashma Rana^{4*}

¹Medical Officer

²Department of Obstetrics and Gynecology, Provincial Hospital Janakpur

³House officer, Paropakar Maternity and Women's Hospital, Thapathali, Kathmandu, Nepal

⁴Consultant Gynecologist, Kathmandu, Nepal

Received: 11 Aug, 2021

Accepted: 12 Sep, 2021

Published: 30 Sep, 2021

Key words: Decidual cast; Membranous dysmenorrhea; Norethisterone.

***Correspondence to:** Ashma Rana, Consultant Gynecologist, Kathmandu, Nepal.
Email: ashmarana2011@gmail.com

Citation

Rana A, Bhardwaj M, Prajapati S, Rana A. Vaginal extrusion of huge decidual cast: an exceptional case report. Journal of Chitwan Medical College. 2021;11(37):145-7.



Peer Reviewed

ABSTRACT

Infrequent, irregularly irregular delayed menstrual period accompanied by heavy bleeding prolonged for weeks to months was treated with oral norethisterone 5mg tablet in 5mg – 30mg daily divided dose resulted in painful vaginal extrusion of huge fleshy mass (10 x 7 x 5 cm) retaining the shape uterus histopathologically confirmed as decidual cast, a rare, as well as incomparable case, is described in an unmarried nulligravida in late twenty's to alert the association of progesterone to membranous dysmenorrhea.

Everyone under the hormonal treatment for menstrual disorders must be educated and made aware of the underlying dreadful possibility of painful vaginal expulsion of decidual cast ascribed to membranous dysmenorrhea to cope or overcome the fright.

INTRODUCTION

Menarche may be the beginning of distress for many pubertal girls, either in form of menorrhagia or disordered menstruation coming infrequently at the longer intervals with scanty to heavy flow. This in due course of time eventually gets corrected with the hypothalamic maturity and the occurrence of the ovulatory menstrual cycle, promising good fertility in reproductive life. Unfortunately, the same is not true for all. Described herewith is one, who suffered right from the onset of menstruation and underwent treatment with periodic oral progesterone for a long duration that ultimately resulted in painful vaginal expulsion of a huge decidual cast of membranous dysmenorrhea, signifying controlled use of progesterone.

CASE REPORT

A 29 years well-educated professional lady unmarried, nulligravida in single status, to begin with, the onset of menses at the age of 13. Subsequent menstrual periods were irregularly irregular occurring every three to six months or at times delayed as long as to one year, with the bleeding pattern varying from spotting to scanty flow. After a decade of

menarche, the pattern of the menstrual cycle (MC) remaining infrequent as always was accompanied by the painless heavy menstrual flow. Pooling of blood or flooding was experienced even a slight movement. Bleeding used to continue for months at times. For this, she consulted a Gynecologists, for the first time in 2016 Sept 20, when she was 25 years of age. On examination, weight was 58 kg, looked pale hemoglobin 8.7 gm % and Blood Pressure (BP) of 120/60 mm of Hg. Coagulation profile and thyroid function tests were normal. Transabdominal USG showed normal uterus 10.4x4.6 x 5.4 with endometrial thickness of 24mm. The dose eventually was increased up to 2 tabs thrice a day in between in order to stop the profuse bleeding and correct anemia (Hb 6 gm %). Two units of B positive blood were transfused during the period of hospitalization in a private hospital from 21-26 January 2020. Further evaluation by the USG abdomen showed uterine enlargement (118x76x93 mm) with an endometrial thickness of 42 mm. Digital Pelvic examination was not indicated so not done. Her coagulation profile and thyroid parameters were within normal limits but Hb always clinically remained moderately anemic (<10 gm percent). She also had issues with acne vulgaris. Several abdominal USG was repeatedly done in different time periods which reported bulky uterus with varying measurements of

endometrial thickness without any feature of polycystic ovary syndrome (PCOS). She was advised of Dilatation and Curettage (D&C) for the investigation but she denied it. Norethisterone 5 mg tab was prescribed 1 tab three times a day, then twice a day followed by once a day for three consecutive weeks.

A month later, on 15 Feb 2020, during the COVID-19 lockdown period, she had severe crampy lower abdominal pain followed with frequent voiding urgency and rectal hurry alike bearing down pain that lasted for several hours with resultant vaginal expulsion of huge about one Kg of fleshy mass with blood clots (Figure 1) that frightened her. Soon after expulsion of a mass, the pain subsided, got relief, and was lighter.

USG examination was done on the following day showed the uterine measurement of 55 x 60 x 96 mm and endometrial thickness equal to 5mm. Low dose combined oral contraceptive pills (COC) containing levonorgestrel 100 µg; ethinylestradiol 20 µg was prescribed daily for 21 days for three-cycle with 7 days of pill-free interval between cycles and advice for follow up after 3 months of the hormone. On the follow-up history, she was not resuming her menstrual period for the last 4 months.

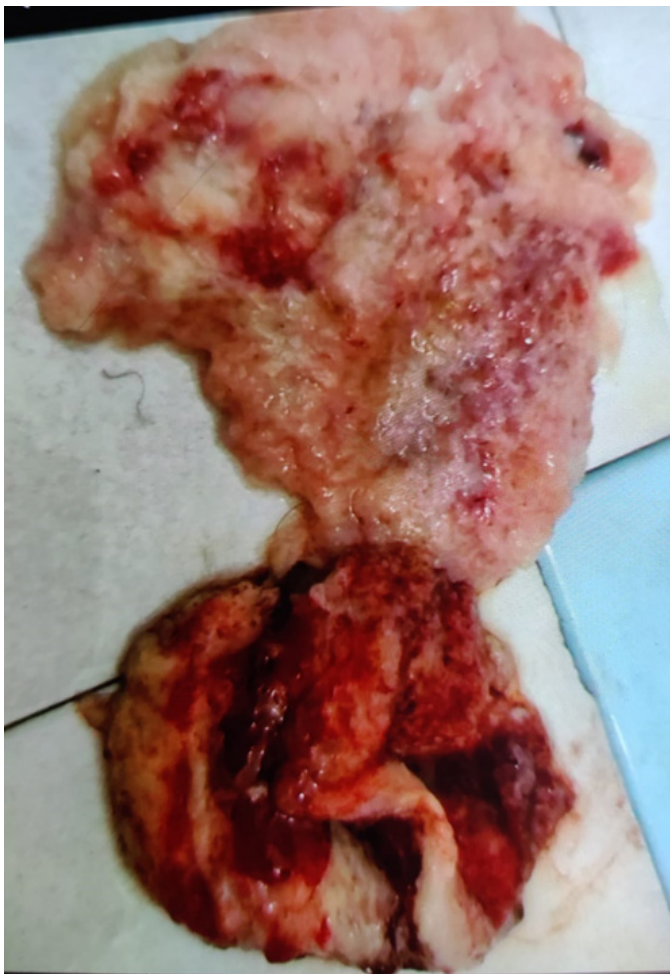


Figure 1: Decidual cast

Histopathological examination of the specimen (HPE S

6132/76), grossly showed a fibro-fatty fleshy mass (10 x 7 x 5 cm) retaining the shape endometrium similar to decidual cast which later on proven with the evidence of decidual cells with multiple dilated and variable sized secretory glands (Figure 1).

DISCUSSION

In this case, Norethisterone, a 19-nortestosterone derivative of progesterone, was associated with the expulsion of decidual cast retaining the shape of the endometrial cavity. It is secondary to spontaneous sloughing of the entire endometrium in one single cylindrical or membranous piece, ascribed to membranous dysmenorrhea, a rare entity with few reported sporadic cases.^{1,2} Apart from spontaneous membranous dysmenorrhea, it is also associated with hormonal contraceptives like progestin.³ Omar Ha et al.⁴ found that Medroxy Progesterone Acetate (DMPA) users had a history of the expulsion of the decidual cast. Apart from solely used progesterone alone, progesterone containing hormonal contraceptives either in oral preparations combined oral contraceptives preparations. The Ortho Tri-Cyclen Lo, active white tablets contains (0.18 mg of norgestimate, 0.25 mg) likewise light blue tab contains norgestimate 0.215 and dark blue tablets contain 0.250 mg of norgestimate respectively combined with low dose 35 mcg of Ethinyl estradiol in each. Desogestrel contains ethinylestradiol 0.02 mg and desogestrel 0.15 mg or transdermal hormonal patch like Ortho Evra containing norelgestromin/ethinylestradiol have also been claimed to association with the causation of membranous dysmenorrhea.⁵⁻⁷

Membranous dysmenorrhea ascribed to the vaginal passage of decidual cast, a bloody tissue resembling the endometrial cavity can well be differentiated from rhabdomyosarcoma, benign polyp, aborted pregnancy, and rarely a decidual cast of abdominal pregnancy. Membranous dysmenorrhea was reported around the age of 40 years. In our case it was occurred in the late twenty's, belonging to an age group above the commonly affected younger adolescents. The size of the decidual cast in our case was a larger size than in previous case reports.

Expulsion of endometrial/decidual cast has been reported after a variable length of hormone use, from a month to more than a year of discontinuation. And these variable hormonal contraceptives are clinically used to suppress profuse or irregular menstrual bleeding as so in our case or the treatment of spasmodic dysmenorrhea.

CONCLUSION

A rare, as well as incomparable case, is described in an unmarried nulligravida in the late twenties to alert the association of progesterone to membranous dysmenorrhea. So, everyone under the medications of progesterone for menstrual disorders must be educated for the potency of progesterone to painful vaginal expulsion of decidual cast ascribed to membranous dysmenorrhea, to cope with the fright.

REFERENCES:

1. Sharmila V, Thirunavukkarasu AB. Spontaneous membranous dysmenorrhea: a rare clinical entity. *Int J Reprod Contracept Obstet Gynecol* 2019;8:4094-6. [\[DOI\]](#)
2. Topçu HO, Topçu S, Kokanalı D, Memur T, Doğanay M. Spontaneous membranous dysmenorrhea in an adolescent girl: A case report and literature review. *J Pediatr Adolesc Gynecol*. 2015 Oct;28(5):e139-41. [\[DOI\]](#)
3. Oliveira PP, Eyng C, Zin RM, Menegassi J. Membranous dysmenorrhea: a forgotten disease. *Rev Bras Ginecol Obstet*. 2009 Jun;31(6):305-10. [\[DOI\]](#)
4. Omar HA, Smith SJ. Membranous dysmenorrhea: a case series. *The Scientific World JOURNAL*. 2007 Nov 26; 7:1900-3. *Scientific World Journal*. 2007 Nov 26;7:1900-3. [\[DOI\]](#)
5. Parkes P, Trainor JL, Raval M, Dhar CP. Endometrial Cast Expulsion: A Rare Cause of Pelvic Pain Case Report and Review of the Literature. *J Adolesc Health*. 2021 May;68(5):1017-1019. [\[DOI\]](#)
6. Şen Y, Cimbek EA, Uğraş NS. Decidual cast after discontinuation of oral contraceptives use in a young girl. *J Pediatr Adolesc Gynecol*. 2013 Dec; 26(6):e127-9. [\[DOI\]](#)
7. Veldman J, Van Houdenhove B, Verguts J. Chronic fatigue syndrome: a hormonal origin? A rare case of dysmenorrhea membranacea. *Arch Gynecol Obstet*. 2009 May; 279(5):717-20. [\[DOI\]](#)