



## CASE REPORT

### LATE ONSET CAPSULAR BLOCK SYNDROME AFTER MANUAL SMALL INCISION CATARACT SURGERY: A CASE REPORT

Sabin Sahu<sup>1,\*</sup>, Sanjay Kumar Singh<sup>1</sup>, Pragya Luitel<sup>2</sup>, Reena Yadav<sup>1</sup>, Bhadra Priya<sup>1</sup>, Sharad Hemant<sup>1</sup>

<sup>1</sup>Sagarmatha Choudhary Eye Hospital, Lahan – 3, Siraha, Nepal

<sup>2</sup>Biratnagar Eye Hospital, Rani, Biratnagar, Nepal

Received: 26 Aug, 2020

Accepted: 9 Nov, 2020

Published: 16 Dec, 2020

**Key words:** Capsular block syndrome; Continuous curvilinear capsulorrhexis; Nd:YAG capsulotomy; Posterior capsular opacification.

**\*Correspondence to:** Sabin Sahu, Sagarmatha Choudhary Eye Hospital, Lahan – 3, Siraha, Nepal.  
Email: [sabinsahu@gmail.com](mailto:sabinsahu@gmail.com)

#### Citation

Sahu S, Singh SK, Luitel P, Yadav R, Priya B, Hemant S. Late onset capsular block syndrome after manual small incision cataract surgery: a case report. Journal of Chitwan Medical College. 2020;10(34):114-6.



Peer Reviewed

#### ABSTRACT

Capsular block syndrome is a rare complication of cataract surgery seen with continuous curvilinear capsulorrhexis and in-the-bag placement of posterior chamber intraocular lens. We report an uncommon case of late postoperative fibrotic capsular block syndrome with posterior capsular opacification in an adult Nepali patient after uneventful manual small incision cataract surgery which was successfully treated with Nd: YAG laser capsulotomy without any complications.

#### INTRODUCTION

Capsular block syndrome (CBS) is an uncommon complication seen after cataract surgery with continuous curvilinear capsulorrhexis (CCC) and in-the-bag placement of a posterior chamber intraocular lens (PCIOL). Patient with this syndrome often have a myopic shift, anterior displacement of the iris lens diaphragm, shallow anterior chamber, raised intraocular pressure. It is characterized by adherence of the anterior capsule to the intraocular lens and blockage of the contents within the capsular bag.<sup>1</sup> Miyake et al.<sup>2</sup> has classified capsular block syndrome into intraoperative, early post-operative and late post-operative according to the time of onset. Kim and Shin<sup>3</sup> classified postoperative CBS into non-cellular, inflammatory and fibrotic according to the clinical characteristic and pathogenetic origin. We report a case of late post-operative capsular block syndrome with PCO in an adult Nepali male presenting three years after the uneventful manual small incision cataract surgery (SICS).

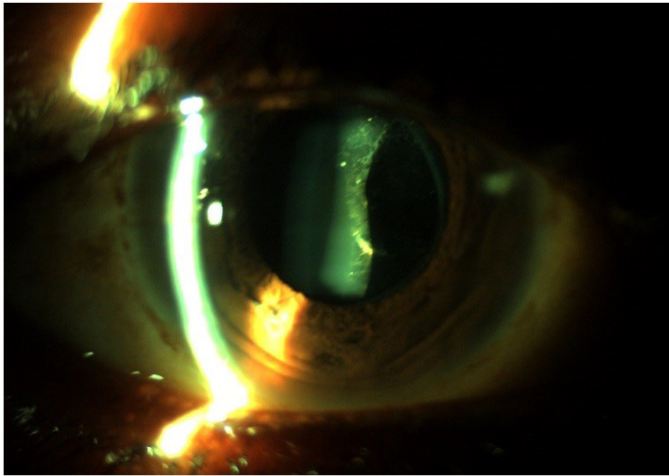
#### CASE REPORT

A 66-year-old Nepali male with no notable medical history presented with gradual blurring of vision in right eye for last

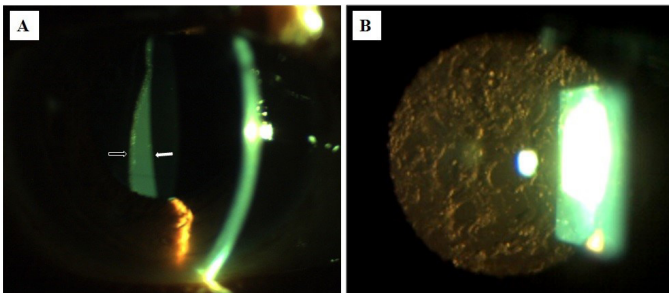
six months. His unaided visual acuity was 3/60 in the right eye and 6/60 in the left eye. The vision in the right eye was not improving with refraction while the left eye improved to 6/18 with -2.5 DS/-0.50 DC x 100° correction. The intraocular pressure on goldmann applanation tonometry was 12 mmHg in both eyes. He had undergone right eye uneventful manual small incision cataract surgery (SICS) and single piece polymethylmethacrylate (PMMA) posterior chamber intraocular lens (PCIOL) implantation three years back with good postoperative gain of vision. Slit-lamp examination under mydriasis showed clear cornea, quiet anterior chamber with normal anterior chamber depth, regular CCC with fibrosis between anterior capsule margin and optic of PCIOL, elschmig's pearl-type posterior capsular opacification (PCO) and collection of milky-white fluid between the posterior surface of intraocular lens (IOL) and posterior capsule in the right eye (Figure 1 & 2). Left eye showed nuclear sclerosis of grade II. Fundus examinations were normal in both eyes.

The diagnosis of right eye late onset capsular block syndrome with PCO was made and neodymium-yttrium-aluminum-garnet (Nd:YAG) capsulotomy to the posterior capsule was performed in the right eye. The milky-fluid dispersed into the vitreous cavity leading to disappearance of PCO and capsular

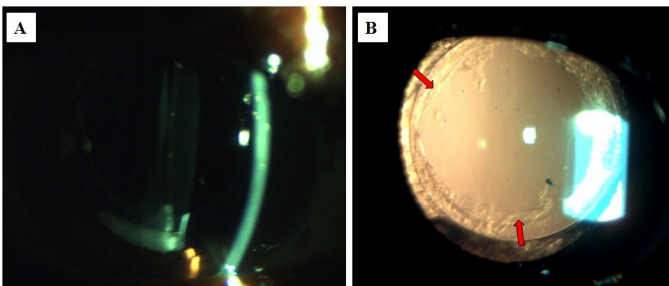
bag distension leaving the clear visual axis (Figure 3).



**Figure 1: Slit lamp photograph of right eye showing the milky-white fluid between the intraocular lens and posterior capsule and posterior capsular opacification**



**Figure 2: (A) Slit view of the right eye showing the milky-white fluid between the posterior surface of intraocular lens (white arrow) and the posterior capsule (black arrow). (B) Retro illumination view showing the elshnig's pearl-type posterior capsular opacification**



**Figure 2: (A) Slit view of the right eye after Nd:YAG capsulotomy showing the disappearance of the milky-white fluid into the vitreous cavity. (B) Retro illumination view after Nd:YAG capsulotomy showing clear visual axis, regular CCC margin with fibrosis between anterior capsule margin and optic of the well centered posterior chamber intraocular lens (red arrow)**

After the procedure, there was immediate improvement in visual acuity in the right eye to 6/9 with -0.50 DS/ -0.50 DC x 100° correction. The patient was prescribed topical prednisolone 1% four-times-a-day and timolol 0.5% twice daily for a week. The patient had uneventful follow up for last three months.

## DISCUSSION

Capsular block syndrome is a rare complication of cataract surgery that occurs with posterior chamber in-the-bag IOL implantation and CCC. It was first described by Davison<sup>4</sup> in 1990 as an early postoperative complication. Since then several case studies of postoperative CBS have been reported. Miyake et al.<sup>2</sup> classified capsular block syndrome into intraoperative, early post-operative (occurring 1-15 days after surgery) and late post-operative (occurring an average of 3.8 years after surgery). Kim and Shin<sup>3</sup> divided postoperative CBS into three types: non cellular, inflammatory, and fibrotic. Non cellular CBS occurs within a day after surgery and is caused by an ophthalmic visco-surgical device. Inflammatory CBS develops several days after surgery and is caused by severe inflammatory cellular reaction. Fibrotic CBS occurs in late postoperative period and is characterized by fibrosis over the entire circumference of the anterior capsule opening and PCO.<sup>3</sup> In our case, milky-white fluid accumulation was seen between IOL and posterior capsule along with the fibrosis in the entire anterior capsule opening and elshnig's pearl-type PCO suggesting late postoperative fibrotic CBS with PCO.

CBS is clinically characterized by capsular bag distension, anterior displacement of the iris lens diaphragm, shallow anterior chamber and unexpected myopic shift. Myopic shift is usually seen in intraoperative and early postoperative CBS due to forward displacement of the IOL<sup>1</sup> while in late postoperative CBS myopic shift, hyperopic shift or no change in refraction have been reported.<sup>5,6</sup> Although CBS is a clinical diagnosis, a definitive diagnosis and better characterization of anatomical structures can be achieved by using diagnostic aids such as anterior segment ultrasound biomicroscopy (UBM), optical coherence tomography (OCT) and Scheimpflug-based photography (Pentacam).<sup>7</sup>

Late postoperative CBS are usually underdiagnosed due to its asymptomatic nature and can be mistaken for PCO. The PCO and late postoperative CBS are treated by creating an opening in the posterior capsule with the Nd:YAG laser.<sup>8,9</sup> Other potential management options for CBS include observation, use of anti-inflammatory medications in presence of inflammation<sup>3</sup>, slit lamp needle revision<sup>10</sup>, surgical aspiration of fluid<sup>11</sup> or pars plana vitrectomy with surgical removal of posterior capsule.<sup>12</sup> Nd:YAG laser capsulotomy can fail in some cases due to inability to accurately focus the laser beam on the posterior capsule because of the opacity of the contents in the distended capsular bag and the surgical drainage of the entrapped fluid need to be performed in such case.<sup>11</sup> However, we did not encounter such difficulty and Nd:YAG capsulotomy was successfully done. After Nd:YAG capsulotomy the fluid accumulated behind the IOL and posterior capsule gets dispersed into vitreous cavity or the anterior chamber. The accumulated fluid behind the IOL in CBS have been reported to contain *Propionibacterium acne*,<sup>12</sup> so the access of the fluid into the vitreous cavity might cause a delayed endophthalmitis. In our case the dispersed milky-white fluid was cleared from the vitreous cavity without any consequences like inflammation or raised intraocular pressure after Nd:YAG capsulotomy.

## CONCLUSION

We report a case of late post-operative fibrotic CBS with PCO in an adult Nepali patient presenting three years after the un-

eventful manual small incision cataract surgery. The case was successfully managed with Nd: YAG laser capsulotomy without any complications.

## REFERENCES:

1. Theng JT, Jap A, Chee SP. Capsular block syndrome: a case series. *Journal of Cataract & Refractive Surgery*. 2000 Mar 1;26(3):462-7. [\[DOI\]](#)
2. Miyake K, Ota I, Ichihashi S, Miyake S, Tanaka Y, Terasaki H. New classification of capsular block syndrome. *Journal of Cataract & Refractive Surgery*. 1998 Sep 1;24(9):1230-4. [\[DOI\]](#)
3. Kim HK, Shin JP. Capsular block syndrome after cataract surgery: clinical analysis and classification. *Journal of Cataract & Refractive Surgery*. 2008 Mar 1;34(3):357-63. [\[DOI\]](#)
4. Davison JA. Capsular bag distension after endophacoemulsification and posterior chamber intraocular lens implantation. *Journal of Cataract & Refractive Surgery*. 1990 Jan 1;16(1):99-108. [\[DOI\]](#)
5. Patil S, Azarbod P, Toufeeq A. Late-onset capsular block syndrome without lens displacement. *Eye*. 2007 Jan;21(1):113-4. [\[DOI\]](#)
6. Shah NA, Goulstine DB. Capsular block syndrome presenting with a hyperopic shift. *Journal of Cataract & Refractive Surgery*. 2006 Nov 1;32(11):1974-6. [\[DOI\]](#)
7. Vélez M, Velásquez LF, Rojas S, Montoya L, Zuluaga K, Balparda K. Capsular block syndrome: a case report and literature review. *Clinical Ophthalmology (Auckland, NZ)*. 2014;8:1507. [\[DOI\]](#)
8. Landa G, Hoffman P, Pollack A, Bukelman A, Leiba H, Marcovich A. Outcome of posterior capsulotomy in late capsular block syndrome with posterior capsular opacification. *Clinical & experimental ophthalmology*. 2006 Dec;34(9):866-9. [\[DOI\]](#)
9. Pinsard L, Rougier MB, Colin J. Neodymium: YAG laser treatment of late capsular block syndrome. *Journal of Cataract & Refractive Surgery*. 2011 Nov 1;37(11):2079-80. [\[DOI\]](#)
10. Mardelli PG. Slitlamp needle revision of capsular block syndrome. *Journal of Cataract & Refractive Surgery*. 2008 Jul 1;34(7):1065-9. [\[DOI\]](#)
11. Qu J, Bao Y, Li M, Zhao M, Li X. Surgical management of late capsular block syndrome. *Journal of Cataract & Refractive Surgery*. 2010 Oct 1;36(10):1687-91. [\[DOI\]](#)
12. Kollias AN, Vogel MA, de Kaspar HM, Lackerbauer CA, Grueterich M. *Propionibacterium acnes* in capsular bag distension syndrome. *Journal of Cataract & Refractive Surgery*. 2010 Jan 1;36(1):167-9. [\[DOI\]](#)