

ORIGINAL RESEARCH ARTICLE

VARIATIONS IN FORMATION OF MEDIAN NERVE: A CADAVERIC STUDY

Shanta Hada^{1*}, Muna Kadel², Tinku Kumari Pandit¹, Kishore Singh Basnet¹

¹Department of Anatomy, KIST Medical College, Lalitpur, Nepal,

²Department of Anatomy, Nepal Army Institute of Health Sciences, Kathmandu Nepal.

Received: 15 Aug, 2020

Accepted: 3 Sept, 2020

Published: 27 Sept, 2020

Key words: Brachial plexus; Median nerve; Roots; Variations.

**Correspondence to: Shanta Hada, Department of Anatomy, KIST Medical College, Imadol, Lalitpur, Nepal.
Email: shantahada@gmail.com*

Citation

Hada S, Kadel M, Pandit TK, Basnet KS. Variations in formation of median nerve: a cadaveric study. Journal of Chitwan Medical College. 2020;10(33):66-8.



ABSTRACT

Background: Median nerve is generally formed in axilla, as one of the branch of brachial plexus. It is formed by the union of medial and lateral roots which are the branches of medial and lateral cord respectively. The knowledge of origin, course and area of distribution of median nerve is important for the anatomist, the neurologist and also for correction of traumatic injuries that are related to brachial plexus. The main objective of this study is to observe different variations in median nerve formation in cadavers.

Methods: A descriptive cross-sectional study was conducted in 25 formalin fixed adult human cadavers in the Department of Anatomy, KIST Medical College and Teaching Hospital, Lalitpur Ethical approval was taken. Altogether, 50 specimens were enrolled in the study by convenient sampling method. The calculation was done using Statistical Package for Social Sciences version 20 (SPSS).

Results: In this study the formation of median nerve was observed to be normal in 78% of the cases. In 20% cases three roots were forming the median nerve and in 2% cases four roots were present. Among these variations in 18% cases the additional roots were observed to be given by the lateral cord of the brachial plexus.

Conclusions: This study concludes that most of the median nerve forms in axilla by the union of two roots with few variations.

INTRODUCTION

Median nerve is one of the branches of brachial plexus formed by the union of two roots, lateral root from lateral cord and medial root from medial cord. It is present in front or to the lateral aspect of axillary artery in the axilla.¹

Variations in the arrangement and distribution of brachial plexus are common. The unusual branches are more prone to injury during the surgical operations in axilla and are also vulnerable in routine nerve repair.² The knowledge about the variations is significant for the neurologists, surgeons, anesthetists and the anatomists. This may contribute in explaining the diagnosis and surgical treatment around axilla and upper limb which can prevent operative as well as post operative complications.³

The main objective was to study the variation in formation of the median nerve and its location.

METHODS

A descriptive cross-sectional study was conducted in the Department of Anatomy, KIST Medical College and Teaching Hospital, Lalitpur, Nepal. Data collection was done from

18/04/2019 to 29/01/2020 after obtaining ethical approval from Institutional Review Committee (IRC NO. 2075/76/66). Properly embalmed and well preserved 25 adult human cadavers of both sexes with intact nerves were included in the study. Cadavers with any kind of upper limb anomalies and cut branches of brachial plexus were excluded from the study. The fixed specimens (50 limbs) were dissected following the steps of Cunningham's Manual of Practical Anatomy vol.1.⁴ The ethical standards of handling cadaver for teaching and learning purpose were followed during the procedures.

Sample size was calculated by using following formula;

$$n = (z)^2 p (1 - p) / d^2$$
$$= (1.96)^2 \times 0.93 \times 0.07 / (0.08)^2$$
$$= 39.7$$

Where

n= required sample size

z = 1.96 at 95% confidence interval

p = estimated proportion of the population that presents the characteristic (p = 90.6%)⁵

d = margin of error (8%)

According to this calculation, at least 51 samples were required. Altogether, 50 specimens were enrolled in the study by convenient sampling method. The cadavers were numbered from 01 to 25. Median nerve was studied in respect to its location and formation. The median nerve with additional roots were tagged and photographs were taken. All the observations were recorded and tabulated. The data was analyzed with the help of SPSS version 20 software.

RESULTS

The location of median nerve was axilla in 92% of specimen. In 78% (39/50) cases, the formation of median nerve was observed to be normal with two roots (Table 1).

Table 1: Distribution of variations of median nerve

	Right N (%)	Left N (%)	Total N (%)
No. of roots			
Two (normal)	18 (72)	21 (84)	39 (78)
Three	6 (24)	4 (16)	10 (20)
Four	1 (4)	0%	1 (2)
Location of median nerve			
Axilla	24 (96)	22 (88)	46 (92)
Arm	1 (4)	3 (12)	4 (8)

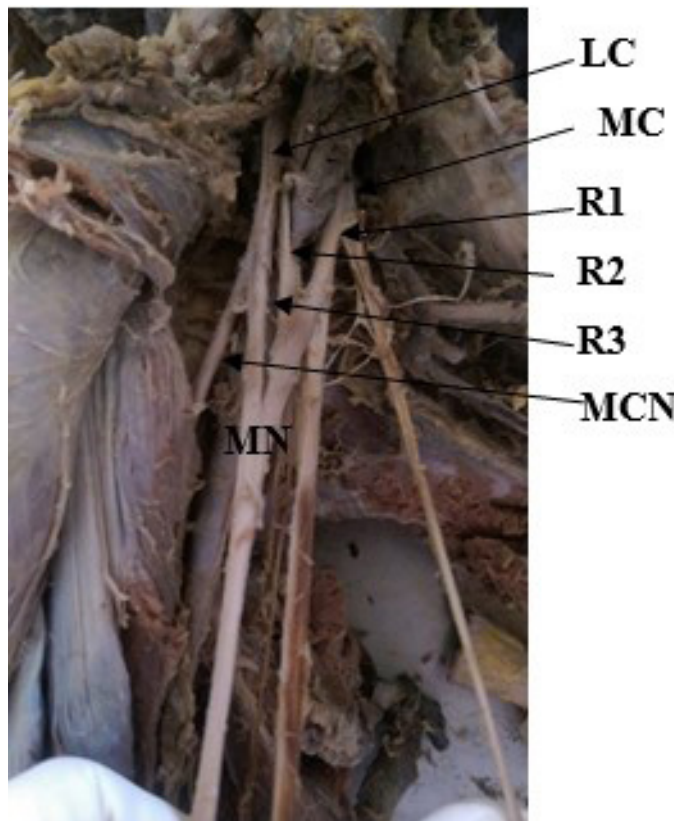


Figure 1: Median nerve with three roots.

Note: R1- Medial root; R2 – additional root; R3 – lateral root; LC – lateral cord; MC – Medial cord; MCN – Musculocutaneous nerve; MN – Median nerve.

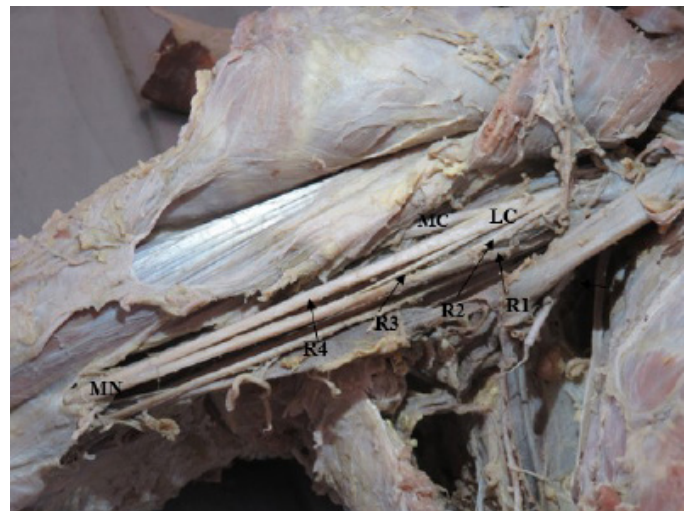

Figure 2: Median nerve with four roots.

Note: R1- Medial root; R2 – Additional root; R3 – Additional root; R4 – Lateral root; LC – Lateral cord; MC- Musculocutaneous nerve; MN – Median nerve.

In 20% (10/50) of cases median nerve had three roots among these 18% (9/50) cases had additional root arising from the lateral cord of brachial plexus (Figure 1). In 2% (1/50) of the cases four roots were forming the median nerve (Figure 2) and both the additional roots were branches of the lateral cord.

The variations were mostly seen in right upper limb which was 24% (6/25) and on the left upper limb it was present in 16% (4/25) cases.

Only in 2 cadavers the additional roots in median nerve were present in both limbs. Both cadavers had 3 roots in both limb and the additional root was the branch from lateral cord.

DISCUSSION

Brachial plexus is associated with several variations such as in its formation, branches and communication.⁵ Median nerve is one of the branches of brachial plexus whose variations regarding its formation and its communication with other nerves has been reported by many authors. Different authors have reported the formation of median nerve with additional roots.⁶⁻⁸ In present study we observed variation in 22% (11/50) cases. Mostly the variations with three roots were seen. Due to the difference in the sample size the percentage in this study was different from other studies.

Buddhiraja et al reported the presence of three roots in 22.4% (44/196) cases, where additional roots were given by lateral cord in 14.2% cases and in 8.16% cases from musculocutaneous nerve. Similarly, four roots were present in 3.75% (7/196) cases with additional roots from both lateral and musculocutaneous nerve.⁹ Similar type of observation with trifurcated origin in 26.41% and median nerve with four roots in 1.88% cases was present in study by Laxmi Kumari et al.¹⁰ Among the four roots two roots were from lateral cord and two from the me-

dial cord.¹⁰ This contradicts our present finding where all the additional roots were given by lateral cord for median nerve with four roots.

Satyanarayan et al¹¹ reported three different unilateral variations of median nerve regarding its formation and relation with axillary nerve. Similarly, another study has also reported the presence of unilateral variation of median nerve.⁸ Mat Taib et al reported 36.4% and 18.2% variation in the formation of median nerve on left and right side respectively.³

In this study 8% of cases presented formation of median nerve in the arm instead of axilla. Laxmi Kumari A et al¹⁰ reported the formation of median nerve in arm in 8.49% cases. Similarly, in another study in 17.3% cases formation was taking place in the arm.⁹ The presence of median nerve in arm with the additional branches has also been reported.⁶

This study has been conducted in a limited number of cadavers. Out of 25 cadavers only 3 cadavers were of female, because of

this reason it was not possible to include the study of sexual dimorphism.

CONCLUSION

There might be variation in number of roots as well as location of formation of median nerve. Knowledge regarding such variation is important during the surgical operations to prevent operative as well as postoperative complications.

ACKNOWLEDGEMENT

The author would like to extend heartfelt gratitude towards Professor Dr. Prakash Man Singh Dangol for his constant guidance and support throughout this research.

CONFLICT OF INTEREST: None

FINANCIAL DISCLOSURE: None

REFERENCES:

1. Standring S. Gray's Anatomy: The Anatomical Basis of Clinical Practice. 41st ed. Edinburgh, London: Churchill Livingstone, Elsevier; 2016. pp.832.
2. Bhanu PS, Sankar KD, Susan PJ. Formation of median nerve without the medial root of medial cord and associated variations of the brachial plexus trunk. *IJAV*. 2010 Feb;(3):27-9. [\[LINK\]](#)
3. Mat Taib CN, Hassan SNA, Esa N, Mohd Moklas MA, San AA. Anatomical variations of median nerve formation, distribution and possible communication with other nerve in preserved human cadavers. *Folia Morphol*. 2017;76(1):38-43. [\[LINK\]](#)
4. Romanes GJ. Cunningham's Manual of Practical Anatomy. 15th ed., vol 1. New York: Oxford University Press Inc; 1986. p. 20-34
5. Emamhadi M, Chabok SY, Samini F, Alijani B, Behzadnia H, Firozabadi FA, et al. Anatomical Variations of Brachial Plexus in Adult Cadavers; A Descriptive Study. *Arch Bone Jt Surg*. 2016;4(3):253-8. [\[PMC\]](#)
6. Bala A, Sinha P, Tamang BK, Sarda RK. Anatomical variation: median nerve formation - a case vignette. *J Clin Diagn Res*. 2014;8(6):AD03-4. [\[PMC\]](#) [\[DOI\]](#)
7. Darwish HH, Khan MM, Alkokani MAF, Zaher WA. Bilateral variation in the formation of median nerve associated with absence of musculocutaneous nerve and radial nerve with two roots. *Eur J Anat*. 2009;13(1):33-6. [\[LINK\]](#)
8. Bharti A, Paranjpe VM, Apte MV. Variations in the formation and relation of median nerve. *Int J Anat Res* 2015;3(3):1298-301. [\[DOI\]](#)
9. Budhiraja V, Rastogi R, Asthana AK. Anatomical variations of median nerve formation: embryological and clinical correlation. *J. Morphol. Sci*. 2011;28(4):283-6. [\[LINK\]](#)
10. Lakshmi Kumari K, Someshwar Rao M, Ashalatha D, G. Elena K, Sailaja LL. Anatomical variation in the formation and course of median nerve: a cadaveric study. *Int J Res Med Sci* 2015;3:1345-7. [\[DOI\]](#)
11. Satyanarayana N, Vishwakarma N, Kumar GP, Guha R, Datta AK, Sunitha P. Rare variations in the formation of median nerve- embryological basis and clinical significance. *Nepal Med Coll J*. 2009;11(4):287-290. [\[LINK\]](#)