

## CASE REPORT

### ASCARIS INFECTION, A RARE CAUSE OF NECROTIZING PANCREATITIS IN A CHILD

Aditya Prakash Yadav<sup>1,\*</sup>, Rishi Kumar Karki<sup>1</sup>, Binod Kumar Rai<sup>2</sup>

<sup>1</sup>National Medical College teaching hospital Birgunj, Nepal

<sup>2</sup>Department of Surgery, National Medical College Teaching Hospital Birgunj, Nepal.

Received: 13 Oct, 2019

Accepted: 7 Mar, 2020

Published: 13 Mar, 2020

**Key words:** Biliary Pancreatitis; Necrotizing Pancreatitis; Peritonitis.

*\*Correspondence to: Aditya Prakash Yadav,  
Department of Surgery, National Medical College  
Teaching Hospital, Birgunj, Nepal.  
Email: [dradityayadav1@gmail.com](mailto:dradityayadav1@gmail.com)*

DOI: <https://doi.org/10.3126/jcmc.v10i1.28081>

#### Citation

Yadav AP, Karki RK, Rai BK. Ascaris infection, a rare cause of necrotizing pancreatitis in a child. Journal of Chitwan Medical College. 2020;10(31):88-90.



Peer Reviewed

#### ABSTRACT

Necrotizing pancreatitis is a very rare in children and is associated with high morbidity & mortality rates. We report a case of 5yr old boy who presented with upper abdominal pain, vomiting and non-passage of stool for 1day. After resuscitation and investigating the child, a provisional diagnosis of biliary ascariasis (BA) with acute pancreatitis was made. The child developed peritonitis after 2 days of admission and exploratory laparotomy was planned. An intraoperative diagnosis of necrotizing pancreatitis was made and the child was successfully managed.

#### INTRODUCTION

Acute pancreatitis is an inflammatory illness of variable severity, characterized by acute inflammation of the pancreatic parenchyma and peripancreatic tissues and it is characterized by epigastric pain, nausea and vomiting. Recent studies indicate that prevalence is more in children of acute pancreatitis.<sup>1</sup> In the majority of cases, acute pancreatitis resolves with bowel rest and does not result in severe complications in children. It can rarely be complicated by the development of necrosis.

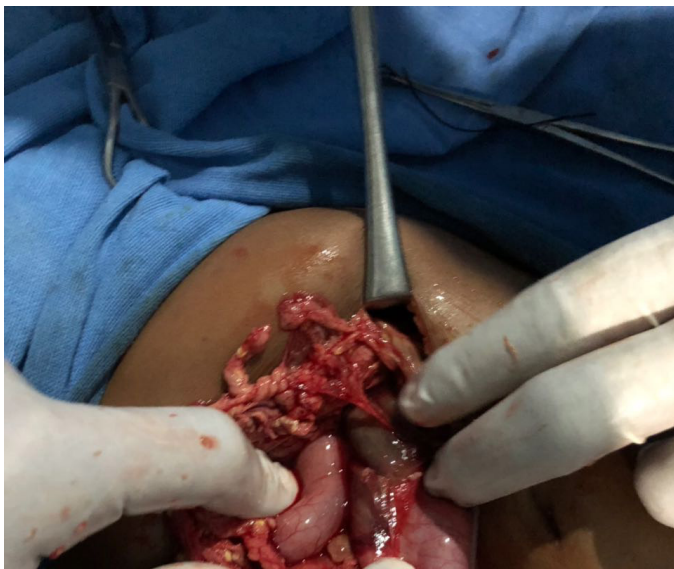
Acute necrotizing pancreatitis is a serious condition associated with high morbidity and mortality rates in adults.<sup>2</sup> It is well described in adult but the literature is very limited with regards to pediatrics population. It has been estimated that necrotizing pancreatitis occurs in less than 1 % of children with acute pancreatitis.<sup>3</sup> From five large pediatric series in the United States, pancreatic necrosis was observed in only 3 out of 1014 children.<sup>1,4,5</sup> There are a few case reports of necrotizing pancreatitis in children, however the data are limited regarding etiology, course, and outcome.

#### CASE REPORT

A 5-year-old boy presented to the emergency department of National Medical College and Teaching Hospital with history of upper abdominal pain and multiple episodes of vomiting for 1 day. The pain was sudden in onset, severe, with no known aggravating or relieving factors. The vomitus was non billous. There was history of non-passage of stool for the same duration. On examination, the patient was in a state of shock. Abdominal examination revealed fullness of the epigastrium, generalized tenderness, absent bowel sounds and an empty rectum. Following resuscitation in the emergency department, the child was shifted to ICU for further care. His CBC showed a total count of 18,500cells/mm<sup>3</sup> with neutrophil of 85%. Liver Function Test showed total bilirubin is 2.30mg/dl with direct bilirubin of 1.08mg/dl, alkaline phosphate 490IU/L, SGOT (146IU/L), SGPT (87IU/L). Serum amylase was 1700IU/L. Renal Function Test were normal. X-ray of abdomen revealed few dilated loops of intestine. USG of abdomen revealed gallbladder and CBD ascariasis with acute pancreatitis and complex ascites. A CT Scan was planned after the stabilization of the child.

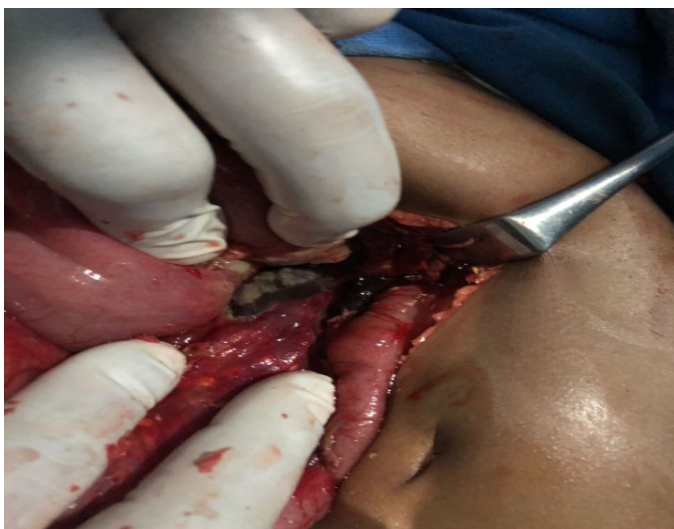On 3<sup>rd</sup> day of admission, the patient developed features of generalized peritonitis and exploratory laparotomy was planned.

Upon entering the peritoneal cavity, about 500ml of reddish fluid was encountered and was drained. There was multiple calcification in the omentum and mesentery (Figure 1).



**Figure 1: Calcification of mesenteric and omentum**

Gall bladder and CBD were free of worms but few worms were noticed in the proximal jejunum that were milked into the large intestine. Upon entering the lesser sac, a necrotic mass of 4x4cm was seen along the stomach bed ensuring a mass effect on the stomach & transverse colon (Figure 2). The mass was arising from the tail of pancreas. The Necrosectomy was done and drains were placed in the lesser sac, retroperitoneal space and in the pelvis after thorough peritoneal lavage.



**Figure 2: Necrotizing mass between transverse colon and stomach**

Post-operatively, the child was managed in surgical ICU. Inj. octreotide along with broad spectrum antibiotic were started on 3<sup>rd</sup> postoperative day. Serum amylase was repeated on 5<sup>th</sup> POD and it was within normal limits (80IU/L). the drain from lesser sac initially put out 100ml/day of hemorrhagic fluid, but the output tapered down to 5ml/day of serous for two days prior to its removal on 10<sup>th</sup> days. On 10<sup>th</sup> post-operative day sips were allowed and on 12<sup>th</sup> day liquid diet was started. On 14<sup>th</sup> post-operative day, soft to normal diet was allowed and the patient was discharged on 15<sup>th</sup> POD. His biopsy report of necrotic tissue shows feature of necrotizing pancreatitis. The patient was doing well on his follow up visit.

## DISCUSSION

Necrotizing Pancreatitis, a severe form of acute pancreatitis is very rare in pediatric population. It has a variable etiology in children. Various literature have shown that necrotizing pancreatitis in children can be caused by use of valproate,<sup>7</sup> *M. pneumonia*<sup>6</sup> and secondary to Crohn's disease.<sup>8</sup> Although *Ascaris* infection may be a cause of acute pancreatitis, progression to necrotizing Pancreatitis as result of it is rarely seen, as was noticed in our case.

*Ascaris* infection occurs in about 25% of world population and most infection are asymptomatic. A wide range of symptoms including fever, nausea, vomiting, diarrhea, pain abdomen may be present when patient is symptomatic.<sup>9</sup> About 500 cases of hepatobiliary and pancreatic disease due to ascariasis in adult have been reported by Khurro et al.<sup>10</sup>

Pancreatitis due to ascariasis may be caused by the obstruction of papilla of Vater, invasion of CBD, invasion of pancreatic duct USG, CT or MRCP, ERCP along with relevant lab investigation may help in the diagnosis of pancreatitis. Most case can be managed conservatively with antispasmodics, analgesics, IV fluids, bowel rest and anthelmintic therapy.<sup>11</sup> Rarely endoscopic intervention may be required. In our case since the child has developed feature of peritonitis, we choose for surgical treatment after which the child was successfully managed.

In summary, we reported a case of necrotizing pancreatitis with peritonitis due to infestations with *ascaris*, which is rare cause in young child. The child was surgically managed and recovered completely.

## REFERENCES:

1. Park A, Latif SU, Shah AU, Tian J, Werlin S, Hsiao A, Pashankar D, Bhandari V, Nagar A, Husain SZ. Changing referral trends of acute pancreatitis in children: a 12-year single-center analysis. *Journal of pediatric gastroenterology and nutrition*. 2009 Sep;49(3):316-22. [\[DOI\]](#)
2. Baron TH, Morgan DE. Acute necrotizing pancreatitis. *New England Journal of Medicine*. 1999 May 6;340(18):1412-7. [\[DOI\]](#)
3. Whitcomb DC, Lowe ME. Pancreatitis: acute and chronic. *Pediatric gastrointestinal disease: pathophysiology, diagnosis, management*. 4th ed. Hamilton, Ont., Canada: BC Decker. 2004:1584-97.
4. DeBanto JR, Goday PS, Pedroso MR, Iftikhar R, Fazel A, Nayyar S, Con-

- well DL, DeMeo MT, Burton FR, Whitcomb DC, Ulrich II CD. Acute pancreatitis in children. *The American journal of gastroenterology*. 2002 Jul 1;97(7):1726-31. [\[DOI\]](#)
5. Kandula L, Lowe ME. Etiology and outcome of acute pancreatitis in infants and toddlers. *The Journal of pediatrics*. 2008 Jan 1;152(1):106-10. [\[DOI\]](#)
  6. Nakagawa M, Ogino H, Shimohira M, Hara M, Shibamoto Y. Continuous regional arterial infusion therapy for acute necrotizing pancreatitis due to *Mycoplasma pneumoniae* infection in a child. *Cardiovascular and interventional radiology*. 2009 May 1;32(3):581-4. [\[DOI\]](#)
  7. Tobias JD, Capers C, Sims P, Holcomb GW. Necrotizing pancreatitis after 10 years of therapy with valproic acid. *Clinical pediatrics*. 1995 Aug;34(8):446-8. [\[DOI\]](#)
  8. Briem-Richter A, Grabhorn E, Wenke K, Ganschow R. Hemorrhagic necrotizing pancreatitis with a huge pseudocyst in a child with Crohn's disease. *European journal of gastroenterology & hepatology*. 2010 Feb 1;22(2):234-6. [\[DOI\]](#)
  9. Carneiro FF, Cifuentes E, Tellez-Rojo MM, Romieu I. The risk of *Ascaris lumbricoides* infection in children as an environmental health indicator to guide preventive activities in Caparaó and Alto Caparaó, Brazil. *Bulletin of the World Health Organization*. 2002;80:40-6. [\[PMID\]](#)
  10. Khuroo MS, Zargar SA, Mahajan R. Hepatobiliary and pancreatic ascariasis in India. *The Lancet*. 1990 Jun 23;335(8704):1503-6. [https://doi.org/10.1016/0140-6736\(90\)93037-p](https://doi.org/10.1016/0140-6736(90)93037-p)
  11. Yattoo GN, Wani FA, Para RA, Chandal KH, Parry AH. Pancreatitis secondary to *ascaris lumbricoides*: A case series analysis. *International Journal of Medical Research & Health Sciences*. 2013;2(3):673-7. [\[LINK\]](#)
  12. Vizcarrondo FJ, Brady PG, Nord HJ. Foreign bodies of the upper gastrointestinal tract. *Gastrointest Endosc*. 1983 Aug;29(3):208-10. [\[DOI\]](#)