

ORIGINAL RESEARCH ARTICLE

CLINICAL AND SONOHYSTEROGRAPHY EVALUATION OF INFERTILE WOMEN

Upendra Pandit^{1,*}, Lekhnath Baral²

¹Department of Obstetrics and Gynecology, Chitwan Medical College, Bharatpur-10, Nepal

²Department of Radio- diagnosis, Nepalgunj Medical College, Teaching Hospital, B.P. Chowk, Nepal

Received: 29 Dec, 2019

Accepted: 11 Mar, 2020

Published: 13 Mar, 2020

Key words: HSG; Sonohysterosalpingography; Tubal occlusion; Tubal patency.

***Correspondence to:** Upendra Pandit, Department of Obstetrics and Gynecology, Chitwan Medical College, Bharatpur-10, Nepal.

Email: drupandit@gmail.com

DOI: <https://doi.org/10.3126/jcmc.v10i1.28073>

Citation

Pandit U, Baral L. Clinical and sonohysterography evaluation of infertile women. Journal of Chitwan Medical College. 2020;10(31):58-63.



Peer Reviewed

ABSTRACT

Background: Hysterosalpingography (HSG) is an integral part of the Conventional clinical evaluation of infertile women. Now a day, Sonohysterography is a modern technique widely used in the clinical evaluation. The objective of this study was to identify pelvic pathology; compare the effect and findings of tubal patency test between Sonohysterosalpingography and single film HSG radiograph.

Methods: This is a prospective evaluation of infertile women who attended the infertility unit of the gynecology department from 2017 March to 2018 October. Women 220 clients were subjected to clinical including SHSG evaluation followed by a single film HSG radiograph on the single sitting. The Chi-square test, multinomial logistic regression analysis was done using IBM SPSS statistics version 20.

Results: Women had bilateral tubal patency 181(82.2%) in SHSG and conformed the same number later by HSG. SHSG showed bilateral tubal occlusion in 33 (15%) whereas HSG conformed only in 22(10%) and block was seen in 18(8.18%) only by HSG. The pathological findings were polycystic ovaries in 33 (15%), Fibroid uterus 11 (5%), ovarian cysts 5(2%), endometrial polyps in 2 cases, endometriotic cyst with hydrosalpinx 8(4%). Procedural side effects were no pain in 69(31.1%), mild pain 125(56.3%), Moderate pain 21(9.5%), vasovagal symptoms 7(3.1%).

Conclusions: The outcome of the Sonohysterosalpingography (SHSG) test for tubal patency is significantly synergized by concurrent HSG in the same sitting. The combined test is best indicated if SHSG alone is not able to demonstrate the sign of tubal patency.

INTRODUCTION

Clinical and Hysterosalpingography (HSG) is the conventional method of evaluation of genital tract. Now a day's Ultrasonography like TVS, Sonohysterography and Sonohysterosalpingography (SHSG) evaluations are most widely used and commonly preferred than conventional methods.

The Sonohysterography is more sensitive than Transvaginal ultrasonography and is as good as hysteroscopy in detecting intracavitary pathologies like polyps, submucosal myomas which can be asymptomatic in infertile women.¹⁻⁶ It can be performed in outpatient clinics with minimal side effects to the patient, in a short time, with simple and inexpensive instruments.⁷⁻⁹ Several modifications have been made to this basic procedure of sonohysterosalpingography (SHSG) to improve its diagnostic accuracy as well as an investigative modality for tubal assessment. The common modifications with sonohysterosalpingography are Saline, HyCoSy, HyFoSy, color Doppler, Three-dimensional (3D).¹⁰⁻¹²

All above-mentioned modifications need expertise which is always lack in low cost care settings. Frequent visits for the

evaluation also increased cost as well as lower the clinical compliance to the client. The truth is that no single procedure is superior to date. So, this study was a simple low-cost evaluation technique which is a simple combination of two procedures SHSG and HSG in a single sitting. The reason behind this combination is that the evaluation of adnexa is best done by SHSG and the tubal patency test is best done by HSG.

The aim of this study was to identify pelvic pathology; compare the effect and findings of the tubal patency test between Sonohysterosalpingography and single film HSG radiograph in a single sitting.

METHODS

This was a prospective study of infertile women with a history of primary and secondary infertility attending the infertility clinic in their reproductive age. A total of 222 infertile women who had undergone clinical evaluation consecutively from 2017 March to 2018 October at Infertility unit of Obstetrics and Gynecology in Nepalgunj Medical College Teaching hospital Nepalgunj was enrolled in the clinical evaluation. Patient having active pelvic infection, active vaginal bleeding, malignancy of the genital tract and suspected pregnancy was excluded from

the study.

All women in their 7-10 day of their monthly period were called for the evaluation. All investigation report like Cumulative blood count (CBC), Serology, Thyroid Function Tests were done. The informed written consent for the detailed procedures SHSG and HSG in the same sitting was taken beforehand. The patient was asked to empty her bladder immediately before the examination. The patient was put in a dorsal position, perineum painted with Betadine and draped. Vagina was cleaned with Betadine solution. The cervix was visualized with the help of Syms' speculum and vulsellum and cleaned with normal saline. Those patients with evidence of severe cervical erosion or vaginitis were undertaken for the evaluation in the next cycle after the 10-day course of treatment. The uterine sound was passed, the position and the size of the uterus were estimated and outer cervical stenosis is ruled out. Then, without analgesia a semi-rigid Foley's Catheter 8 French was inserted into the uterine cavity and the balloon was inflated with 3 ml of sterile water and pulled back to occlude the internal os followed by a Transvaginal scan (TVS). For transvaginal scan, transducer 3.5 MHz was prepared for use with coupling gel followed by application of a condom which was again lubricated with coupling gel before insertion.

The cervix, uterus, and ovaries were evaluated. The tubal evaluation was done concurrently injecting 14 ml of normal saline through an indwelling Foley catheter. The resistance to the free entry of saline and was the subjective feeling of pain or discomfort expressed by the patient was noted as well. The distension of the endometrial cavity with fluid was visualized. Right and left ovarian fosses of the respective fallopian tubes were observed and looked for the flow of fluid and air the "waterfall sign" in the region simultaneously. Later, the cul-de-sac was also observed for the flow of free fluid. In the presence of tubal occlusion, the uterine cavity expands in size and no waterfall sign is observed.¹³ The patient may also experience discomfort and complained of minimal lower abdominal pain. At the end of the clinical Sonohysterosalpingography, 6 ml of water-soluble radio contract dye Urograffin 76% was injected into the uterine cavity through the Foley's Catheter. The bulb of Foley's Catheter deflated and the catheter was removed as soon as the procedure completed. Vital signs were taken if the client feels comfortable then she was carried on wheelchair towards the Radiology room then; a radiograph was taken at the same sitting. The single film was taken to visualize the spill and free dispersion of contrast in the pelvic peritoneal cavity.

The film was evaluated and findings were noted. The single film radiograph of each client after processing was studied by the radiologist. All findings were noted for the radiological anatomy of the female genital system which included the size, shape, position of the uterus, patency of the fallopian tubes, and peritoneal spillage. The parameters like time conjunction and complications or side effects were noted as score rating by Marci R.¹⁴ Side effects were scored by the operator in consultation with the patient immediately after the completion of the examination.

Data was tabulated in the IBM SPSS statistics 20 software. Mean, standard deviation, Chi-square test and Multinomial logistic regression analysis were done in the statistical analysis, p-value ≤ 0.05 considered as significant level.

RESULTS

Out of 222, complete clinical SHSG procedure and HSG were done in 220 cases during their proliferative phase of the menstrual cycle preferably 7th to 10th day. Among the 222 women, Only SHSG examination done in 220 patients 2 had termination of the examination.

Out of 220 women under evaluation, 159(72.3%), 61 (27.7%) were primary infertility and secondary infertility respectively. The age ranges from 17-40 years. The mean age was 26.18±4.51 (Figure: 1). The common age group was 20-25 and 25-30 years of age. The mean duration of infertility was 5.90±4.19years.

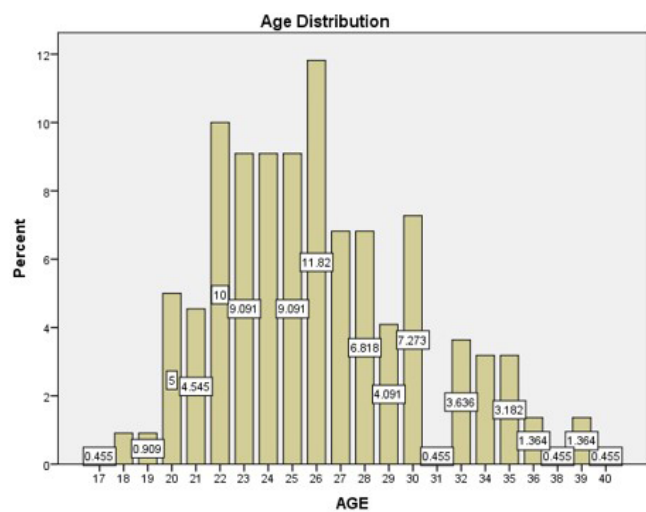


Figure 1: Age Distribution

In the present study, the clinical pathologies like polycystic ovaries (PCOD) in 33(15%), Fibroid uterus 11(5%), Ovarian cyst 5(2%), Endometriosis/Endometriotic with Hydrosalpinx 8(4%) were the most common findings on SHSG. Endometrial polyps were observed in 2(1%) cases. Normal pelvic organs were found in 161(73%) of the cases (Table 1).

Table 1: Frequency distribution of pathology identified by SHSG

| Findings | n (%) | p-value |
|---|---------|---------|
| Normal uterus & Ovaries | 161(73) | 0.9 |
| PCOD | 33(15) | |
| Ovarian Cyst | 5(2) | |
| Fibroid Uterus | 11(5) | |
| Endometrial polyps | 2(1) | |
| Pelvic Endometriotic cyst with Hydrosalpinx | 8(4) | |
| Total | 220 | |

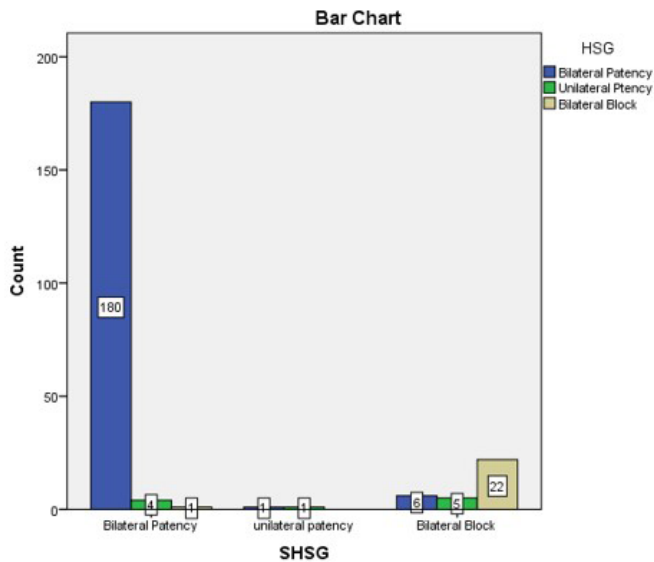


Figure 2: Distribution of SHSG findings and HSG Findings.

Table 2: Effect on SHSG by HSG

| Parameter Estimates | | | | | | | | | |
|---------------------|-----------|----------------|------------|--------|----|------|------------|------------------------------------|-------------|
| SHSG ^a | | B | Std. Error | Wald | Df | Sig. | Exp(B) | 95% Confidence Interval for Exp(B) | |
| | | | | | | | | Lower Bound | Upper Bound |
| Bilateral Patency | Intercept | -3.966 | 1.543 | 6.602 | 1 | .010 | | | |
| | [HSG=1] | 6.751 | 1.575 | 18.375 | 1 | .000 | 854.962 | 39.028 | 18729.269 |
| | [HSG=2] | 1.304 | 4.451 | .086 | 1 | .770 | 3.684 | .001 | 22632.721 |
| | [HSG=3] | 0 ^b | . | . | 0 | . | . | . | . |
| Unilateral patency | Intercept | -9.422 | 23.405 | .162 | 1 | .687 | | | |
| | [HSG=1] | 7.099 | 23.427 | .092 | 1 | .762 | 1210.914 | 1.387E-017 | 1057060.000 |
| | [HSG=2] | 11.755 | 23.431 | .252 | 1 | .616 | 127362.037 | 1.446E-015 | 1121634.000 |
| | [HSG=3] | 0 ^b | . | . | 0 | . | . | . | . |

a. The reference category is: Bilateral Block. b. This parameter is set to zero because it is redundant.
 Bilateral patency (HSG=1); Unilateral patency (HSG=2); Bilateral Block (HSG=3).

Table 3: Classification table of the combined effect of SHSG and HSG

| Observed | Predicted | | | Percent Correct |
|--------------------|-------------------|--------------------|-----------------|-----------------|
| | Bilateral Patency | Unilateral patency | Bilateral Block | |
| Bilateral Patency | 180 | 4 | 1 | 97.3% |
| unilateral patency | 1 | 1 | 0 | 50.0% |
| Bilateral Block | 6 | 5 | 22 | 66.7% |
| Overall Percentage | 85.0% | 4.5% | 10.5% | 92.3% |

Table 4: Procedural Complications after SHSG

| Symptoms | Frequency(%) | p-value |
|--|--------------|---------|
| No pain and discomfort | 69(31.1) | 2.0 |
| Mild pain an mild discomfort | 125(56.3) | |
| Moderate pain and no vaso-vagal | 21(9.5) | |
| Vaso-vagal pain need to observe in dept | 5(2.3) | |
| Severe vaso-vagal symptoms needs resuscitation | 2(0.9) | |
| Total | 222(100) | |

SHSG found Bilateral Patency 180(81.80%), Bilateral Block 22(10%) latter on findings conformed by HSG (Figure 2).

Multinomial logistic regression Analysis yields the following results:

There was a significant correlation between SHSG and HSG at the p-value 0.01 level. The Correlation Coefficient of 0.820 finding showed well fit in the Multinomial logistic regression analysis model. The cox and snell pseudo-R-Square 0.259, Nagelkerke (0.423) showed perfect as well as adequate variation. There was significant input of HSG finding (HSG 1) over SHSG finding in bilateral patency B= 6.751, p-value <0.0001 (Table 2).

The predicted classification of combined effect for bilateral patency was (97.3%), Unilateral Patency (50%), Bilateral Block (66.7%) respectively. The Overall classification percentage was 92.3% which was adequately classified.

In the present study, no pain no side effects which occurred in 69 (31.1%) out of 222 women. Moderate pain occurred during distension of the uterine cavity in 21(9.5%) patients. In 5 (2.3%) patients, symptoms related to vagal stimulation that occurred during the procedure need to observe in the department (Table 4). The most frequent side effects were mild pain and mild discomfort 125(56.3%). Vasovagal pain and severe vasovagal symptoms observed in two patients so the examination was terminated for this reason. The clinical pregnancy rate was 16(7.8%).

DISCUSSION

All mothers from the study group underwent both Sonohysterosalpingography(SHSG) first then HSG in a single sitting at 7-10 days of their menstrual cycle. In the present study, the first procedure SHSG identified different five pathologies. PCOD was seen in 15% of the cases. Likewise, 5% were Fibroid uterus, 2% had an ovarian cyst, Endometriotic cyst with Hydrosalpinx (Tube ovarian mass), 4% Endometrial polyps was observed in 2(1%) cases were the most common findings. Normal pelvic organs were found in 161(73%) of the cases. Patient characteristics were similar to study observed by Ludwin et al.¹⁵ Similar or very close diseases incidences rate were also found with the same study done among 132 cases. SHSG was able to detect endometrial polyp in 2 cases. The error rate detecting endometrial polyp by SHSG was found only in 3.7%.¹⁶ We did not find any cases of uterine anomalies.

The SHSG findings were confirmed later by HSG in 220 infertile women. SHSG and HSG showed bilateral patency 180 (81.80%) cases and bilateral block in 22(10%) cases respectively. SHSG showed bilateral block in 11 cases later HSG showed bilateral patency in 6 and unilateral patency in 5 cases.

A review study done by Uciano DE et al found that accuracy of contrast Sonohysterosalpingography for tubal patency was shown to be comparable with hysterosalpingography (HSG) when compared with laparoscopic chromopertubation. The sensitivity ranged from 75% to 96%, and specificity from 67% to 100%.¹⁷ Contrast Sonohysterosalpingography was also accurate when compared with HSG for determining tubal occlusion after hysteroscopic sterilization. Hence, the study agreed that the HSG as a standard diagnostic test and can be compared with other modalities of examination for the tubal patency test.

In our study, bilateral tubal occlusion was seen in 10% of the cases which was identified by SHSG and conformed by HSG. The little high incidence rate 13.29% was found by Covali et al.¹⁸ In our study, tubal patency was assessed first by SHSG which was later compared with HSG. About 180(81.80%), had bilateral tubal patency in SHSG and conformed the same number later by HSG. SHSG showed bilateral block in 33 (15%) whereas HSG conformed only in 22(10.9%). Unilateral patency and block was seen in 18(10.18%) only by HSG (Figure 2).

The similar accuracy rate of Contrast Sonohysterosalpingography was also found by Mandia et al in his study done among

patients with or without endometriosis.¹⁹ If tubal patency was not demonstrated by SHSG i.e. definite peritoneal spillage with waterfall sign, only less than 66% such tubes will be completely occluded at HSG. The low negative predictive value was a clear limitation of Sonohysterosalpingography. Several studies have demonstrated that Contrast Sonohysterosalpingography was superior to HSG in the study of the Pelvic, uterine and ovarian pathology a similar study done by Acholonu et al showed that sonohysterography was more sensitive 81.8% vs 58.2% and more specific 93.8% vs 25.6% than HSG.²⁰ The sensitivity of Sonohysterosalpingography(SHSG) had increased in our study compared to the study done by Acholonu et al. Whereas HSG was superior to SHSG in the diagnosis of tubal patency. The accuracy of Contrast Sonohysterosalpingography was also studied by Mandia et al among patient with or without endometriosis and findings of Contrast Sonohysterosalpingography was confirmed by Laparoscopy. The diagnostic accuracy of Contrast Sonohysterosalpingography was found 91% in the endometriosis group and 92% in the non-endometriosis patients.^{19,20}

SHSG showed bilateral tubal block in 6 cases later HSG showed bilateral patency. SHSG showed bilateral block in 5 cases later HSG showed unilateral patency. SHSG showed bilateral patency in 6 cases which were eventually diagnosed unilateral patency in 4 cases and bilateral block in 2 cases by HSG. Hence, HSG was more specific to SHSG in the evaluation of the fallopian tubes, especially with respect to tubal blocks. Panchal S et al¹³ mentioned that Tubal patency can be assessed far better with HSG than SHSG alone concerning to site and side. If we combine these two procedures SHSG and HSG the false positive and false negative results can be overcome.

A false-positive result of tubal occlusion can be obtained from SHSG due to immediate tubal spasm because of the transient distension of the uterine cavity described by Schankath et al.²¹ If the contrast fluid slowly infuses the rate of tubal spasm can be overcome. In our study, immediately after the SHSG procedure, there is a short time interval 3- 5minutes to carry the patient towards the radiograph table. So there is a natural delay to take a radiograph. This time is also useful to differentiate tubal spasm from a true tubal occlusion.

In SHSG, the adverse effect occurred in 12.7% cases (moderate to severe pain 9.5%, vasovagal symptoms in 3.2%) little higher incidence of moderate to severe pain but the more or less same incidence of vasovagal symptoms compared to the study done by Dessole et al, Bonnamy et al.^{22, 23} but extremely low incidence compared to study done by Marci et al reported as the aggregates adverse reaction 20.5% (Moderate pain 9.96%, Severe pain 6.48%, vasovagal reaction 4.11%).²⁴ In our study analgesia in injection was needed for moderate to severe pain. Resuscitation was necessary for two cases. Routine oral anti-spasmodic half an hour before the procedure may lower the risk of moderate pain.

If both procedures are concurrently done with simple modification combined procedure, which is expected superior in its diagnosis of pelvic, Uterine Ovarian and tubal pathology to evaluate infertile women. The predicted classification of

combined effect for bilateral patency was (97.3%), Unilateral Patency (50%), Bilateral Block (66.7%) respectively. The Overall classification percentage was 92.3% which was adequately classified.

The combined examination tests usually well-tolerated, causing mild pain and mild discomfort in most patients and No pain in a few. The pain is due to inflation of the balloon which stimulates the cervix to cause pain and vasovagal symptoms. In our experience aspiration of 1 ml, the saline solution from the balloon soon after SHSG the first procedure reduces the pain rather than the removal of the catheter before HSG snap which makes it difficult to tract the cervix during film reading.

The clinical pregnancy rate was 16(7.27.8%) within one year of the test Lo monte, et al also found the spontaneous pregnancy rate after evaluation.²⁵ But Lindbourg et al in their randomized control trial that an enhanced pregnancy rate after performing Sonohysterosalpingography (SHSG) could not be confirmed.²⁶

No superior radio imaging test is found till date then sonohysterosalpingography for the evaluation of female infertility. The study not only concentrated on the optimal use of newer technique/resources available in the present contest but also signify the importance of the conventional one which has still got a significant role. The study also provided a single frame test combined with SHSG and HSG in a single sitting, which synergizes the ultimate quality of the test. Technical variations could have influenced the detection rate.

CONCLUSION

The evaluation of uterus is best done by Sonohysterosalpingography concurrent with HSG in same sitting. Outcome of Sonohysterosalpingography (SHSG) test for tubal patency is significantly synergises by concurrent HSG. The combine test is best indicated if SHSG alone is not able to demonstrate the sign of tubal patency.

CONFLICT OF INTEREST: None

FINANCIAL DISCLOSURE: None

REFERENCES:

- Debnath J, Satija L, Sharma RK, Rastogi V, Singh H, Mohan R, Khanna SK. Transvaginal Saline Infusion Sonohysterography: Initial Results. *Medical Journal, Armed Forces India*. 2000;56(2):135-9. [\[DOI\]](#)
- Ryu J, Kim B, Lee J, Kim S, Lee SH. Comparison of Transvaginal Ultrasonography with Hysterosonography as a Screening Method in Patients with Abnormal Uterine Bleeding. *Korean Journal of Radiology*. 2004;5(1):39-46. [\[DOI\]](#)
- Milingos S, Kallipolitis G, Stefanidis K, Sklia J, Makris N, Loutradis D, Antsaklis A, Michalas S. Saline contrast hysterosonography in infertile patients and in women with abnormal uterine bleeding. *Eur J Gynaecol Oncol*. 2005; 26(5):564-7. [\[PMID\]](#)
- Yang T, Pandya A, Marcal L, et al. Sonohysterography: Principles, technique and role in diagnosis of endometrial pathology. *World Journal of Radiology*. 2013;5(3):81-7. [\[DOI\]](#)
- Sayasneh A, Ekechi C, Ferrara L, et al. The characteristic ultrasound features of specific types of ovarian pathology (Review). *International Journal of Oncology*. 2015;46(2):445-58. [\[DOI\]](#)
- Omari EA, Varghese T, Kliever MA. A Novel Saline Infusion Sonohysterography-Based Strain Imaging Approach for Evaluation of Uterine Abnormalities In Vivo: Preliminary Results. *Journal of Ultrasound in Medicine*. 2012 Apr;31(4):609-15. [\[DOI\]](#)
- Aslam M, Ijaz L, Tariq S, Shafqat K. Comparison of transvaginal sonography and saline contrast sonohysterography in women with abnormal uterine bleeding: correlation with hysteroscopy and histopathology. *International journal of health sciences*. 2007 Jan;1(1):17-24. [\[PMID\]](#)
- Karimzadeh MA, Firouzabadi RD, Goharad F. Diagnostic value of saline contrast sonohysterography comparing with hysteroscopy for detecting endometrial abnormalities in women with abnormal uterine bleeding. *Iranian journal of reproductive medicine*. 2011;9(3):199-202. [\[PMID\]](#)
- Phillips CH, Benson CB, Ginsburg ES, Frates MC. Comparison of uterine and tubal pathology identified by transvaginal sonography, hysterosalpingography, and hysteroscopy in female patients with infertility. *Fertility Research and Practice*. 2015;1:20. [\[DOI\]](#)
- Zafarani F, Ahmadi F. Evaluation of Intrauterine Structural Pathology by Three-Dimensional Sonohysterography Using An Extended Imaging Method. *International Journal of Fertility & Sterility*. 2013;7(1):1-6. [\[PMID\]](#)
- Rajesh H, Lim SL, Yu SL. Hysterosalpingo-foam sonography: patient selection and perspectives. *International Journal of Women's Health*. 2017;9:23-32. [\[DOI\]](#)
- Patil M. Assessing tubal damage. *Journal of Human Reproductive Sciences*. 2009;2(1):2-11. [\[DOI\]](#)
- Panchal S, Nagori C. Imaging techniques for assessment of tubal status. *Journal of Human Reproductive Sciences*. 2014;7(1):2-12. [\[DOI\]](#)
- Marci R, Marcucci I, Marcucci AA, et al. Hysterosalpingocontrast sonography (HyCoSy): evaluation of the pain perception, side effects and complications. *BMC Medical Imaging*. 2013;13:28. [\[DOI\]](#)
- Ludwin I, Ludwin A, Wiechec M, Nocun A, Basta P, Pitynski K. Accuracy of hysterosalpingo-foam sonography in comparison to hysterosalpingo-contrast sonography with air/saline and to laparoscopy with dye. *Hum Reprod*. 2017 Apr 1;32(4):758-69. [\[DOI\]](#)
- Radwan P, Radwan M, Kozarzewski M, Polac I, Wilczyński J. Evaluation of sonohysterography in detecting endometrial polyps – 241 cases followed with office hysteroscopies combined with histopathological examination. *Videosurgery and other Miniinvasive Techniques*. 2014;9(3):344-50. [\[DOI\]](#)
- Uciano DE, Exacoustos C, Luciano AA. ultrasonography for tubal patency. *J Minim Invasive Gynecol*. 2014 Nov-Dec;21(6):994-8. [\[DOI\]](#)
- Covali R. Correlation between the wide range of tubal pathology discovered by routine hysterosalpingography in a university hospital in Romania and the successful pregnancy rate. A cohort study. *J Med Life*. 2017 Oct-Dec;10(4):232-6. [\[PMID\]](#)
- Mandia L, Personeni C, Antonazzo P, Angileri SA, Pinto SA, Savasi V. Ultrasound in Infertility Setting: Optimal Strategy to Evaluate the Assessment of Tubal Patency. *Biomed Res Int*. 2017;2017:3205895. [\[DOI\]](#)
- Acholonu UC, Silberzweig J, Stein DE, Keltz M. Hysterosalpingography versus sonohysterography for uterine abnormalities. *JSLs*. 2011 Oct-Dec;15(4):471-4. [\[DOI\]](#)
- Schankath AC, Fasching N, Urech-Ruh C, Hohl MK, Kubik-Huch RA. Hysterosalpingography in the workup of female infertility: indications, technique and diagnostic findings. *Insights into Imaging*. 2012;3(5):475-83. [\[DOI\]](#)

22. Dessole S, Farina M, Rubattu G, Cosmi E, Ambrosini G, Nardelli GB. Side effects and complications of sonohysterosalpingography. *Fertility and sterility*. 2003 Sep 1;80(3):620-4. [\[DOI\]](#)
23. Bonnamy L, Marret H, Perrotin F, Body G, Berger C, Lansac J. Sonohysterography: a prospective survey of results and complications in 81 patients. *Eur J Obstet Gynecol Reprod Bio*. 2002;102:42–7. [\[DOI\]](#)
24. Marci R, Marcucci I, Marcucci AA, et al. Hysterosalpingocontrast sonography (HyCoSy): evaluation of the pain perception, side effects and complications. *BMC Medical Imaging*. 2013; 13:28. [\[DOI\]](#)
25. Lo Monte G, Capobianco G, Piva I, Caserta D, Dessole S, Marchi R. Hysterosalpingo contrast sonography (HyCoSy): let's make the point!. *Arch Gynecol Obstet*. 2015 Jan; 291(1):19-30. [\[DOI\]](#)
26. Lindbourg L, Thorburn J, Bergh C, Strandell A. Influence of HyCoSy on spontaneous pregnancy: a randomized controlled trial. *Hum Reprod*. 2009 May;24(5):1075-9. [\[DOI\]](#)