

**CASE REPORT****SOLITARY OSTEOCHONDROMA OF SCAPULA: A CASE REPORT**BD SHARMA¹ *, J SITAULA¹, A PRAJAPATI¹, AP REGMI¹¹ Department of Orthopaedics, Chitwan Medical College, Bharatpur-10, Chitwan, Nepal.***Correspondence to:** Dr Bishnu Dev Sharma, Department of Orthopaedics, Chitwan Medical College, Bharatpur-10, Chitwan, Nepal.
Email: bisnudev@gmail.com**ABSTRACT**

Osteochondromas are the most common benign tumours of bone. They are most commonly seen in the metaphyseal regions of long bones (femur, tibia, humerus). The scapula is rarely involved, and very few cases of solitary osteochondroma of scapula have been reported in literature. We present the case of a 17 year old male who presented with pain and limited range of motion of his right shoulder. CT scan revealed an osteochondroma on the dorsomedial surface of the right scapula extending into the ventral surface. Surgical excision was done and histopathological study showed osteochondroma of the scapula.

Key words: Osteochondroma, Scapula, Solidarity**INTRODUCTION**

Osteochondromas are the most common benign tumours of bone. They are the osteocartilaginous exostoses that account for 35% to 46% of all benign neoplasms of bone.¹ These lesions are thought to arise from aberrant growth of normal epiphyseal growth plate cartilage.² The lesions consist of a bony mass, often in the form of a stalk, produced by progressive endochondral ossification of a growing cartilaginous cap.³ Most lesions are found during the period of rapid skeletal growth and their growth usually ceases when skeletal maturity is reached.³

About 90% of patients have only a single lesion.³ Osteochondromas may occur on any bone preformed in cartilage, but usually are found on the metaphyseal regions of long bones such as distal femur, proximal tibia, or proximal humerus.³

These tumours usually cause no symptoms and are discovered incidentally. Some patients may present with pain due to mechanical pressure to surrounding structures, fracture of the bony stalk of the tumour, neurovascular impingement, bursa formation and rarely malignant transformation of the cartilaginous cap.

Literature on involvement of scapula is limited to isolated case reports.^{4, 5} Here we present the case of a solitary symptomatic osteochondroma arising from the dorsomedial surface of the scapula extending into the ventral surface in a young adult male treated with surgical excision.

CASE REPORT

A 17 year right handed male presented with pain on right shoulder since last 6 months. He had noticed a swelling over his right scapula 2 year back (Figure 1). During the last 4 months, progressive limitation of overhead activities had developed. There was no history of trauma, fever or weight loss. There was no significant family history.

On examination, a 5 X 5 cm spherical swelling was palpable along the medial border of the right scapula. The swelling was bony hard, smooth, non-tender with well-defined edges. The skin over the swelling was normal. The swelling was fixed to scapula but not-tethered to the overlying skin. A grating sensation was felt when the shoulder was abducted. Shoulder range of motion was comparable

to opposite (left) side. There was no winging of the scapula and no neurologic deficit. No other bony exostoses were noted in his body.

Plain radiograph showed a bony mass arising from the medial border of the scapula (Figure 2). CT scan revealed a mushroom shaped osteochondroma measuring 1.9 X 2.6 X 2.2 cm along the medial border of the blade of scapula with extension into the ventral surface (Figure 2). No associated soft tissue masses were noted. Pre-operative laboratory investigations were within normal limits.

Under general anaesthesia the patient was positioned prone. Incision was given over the mass parallel to the medial border of the right scapula. Dissection was carried out down to the level of the mass splitting the muscle fibers. The tumour was excised and the wound closed in layers under suction drain (Figure 3).

Resected specimen measured 5 X 5 cm with a cap of cartilage overlying the bony tissue. Microscopic sections showed cap of hyaline cartilage overlying trabeculae of lamellar bone. The cells did not show atypia. Findings were consistent with the diagnosis of osteochondroma.

The post-operative period was uneventful. An arm sling was applied for a week and the shoulder gently mobilized as was tolerable. No above shoulder exercises were permitted for 4 weeks postoperatively.

At 6 weeks follow-up the patient had regained a pain free full range of movement of shoulder and the operative scar had healed. At 6 months, the patient was asymptomatic with return to full sporting activities and there was no evidence of recurrence.

DISCUSSION

Osteochondromas have involved the scapula in 3.0-4.6% of all reported cases. They comprise 14.4% of all tumors of the scapula and 49% of benign scapular tumors.⁴ The ventral surface is involved most commonly, and isolated unilateral lesions predominate.^{4, 6}

The common presenting complaints⁶ of patients with an osteochondroma of the scapula include pain, decreased active range of motion, crepitus with movements of the involved shoulder and sometimes

“pseudowinging” of the scapula. A mass may or may not be palpable.

Plain radiograph reveals a bony mass arising from the scapula. CT scan can provide more detail regarding the location and size of the mass. Diagnosis is confirmed by histopathologic evaluation, which demonstrates enchondral or lamellar bone connected to normal bone by a thin stalk in continuity with the medullary canal of the native bone.⁷ Histologic specimens reveal a cartilage cap of varying thickness. A cartilaginous cap of more than 2 cm in thickness should raise concern for malignant transformation.⁸ Other complications include reactive bursa formation, pseudowinging of scapula, snapping scapula syndrome and restricted movements of the shoulder.

Surgical excision is the treatment of choice for symptomatic osteochondroma of the scapula and it is usually curative.⁹ Excision can be done by open surgery or by scapulothoracic arthroscopy.¹⁰ Overall prognosis following excision is good, although recurrence may occur if excision is incomplete.¹¹

CONCLUSION

Osteochondromas of scapula are rare benign bone tumours. They can present with pain, restricted shoulder range of motion and sometimes with pseudowinging of scapula. Surgical excision may provide an excellent clinical outcome, as evidenced by this patient.

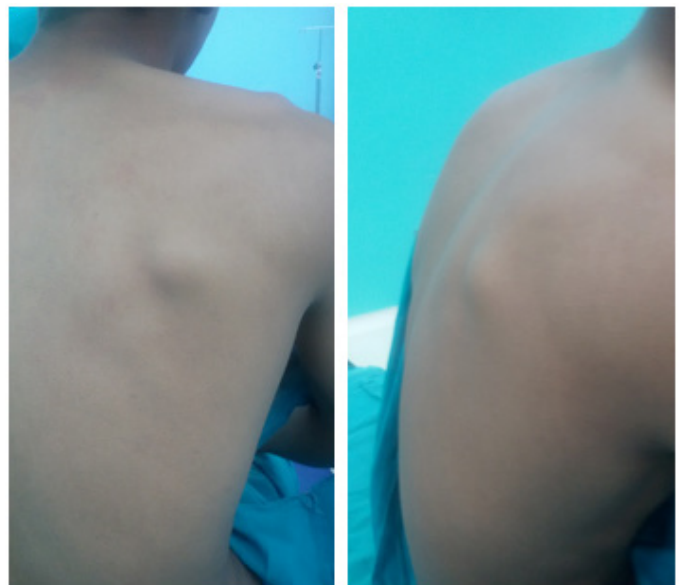

Figure 1: Clinical photo showing swelling arising from right scapula

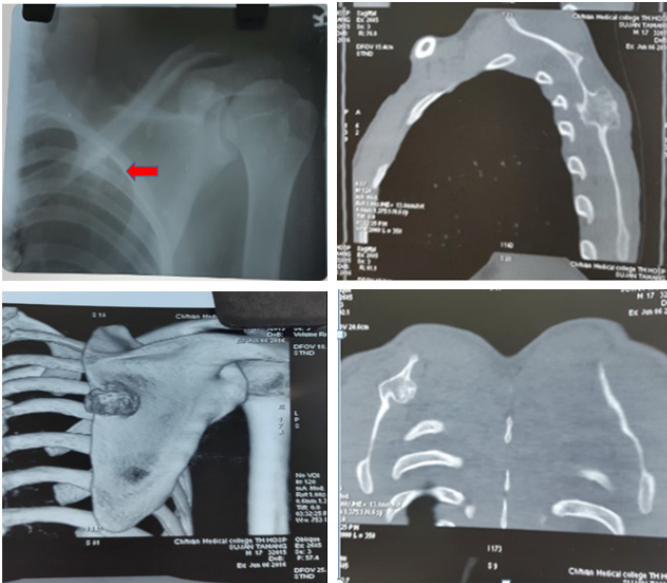


Figure 2: Plain radiograph and CT images

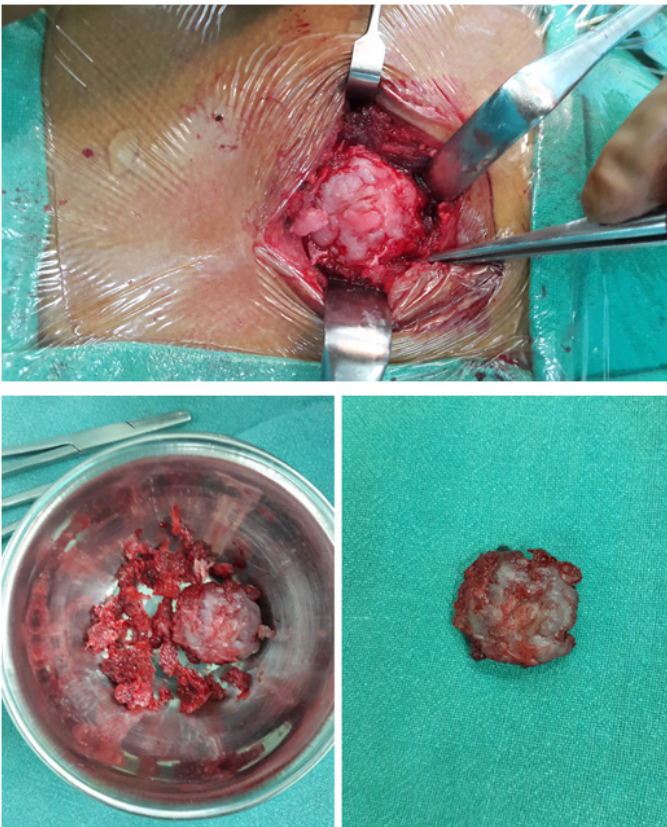


Figure 3: Intra-operative image of the tumour and the resected specimen

REFERENCES

1. Mohsen MS, Moosa NK, Kumar P. Osteochondroma of the scapula associated with winging and large bursa formation. *Med Princ Pract.* 2006;15(5):387-90.
2. Milgram JW. The origins of osteochondromas and enchondromas. A histopathologic study. *Clin Orthop Relat Res.* 1983;174(174):264-84.
3. Heck RK. Benign bone tumours and non neoplastic conditions simulating bone tumours. *Campbell orthopaedics.* 11 ed2007. p. 860.
4. Esenkaya I. Pseudowinging of the scapula due to subscapular osteochondroma. *Orthopedics.* 2005;28:171-2.
5. Danielsson LG, el-Haddad I. Winged scapula due to osteochondroma. Report of 3 children. *Acta Orthop Scand.* 1989;60(6):728-9.
6. Fageir MM, Edwards MR, Addison AK. The surgical management of osteochondroma on the ventral surface of the scapula. *J Pediatr Orthop B.* 2009;18(6):304-7.
7. Fukunaga S, Futani H, Yoshiya S. Endoscopically assisted resection of a scapular osteochondroma causing snapping scapula syndrome. *World J Surg Oncol.* 2007;5:37.
8. Malghem J, Berg BV, Noel H, Maldague B. Benign osteochondroma and exostosis chondrosarcomas: evaluation of cartilage cap thickness by ultrasound. *Skel Radiol.* 1992;21:33-7.
9. Khurana J, Abdul-Karim F, Bovée JVMG. Osteochondroma. In: Fletcher CDM, Unni KK, Mertens F, editors. *World Health Organization Classification of Tumours.* France: Lyon; 2002. p. 234-6.
10. Aalderink K, Wolf B. Scapular osteochondroma treated with arthroscopic excision using prone positioning. *Am J Orthop (Belle Mead NJ).* 2010;39(2):E11-4.
11. Krieg JC, Buckwalter JA, Peterson KK, el-Khoury GY, Robinson RA. Extensive growth of an osteochondroma in a skeletally mature patient. A case report. *J Bone Joint Surg Am.* 1995;77(2):269-73.