

CASE REPORT

SCALP SWELLING OF LONG DURATION

P Dahal^{1*}, SM Rai¹

¹Department of Surgery, Burns & Plastic Surgery Unit, National Academy of medical Sciences, Bir Hospital, Kathmandu.

*Correspondence to: Dr Peeyush Dahal, Department of Surgery, Burns & Plastic Surgery Unit, National Academy of medical Sciences, Bir Hospital, Kathmandu.

Email: peeyushdahal@gmail.com

ABSTRACT

Malignant tumors occurring in the scalp are uncommon. When scalp swellings are asymptomatic, small in size or covered by hair usually they are neglected by patients. This may lead to a potential risk of delay in detection and treatment which may cause poorer results. Here we are presenting the case of scalp swelling of unknown duration and pre-operative investigation had showed benign lesion and was managed accordingly but post operatively it was found malignant and metastasized rapidly and become incurable. So any unusual, ulcerated/pigmented lesion of the scalp we must consider the possibility of a tumor and reconstruction with flap should be done after confirmation of the diagnosis.

Key words: Scalp swelling, Scalp reconstruction, Skin tumor, Wide local excision.

INTRODUCTION

Approximately 2% of epithelial tumors of the skin are located on the scalp. Malignant tumors occurring in the scalp are not common. Basal cell carcinoma and squamous cell carcinoma are most frequent tumors accounting for more than 50% of scalp malignancies and other tumors are (follicular, sebaceous, eccrine and apocrine differentiation), tumours of soft tissue (angiosarcoma, Dermatofibrosarcoma protuberans, leiomyosarcoma) and lymphoma are found less frequent. Extraocular sebaceous carcinomas are even rarer, accounting for only 25% of the total number of sebaceous carcinomas reported in the head and neck. Tumours arising from the outer root sheath of hair follicles comprises of 0.1 % of skin tumors.⁴

Pilar tumor is a rare neoplasm arising from the external root sheath of the hair follicle and are observed most commonly on the scalp and clinically present as irregularly defined subcutaneous nodules, which are often cystic and characterized by trichilemmal keratinization.

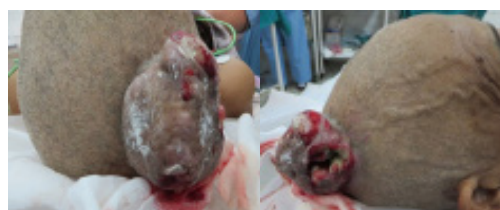These tumors have been reported with varying nomenclature, e.g., proliferating epidermoid cyst, invasive pilomatrixinoma, trichoclamydocarcinoma, trichilemmal pilar tumor, and proliferating pilar

tumor.

When scalp swellings are asymptomatic, small in size or covered by hair usually they are neglected by patients. Here we are presenting the similar case of scalp swelling of unknown duration and neglected for years.

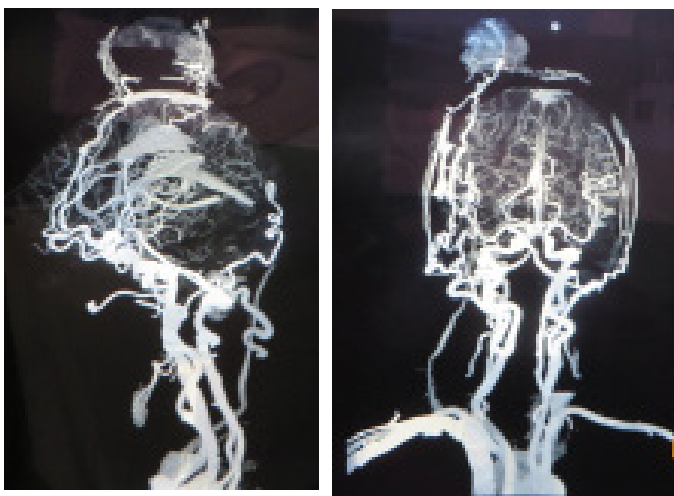
Case report

A 72 years old lady from eastern part of Nepal presented with a large globular ulcerated swelling with cavities seen on lateral aspect of swelling over right Parietal region since adulthood but she do not know the exact duration. It was painless and was covered by hair during her adulthood. The swelling had become prominent during the fifth decade of life. Ulcer was developed 6 months back and onset of pain and bleeding from the wound site since three month duration which compelled her to seek medical attention.



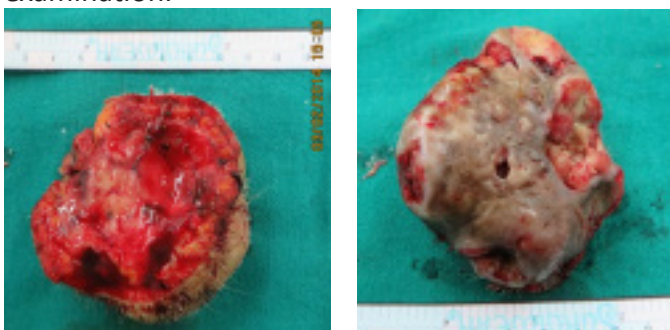
Swelling at the time of presentation

She had visited some hospitals and in one fine needle aspiration cytology examination was done and report was inflamed keratin cyst. We did the CT plain, contrast and CT angio of the head. The radiological findings were heterogeneously enhancing lobulated exophytic scalp mass in right parietal region with internal coarse calcifications and enhancing septations suggesting scalp hemangioma with arterial supply from bilateral superficial temporal artery and right occipital arteries and early venous drainage from right retromandibular and right external jugular veins.



CT angio of the patient

Total excision of swelling was performed the mass was found up to bone and there was a large defect which was covered immediately with local scalp flap. The specimen was sent for histopathological examination.



Excised specimen

The histological features of biopsy were consistent with malignant tumor. The deeper margin and two of the margin were positive for malignant cells. The type of the tumor was not ascertained and immunohistochemistry for Cytokeratin, Vimetin, SMA and CD 31 was suggested to assert the

histogenesis of the tumor. This service was not available in Nepal and was sent to India but the specimen was misplaced for two weeks and patient presented with multiple nodular swelling in the scalp, neck which was positive for tumor cell on FNAC. Then patient lost for follow up.

DISCUSSION

Tumours arising from the outer root sheath of hair follicles comprises of 0.1 % of skin tumors, Saida et al. in 1983 defined three stages of trichilemmal tumors - trichilemmal cyst, (adenomatous stage); proliferating trichilemmal tumor, (epitheliomatous stage) and malignant proliferating trichilemmal tumour, (carcinomatous stage) ^{1,2}. These tumors usually occurring in the scalp of elderly women and show characteristic trichilemmal keratinisation. A trichilemmal cyst is by far the most common of these³.

Primary adenoid cystic carcinoma (PACC) is a rare entity characterized by an indolent but progressive course. It has tendency to recur locally, and rare nodal metastatic spread. PACC exhibit aggressive infiltrative growth in the reticular dermis and subcutis which may be the reason for local recurrence and regional spread. Kato et al has mentioned that this tumor most commonly arises in the sixth and seventh decades of life and average duration of tumor prior to diagnosis is 9.8 years with a tumor size ranging from 0.5 to 8 cm. ⁴ The primary modality of management is wide local excision with tumor free margin.⁵ But in our case we reconstruct the defect without confirming the tumor free margin so the early recurrence might have occurred.

SC is most commonly seen in the orbital region, extra orbital SC is very rare. So far only 150 cases of extra orbital SC were reported in the literature^{6,7}. The clinical behavior and characteristics are still a matter of controversy in the literature.⁸ Extra ocular SC is known to recur locally and spread to lymph nodes and visceral organs.⁹ A sebaceous carcinoma is a rare, aggressivetumour which provides a diagnostic dilemma as in our case for many physicians and surgeons. Diagnosis is only achieved histopathological examination.

Eccrine Porocarcinoma is a rare neoplasm arising from sweat gland. It originates from intraepidermal

and upper dermal eccrine ducts. It is commonly found in old people and usually having clinical findings of long duration of occurrence of a verrucous plaque, polypoid growth or an ulcerative lesion. There may be local recurrence and metastasis to skin, lymph nodes, viscera, and bone. But in our case there was no verrucous plaque polypoid growth and we could not perform the immunohistochemistry examination.

CONCLUSION

When scalp swellings are asymptomatic, small in size or covered by hair usually they are neglected by patients and delay in seeking prompt medical attention. This may lead to a potential risk of delay in detection and treatment which may cause poorer results. Scalp swelling of long duration may provide a diagnostic dilemma. Any unusual, ulcerated/pigmented lesion of the scalp we must consider the possibility of a tumor and reconstruction with flap should be done after confirmation of the diagnosis.

REFERENCES

1. Ye J, Nappi O, Swanson PE, Patterson JW, Wick MR. Proliferating pilar tumors: A clinicopathologic study of 76 cases with a proposal for definition of benign and malignant variants. *Am J Clin Pathol* 2004;122(4):566–74.
2. Siddha M, Budrukkar A, Shet T, Deshpande M, Basu A, Patil N et al. Malignant pilar tumor of the scalp: A case report and review of literature. *J Cancer Res Ther* 2007;3:240–3.
3. Saida T, Oohara K, Hori Y, Tsuchiya S. Development of a malignant proliferating trichilemmal cyst in a patient with multiple trichilemmal cysts. *Dermatologica* 1983;166:203–8.
4. Naylor E, Sarkar P, Perlis CS, Giri D, Gnepp DR, Robinson-Bostom L. Primary cutaneous adenoid cystic carcinoma. *J Am Acad Dermatol* 2008;58:36–41.
5. Krishnamurthy A, Vaidhyanathan A. Primary cutaneous adenoid cystic carcinoma of scalp. *International Journal of Head and Neck Surgery*. 2010;1(3):179–181.
6. Duman DG, Ceyhan BB, Celikel T et al. Extraorbital sebaceous carcinoma with rapidly developing visceral metastasis. *Dermatol Surg* 2003 Sep; 29(9):987–9.
7. Pickford MA, Hogg FJ, Fallowfield ME et al: Sebaceous carcinoma of the periorbital and extraorbital regions. *Br J Plast Surg* 1995 Mar; 48(2):93–6.
8. Bassetto F, Baraziol R, Sottosanti MV et al. Biological behaviour of the sebaceous carcinoma of the head. *Dermatol Surg* 2004 Mar; 30(3):472–6.
9. Verlooy H, Mortelmans L, Schiepers C et al: A rare case of sebaceous carcinoma with very malignant characteristics. *Clin Nucl Med* 1993 May;18(5):425–7.
10. Roshani E, Rana, Sachin S, Verma, Vinita A, Puri, Amresh S, Baliarsing. Sweat gland tumor (Eccrine Porocarcinoma) of scalp: A rare Tumor. *Indian J Plast Surg* January–June 2005; Vol 38 Issue 1:50–53.