

## CASE REPORT

### OPTIC DISC DRUSEN PRESENTING AS PAPILLEDEMA: A CASE REPORT

S Sitaula<sup>1</sup>, M Thapa<sup>1</sup>, AK Sharma<sup>1</sup>

<sup>1</sup> Department of Ophthalmology, Maharajgunj Medical Campus, Institute of Medicine, Tribuvan University, Kathmandu, Nepal.

\*Correspondence to : Dr Sanjeeta Sitaula, Lecturer, Department of Ophthalmology, Maharajgunj Medical Campus, Institute of Medicine, Tribuvan University, Kathmandu, Nepal.

Email: sanjeeta8272@gmail.com

#### ABSTRACT

Optic disc drusen, which are congenital anomalies of optic nerve head, are depositions of mucopolysaccharides and proteinaceous material within the optic nerve head. They are usually bilateral and diagnosed incidentally during routine fundus examination where they may be mistaken for papilledema. We report a case of 63 year old female referred to the neuro-ophthalmology department with the clinical suspicion of disc edema. Simple noninvasive investigations like ultrasound B-scan, fundus autofluorescence along with the newer test like spectral domain optical coherence tomography helped us to diagnose it as a case of pseudopapilledema, as optic disc drusen. Thus, a high index of suspicion along with the ancillary tests is helpful in differentiating optic disc drusen from true papilledema.

**Key Words:** *Autofluorescence, Optic disc drusen, Papilledema.*

#### INTRODUCTION

Optic disc drusen (ODD) are depositions of mucopolysaccharides and proteinaceous material that accumulate anterior to the lamina cribrosa within the optic nerve head causing pseudopapilledema. Anomalous optic disc elevation (pseudopapilledema) may be confused with true optic disc swelling and therefore represents a primary diagnostic consideration in the patient referred for papilledema. Many patients with pseudopapilledema go through unnecessary neuroimaging, lumbar puncture and other extensive laboratory studies. Several tests such as red-free fundus photography, ophthalmic ultrasonography (USG), computed tomography (CT) and optical coherence tomography (OCT) help to diagnose ODD. Hence awareness of this clinical entity can help to alleviate anxiety as well as reduce unnecessary and invasive procedures.

#### CASE REPORT

A 63 year old female presented to Out-Patient Department with history of painless progressive diminution of vision of both eyes for last three years. She was a known hypertensive under anti-hypertensive medications.

Ocular examination demonstrated best corrected visual acuity of 6/18 and 6/9 in right and left eye respectively. Anterior segment and pupil examination was normal. There was grade 3 and 2 nuclear sclerosis in right and left eye respectively. Right eye vitreous showed dense asteroid hyalosis. Both the discs had elevated irregular margins, fluffy contour and obliterated cup disc ratio. The peripapillary vessels were tortuous. Color vision was normal. Goldman visual field showed bilateral enlarged blind spots with constriction of the peripheral visual fields. The patient was referred to neuro-ophthalmology clinic with

suspicion of papilledema.

Neurological evaluation did not reveal any significant finding. Ultrasound B-scan showed calcification of the optic disc. Red free fundus photograph demonstrated auto-fluorescence of the optic disc. Further spectral domain optical coherence tomography (SD-OCT) confirmed the findings.

#### DISCUSSION

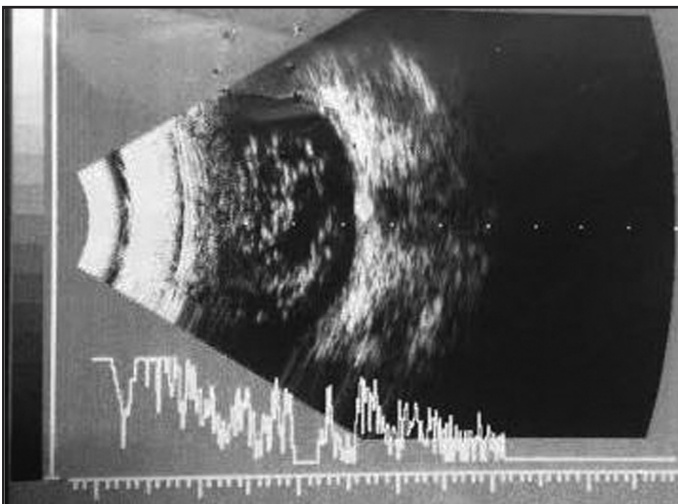
The word 'drusen' originally meant tumor, swelling, or tumescence. Drusen of the optic disc was first described by Liebreich in 1868. Other terms for these lesions include hyaline bodies and colloid bodies of the optic disc. Optic disc drusen are found in approximately 0.3-2% of the general population,<sup>1</sup> with bilateral distribution in 66-85%<sup>1-3</sup> and no sex predilection.<sup>2</sup> The primary pathology appears to be inherited dysplasia of the optic canal, or the optic disc and its vasculature, which predisposes axoplasmic transport stasis secondary to congenitally crowded optic nerve heads.<sup>4</sup> However some authors believe these depositions occur as a result of axonal degeneration of the optic nerve.<sup>5</sup> Optic disc drusen are more common in Caucasian patients.<sup>3</sup> It may be familial in some cases where it is inherited in an autosomal dominant pattern with incomplete penetrance.<sup>6,7</sup>

The ophthalmoscopic appearance of the disc drusen depends on whether it is buried or superficial. Superficial drusen are yellowish white, globular, irregular excrescences that vary in size from minute dots to larger granules within the disc. Buried disc drusen have moderate disc elevation along with blurring of margins, however the disc is not hyperemic and the peripapillary nerve fibre layer is normal. The physiological cup is obliterated and often there is anomalous vascular pattern on the disc surface,

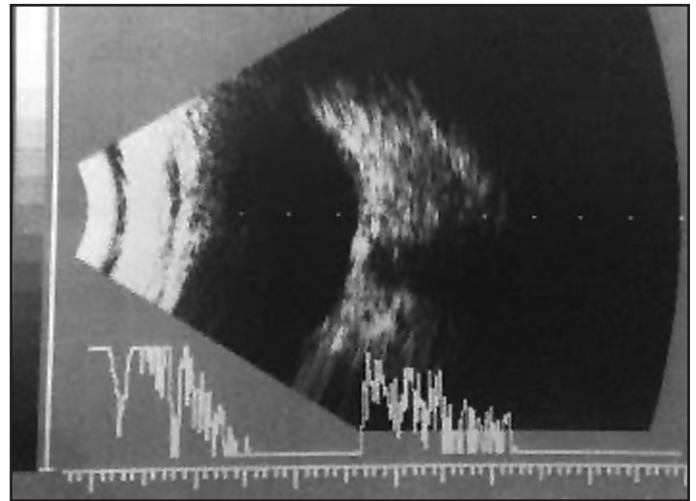
including an increased number of otherwise normal vessels, abnormal arterial and venous branching, increased tortuosity, vascular loops, and cilioretinal arteries. In children, disc drusen tend to be buried, whereas in adults, they are often visible on the disc surface, since the evolution of disc drusen is a dynamic process and continues throughout life.

Patients with optic disc drusen are generally asymptomatic, although rarely a patient may experience transient visual obscuration.<sup>8</sup> Although patients are unaware of the visual field deficits, visual field defects are found in 21% of eyes with pseudopapilledema without visible drusen, and 71% of eyes with visible drusen.<sup>9</sup> The most common visual field defects in ODD are inferior nerve fiber bundle defects, enlargement of the blind spot, and generalized constriction.<sup>10</sup> Often buried disc drusens may be mistakenly diagnosed as disc edema, especially in bilateral cases. Certain clinical signs and ancillary tests can be helpful. The presence of peripapillary nerve fibre layer edema, hyperemia of optic disc and venous congestion and absence of spontaneous venous pulsation indicate papilledema. Besides, signs and symptoms of raised intracranial pressure are also present in patients with papilledema.

Other ancillary tests like ultrasonography B scan, CT scan, fundus photography in red-free light, fluorescein angiography and optical coherence tomography (OCT) can aid in detection of disc drusen. In our patient, in ultrasonography B-scan of the posterior segment, we could see echodense structure with acoustic shadowing at the level of optic nerve head of both eyes suggestive of calcified disc drusen (Figure 1 and 2). There were hyperechoic dots scattered around the entire vitreous of right eye corresponding to the clinically visible asteroid hyalosis (Figure 1).

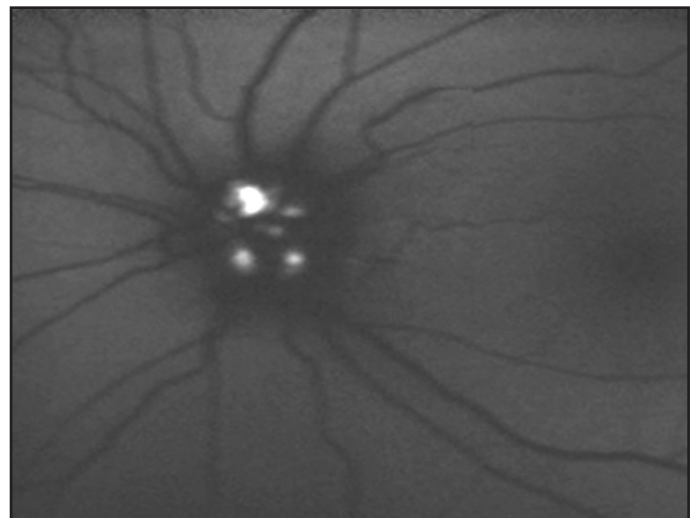


**Figure 1: USG scan Right eye**



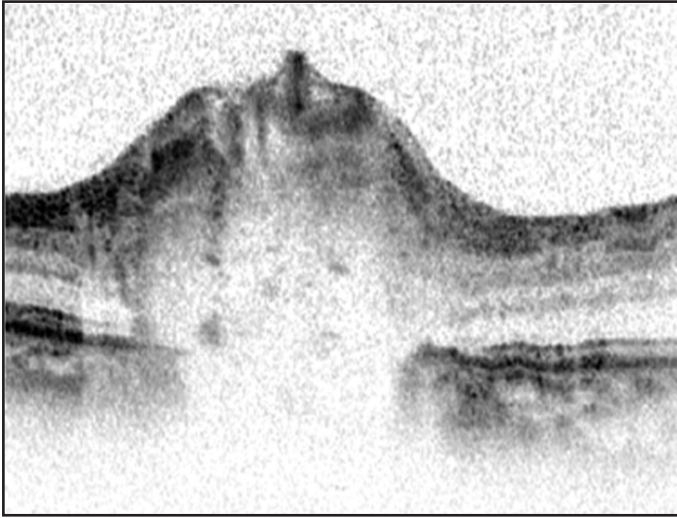
**Figure 2: USG scan Left eye**

Drusens are highly auto-fluorescent and show up as bright regions on the optic disc even without fluorescein dye especially in red-free light. During fundus fluorescein angiography, drusens show well-defined, uneven hyper-fluorescence, especially in the late phase without leakage of dye. This can be helpful in differentiating optic disc drusen from true papilledema, with the former showing only scarce teleangiectatic vessels.<sup>1</sup> We could obtain a fundus photograph of the left eye only because the right eye had hazy media due to the presence of cataract and asteroid hyalosis. In the fundus photograph of the left eye we can see auto-fluorescence in red free light (Figure 3).



**Figure 3: Red-free fundus photograph of left eye showing autofluorescence**

SD-OCT by its ability to acquire 100 times more number of A-scans as compared to Stratus OCT provides high resolution images of the cross section of the optic nerve head, a close approximation to the histo-pathological section.<sup>11</sup> The 3-dimensional SD-OCT image of our patient demonstrated the irregular contour of the optic nerve head with maximum thickness of 710 $\mu$ m. There was variable amount of thickening and displacement of the nerve fibre layer with underlying lucency. There was disorganization of the adjacent retinal pigment epithelium.



**Figure 4: SD-OCT image of left optic disc drusen**

There is no effective treatment for ODD. Occasionally ODDs become symptomatic due to either insidious field loss or spontaneous hemorrhage, at times associated with choroidal neovascular membrane formation, hence periodic follow up is necessary.

To conclude, a high index of suspicion along with careful observation of the optic disc is helpful in differentiating optic disc drusen from true papilledema along with noninvasive investigations like red-free fundus photography, ultrasound B-scan and OCT.

## REFERENCES

1. Auw-Haedrich C, Staubach F, Witschel H. Optic disc drusen. *Survey of ophthalmology*. 2002;47(6):515-32.
2. Rosenberg MA, Savino PJ, Glaser JS. A clinical analysis of pseudopapilledema. Population, laterality, acuity, refractive error, ophthalmoscopic characteristics, and coincident disease. *Archives of ophthalmology*. 1979;97(1):65-70.
3. Lorentzen SE. Drusen of the optic disk. A clinical and genetic study. *Acta ophthalmologica*. 1966;Suppl 90:1-180.
4. Spencer WH. XXXIV Edward Jackson Memorial Lecture: drusen of the optic disc and aberrant axoplasmic transport. *Ophthalmology*. 1978;85(1):21-38.
5. Wilkins JM, Pomeranz HD. Visual manifestations of visible and buried optic disc drusen. *Journal of neuro-ophthalmology : the official journal of the North American Neuro-Ophthalmology Society*. 2004;24(2):125-9.
6. Lorentzen SE. Drusen of the optic disk, an irregularly dominant hereditary affection. *Acta ophthalmologica*. 1961;39:626-43.
7. Antcliff RJ, Spalton DJ. Are optic disc drusen inherited? *Ophthalmology*. 1999;106(7):1278-81.
8. Lorentzen SE. Optic disc drusen. *Acta ophthalmologica*. 1983;61(2):335-6.
9. Savino PJ, Glaser JS, Rosenberg MA. A clinical analysis of pseudopapilledema. II. Visual field defects. *Archives of ophthalmology*. 1979;97(1):71-5.
10. Lee AG, Zimmerman MB. The rate of visual field loss in optic nerve head drusen. *American journal of ophthalmology*. 2005;139(6):1062-6.
11. Choi SS, Zawadzki RJ, Keltner JL, Werner JS. Changes in cellular structures revealed by ultra-high resolution retinal imaging in optic neuropathies. *Investigative ophthalmology & visual science*. 2008;49(5):2103-19.