

Dengue Fever Presenting as Acute Pancreatitis: A Case Series.

Kishor Khanal, Saroj Poudel, Anup Ghimire, Ashim Regmi, Rashmita Bhattarai, Aakash Pandey

Nepal Medicit Hospital, Bhaisepati, Lalitpur, Nepal

Keywords: Dengue fever, Acute Pancreatitis, Dengue hemorrhagic fever, Dengue shock syndrome



This work is licensed under a Creative Commons Attribution 4.0 Unported License.

Abstract

Acute pancreatitis (AP) is a rare complication of Dengue fever with unpredictable progression and outcome. There have been increasing reports of acute pancreatitis due to dengue. Fever, abdominal pain or tenderness are the presenting clinical manifestations on hospital admission. We reported two similar cases of Dengue who presented with the complaints of fever, abdominal pain, and generalized body ache. Acute pancreatitis was diagnosed in both cases following blood investigations, ultrasound and contrast enhanced computed tomography (CECT) of the whole abdomen.

Introduction

Dengue is a common viral infection seen in tropical areas. It is caused by the dengue virus belonging to the Flavivirus genus. Dengue virus has four serotypes, and it spreads through mosquito bites (*Aedes aegypti* and *albopictus*). Dengue infection has a wide spectrum of clinical manifestations with multi-organ involvement. The prognosis ultimately depends upon the number of organs involved. Dengue hemorrhagic fever (DHF) and dengue shock syndrome (DSS) are the most severe manifestations of Dengue, which carry high mortality rates. Acute pancreatitis, however, is an uncommon consequence of dengue fever and is mostly associated with severe dengue. [1-2]

*Corresponding Author:

Dr. Kishor Khanal

Nepal Medicit Hospital, Bhaisepati, Lalitpur, Nepal

Email: kishorkhanal01@gmail.com

Case Presentation

Case-I

A 51-year-old, non-alcoholic male was admitted with the complaints of high-grade fever associated with loose motion and generalized body ache. The patient had leucopenia with total leukocyte counts (TLC) of 1270 cells/cc, platelets of 20,000 cells/cc, hemoglobin of 15.7 gm %, and hematocrit 48.8%. Liver function tests were deranged. Further evaluation of the patient for tropical infections revealed Dengue to be positive (NS1 positive, IgG/IgM negative). Procalcitonin was also high (53.55 ng/ml).

On the third day of admission, the patient complained of abdominal pain. Abdominal examination revealed tenderness and guarding in the epigastrium with no rebound tenderness. Serum lipase and amylase were elevated to 1020 and 188 units/dl respectively, with normal lipid profile. Abdominal ultrasound revealed bulky pancreas with bilateral pleural effusion with minimal perihepatic and peri splenic collection with absence of gall stone (figure 1). A diagnosis of Acute Pancreatitis was made and the patient was managed conservatively. Empirical broad-spectrum antibiotics were started with intravenous Imipenem/Cilastatin and Metronidazole to cover secondary bacterial infections.

The patient was kept nil by mouth and was treated with intravenous fluids and antibiotics, and analgesics. The patient received two units of platelet concentrate due to thrombocytopenia. During the course of ICU stay, the patient improved gradually with increase in platelets counts, decrease in liver enzymes and resolution of abdominal pain. He was discharged in stable condition after 10 days of ICU admission.

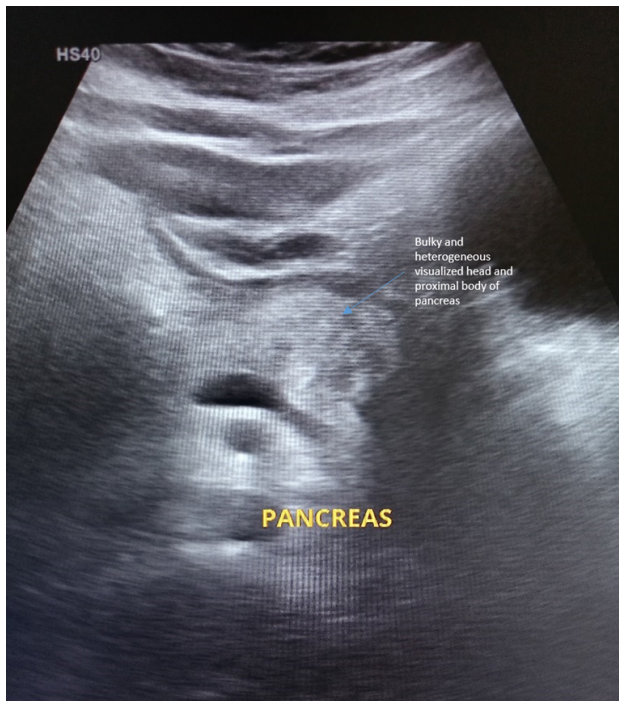

Figure 1. Ultrasound shows Bulky and heterogeneous visualized head and proximal body of the pancreas.

Investigation

Blood and Urine cultures were negative.

Table 1: Laboratory results

Investigations/Date	Total Leucocytes Counts	Hemoglobin (gms%)	Platelets (cells/cc)	Hematocrits (PCV) %	Liver Function Test (U/L)
13/09/2022	1270	15.7	20,000	48.8	AST: 468 ALT: 270
14/09/2022	6100	13.9	20,000	38.6	AST: 1003 ALT: 384
15/09/2022	16350	10.2	30,000	30.4	AST: 866 ALT: 333
16/09/2022	24,440	10.4	45,000	31.0	AST: 751 ALT: 412
17/09/2022	28,140	11.2	48,000	33.1	AST: 483 ALT: 330
18/09/2022	15690	10.4	30,000	31.0	AST: 221 ALT:232
19/09/2022	12180	10.7	63,000	32.1	AST:123 ALT:174
20/09/2022	12240	10.9	90,000	33.0	
21/09/2022	10050	11.0	120000	33.0	AST:98 ALT:64

Case II

A 25-year-old non-alcoholic, male was admitted with the complaints of high-grade fever associated with headache and vomiting. He was put on continuous intravenous fluid, due to severe vomiting. Investigations were carried out to rule out tropical diseases. He tested positive for dengue infection (NS1 positive).

On the fourth day of his admission, he developed abdominal pain, mainly in the epigastric region. The pain was severe in intensity and radiated to the back. It was associated with vomiting, which was non-bilious and non-projectile in nature. The patient had a total leukocyte count (TLC) of 10520 cells/cc, platelets of 30000, hemoglobin of 7.3 gm % and hematocrit of 40.8%. Liver function test (AST:135/ALT:49/Alkaline Phosphatase:133, Total bilirubin 5.3). His procalcitonin was high (1.72ng/ml).

Due to persistent abdominal pain, USG abdomen and pelvis were done which revealed bulky and heterogeneous pancreas with peripancreatic collection and absence of gallstones. Serum lipase and amylase showed elevated levels, 218 and 803 units/dl respectively. A diagnosis of acute pancreatitis was made and the patient was managed with intravenous fluids and broad-spectrum antibiotics.

The CECT abdomen was performed on the seventh day of his ICU admission due to abdominal distension and pain, and shows the features of acute necrotizing pancreatitis with a moderate ascites. Therefore, Pigtail insertion was performed and ascitic fluid was sent for culture. Culture sensitivity revealed no growth. Pleural fluid tapping was done for bilateral pleural effusion and pleural fluid was sent for culture revealed no growth. Potassium replacement was done for hypokalemia management. During the course of ICU stay, the patient improved gradually with increase in platelets counts, decrease in liver enzymes. He was discharged in stable condition after 10 days of ICU admission.

Investigation

Contrast-enhanced computed tomography (CECT) of abdomen revealed collection of peripancreatic fluid in peri gastric and peripancreatic region with mild to moderate ascites (figure 2, 3).

These features suggest acute necrotizing pancreatitis with CTSI score of (10/10).

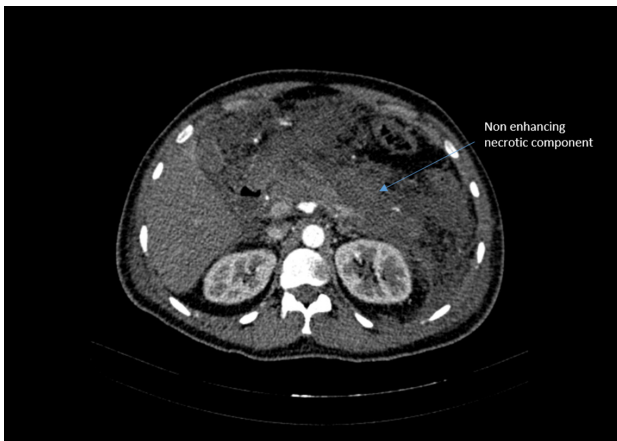


Figure 2: CECT Abdomen in arterial phase showing non enhancing hypodense area replacing body and tail of pancreas with minimal peripancreatic fluid.

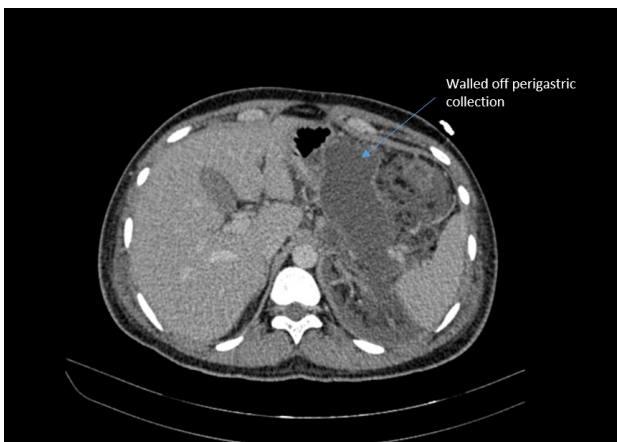


Figure 3: CECT Abdomen showing perigastric collection secondary to Pancreatitis

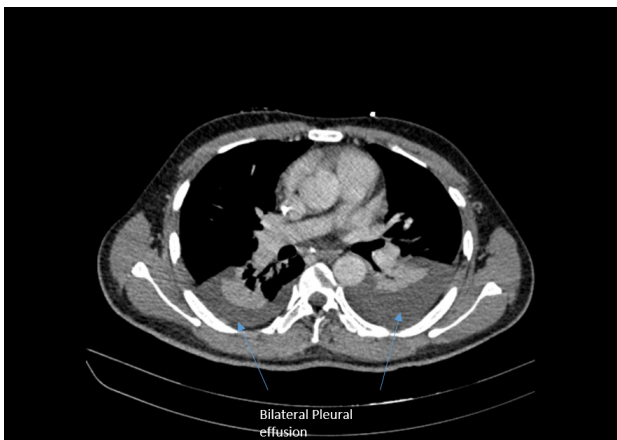

Figure 4: CECT Chest showing Bilateral pleural effusion in the same patient

Table 2: Laboratory results

Investigations/Date	Total Leucocytes Counts (Cells/cc)	Hemoglobin (gm %)	Platelets (Cells/cc)	Hematocrits (PCV)%	Liver Function Test (U/L)
05/09/2022	10520	7.3	30000	40.8	AST:135 ALT:49
6/09/2022	8150	8.5	69000	35.7	
7/09/2022	8890	9.5	94000	30.9	AST:123 ALT:40
8/09/2022	10790	8.7	102000	38.9	
9/09/2022	14110	9	103000	30	AST: 101 ALT: 42
10/09/2022	14970	9.5	324000	26.9	
11/09/2022	15130	9.8	470000	26	AST: 70 ALT: 35
12/09/2022	13500	10.2	501000	25.4	
13/09/2022	12030	11.1	482000	28.4	AST: 65 ALT: 32
14/09/2022	8870	12.9	448000	23.6	

Discussion

Dengue infections are caused by four antigenically diverse dengue virus serotypes, DEN 1, 2, 3, and 4, which are members of the Flaviviridae family. The classical symptoms that were associated with dengue fever were high grade fever with chills, muscle and joint pain, anorexia, abdominal pain, and severe vomiting. Dengue fever affects people of all ages and both sexes, with an average incubation period of 5-6 days. [3]

There are various atypical presentations of DF-like neurological manifestations (encephalopathy, acute motor weakness, seizures, neuritis, Guillain-Barre syndrome, hypokalemic paralysis, acute viral myositis, and acute encephalitis); hepatic involvement (acute hepatic failure, coagulation disturbances, and hepatomegaly); cardiac involvement (myocarditis, sinoatrial block, and atrio-ventricular dissociation); systemic lupus erythematosus, uveitis, acute kidney injury, acute inflammatory colitis, Kawasaki disease, hemophagocytic syndrome, and so on which have been documented in the literature.

The presence of gastrointestinal signs and symptoms is considered a sign of alarm in dengue. The gastrointestinal manifestations depend upon the degree of severity of Dengue. The frequency of gastrointestinal signs and symptoms is higher in cases of Dengue with warning signs (92.59%) and Severe Dengue (100%), in contrast to Dengue without warning signs (65.71%).[4-5]

Acute pancreatitis is a rare side effect of dengue fever and is typically linked to severe dengue hemorrhagic fever. Till date, there have been only a few case reports of acute pancreatitis complicating DF from across the world. Common etiologies of acute pancreatitis include gallstones, alcohol, hypertriglyceridemia, trauma and drugs (mainly antibiotics) . Less common etiologies include periampullary diverticula, pancreas divisum, a periampullary mass and infectious agents, such as mumps, coxsackievirus and cytomegalovirus. We excluded these causes of acute pancreatitis in our case by history, laboratory examination and imaging studies.

The exact pathogenesis of pancreatitis in dengue is not known. It could be due to: [5]

1. Direct invasion of virus causing inflammation and destruction of pancreatic acinar cells

2. Pancreatic damage due to dengue shock or
3. Autoimmune response to islet cells
4. Development of edema of the ampulla of vater and obstruction to outflow of pancreatic fluid.

The incidence of Acute Pancreatitis in Dengue fever has been variably reported in different studies. One study by Nimmagadda S.S et.al has reported acute pancreatitis in 1.33% of Dengue patients. [6]. In another study of dengue fever, Khanna et al. reported the incidence of acute pancreatitis to be as high as 14.5%.[7] Another study conducted by Shamim M et al reported the incidence of acute pancreatitis to be 0.8% in dengue patients.^[8]

Since most Dengue patients are already thrombocytopenic, the risk of development of hemorrhagic pancreatitis is higher. Therefore, timely diagnosis, and proper monitoring is very important in the management of Dengue pancreatitis.

Conclusions

Dengue fever induced acute pancreatitis is an atypical manifestation that is less studied. Apart from warning signs, pancytopenia, dengue hemorrhagic fever, and dengue shock syndrome can further complicate the prognosis and management. So, timely diagnosis and treatment may reduce mortality and morbidity.

References

1. Senanayake S. Dengue fever and dengue hemorrhagic fever: a

diagnostic challenge. *Aust Fam Physician*. 2006;35:609–12.

2. World Health Organization Regional Office for South-East Asia. *Comprehensive Guidelines for Prevention and Control of Dengue and Dengue Haemorrhagic Fever*. Revised and expanded edition. World Health Organization: 2011. 196p.
3. N. Frecuencia de signos y síntomas gastrointestinales del dengue. Análisis de una cohorte de 1484 pacientes [Frequency of gastrointestinal signs and symptoms of dengue. Analysis of a cohort of 1484 patients]. *Invest Clin*. 2013 Sep;54(3):299-310. Spanish. PMID: 24354243.
4. Gulati S, Maheshwari A. Atypical manifestations of dengue. *Tropical medicine & international health: TM & IH*. 2007; 12(9): 1087–95.
5. Krithika AP, Ramya R. Acute Pancreatitis: a late complication of Dengue fever. *Int J Contemp Pediatr* 2018;5:676-7.
6. Satya Sudhish Nimmagadda et al, Atypical Manifestations of Dengue Fever – Where Do We Stand Today? *Journal of Clinical and Diagnostic Research*. 2014 Jan, Vol-8(1): 71-73.DOI: 10.7860/JCDR/2014/6885.3960.
7. Khanna S, Vij JC, Kumar A, Singal D, Tandon R. Etiology of abdominal pain in dengue fever. *Dengue Bull* 2005; 29:85-88.
8. Shamim M. Frequency, pattern and management of acute abdomen in dengue fever in Karachi, Pakistan. *Asian J Surg* 2010; 33:107- 113.