

# MULTIPLE PYOGENIC LIVER ABSCESS

CASE REPORT, Vol-5 No.2

Asian Journal of Medical Science, Volume-5(2014)

<http://nepjol.info/index.php/AJMS>

<sup>1</sup>Deepak Madi, <sup>2</sup>Basavaprabhu Achappa, <sup>3</sup>Mridula Laxman, <sup>4</sup>John T Ramapuram, <sup>5</sup>Nithyananda Chowta, <sup>6</sup>Sujani Yadlapati, <sup>7</sup>Soundarya Mahalingam. <sup>1,2,3,4,5,6</sup> Department of Internal Medicine, <sup>7</sup> Department of Paediatrics, Kasturba Medical College, (affiliated to Manipal University), Mangalore.

## ABSTRACT

### CORRESPONDENCE :

Dr. Basavaprabhu Achappa  
Associate Professor,  
Department of Internal  
Medicine,  
Kasturba Medical College,  
Mangalore (Affiliated to  
Manipal University)  
Email.id:  
[bachu1504@gmail.com](mailto:bachu1504@gmail.com)  
Mobile No: +919980170480

Multiple liver abscess is a life threatening condition with high mortality. We present a case of a 59 yr old gentleman who developed multiple hepatic abscesses due to an appendicular mass. He was treated with parenteral antibiotics and ultrasound guided needle aspiration of the largest abscess was done. He recovered promptly with complete resolution of the liver abscesses. The main aim of this case report is to highlight the fact that multiple pyogenic liver abscesses can be managed with antibiotic treatment and needle aspiration.

**Key words: Multiple liver abscess, Diabetes, Pyogenic abscess**

---

*"Multiple liver abscess is a life threatening condition with high mortality"*

---

## INTRODUCTION

Liver abscesses may be solitary or multiple. They arise from biliary sepsis, portal sepsis or spontaneously.<sup>1</sup> Studies have shown that biliary disease is the commonest cause of pyogenic liver abscess.<sup>2</sup> Patients with diabetes mellitus and immunosuppressed states are at a greater risk for developing liver abscess.<sup>3</sup> There is a changing trend in the management of pyogenic liver abscess with majority of the cases being managed with parenteral antibiotics and percutaneous ultrasound/computed tomography guided aspiration.<sup>4</sup>

Mortality is high in patients with multiple liver abscesses.<sup>5</sup> There are very few published case reports of multiple pyogenic liver abscess treated successfully with antibiotics and needle aspiration from our country. We report a case of multiple pyogenic liver abscess in a patient with diabetes mellitus managed with antibiotic treatment and ultrasound guided needle aspiration.

## CASE REPORT

A 59 yr old gentleman presented to our hospital with complaints of pain abdomen and fever of 10 days duration. The pain was localized to the right hypochondrium. He was diagnosed to have diabetes mellitus 6 months back and he was on diet control. There was no history of any addictions. On examination, pulse was 114/min, BP - 130/90mm Hg, temperature 100.4°F. There was tender hepatomegaly and tenderness was also noted at McBurney's point. There was evidence of a right sided pleural effusion.

His investigations revealed: Hb -12.8g/dl, Total White Blood Cell count – 19,300 cells/cu.mm, platelet count-2, 30,000 cells/cu.mm, ESR- 115mm/1<sup>st</sup> hour. Total Bilirubin – 4.9 mg%, Direct Bilirubin- 4.85 mg%, Albumin -2.8 gm %, Alanine transaminase-163 IU/L, Aspartate transaminase-111 IU/L and Alkaline phosphatase-362 IU/L. Glycated hemoglobin was 7.3% and Fasting blood sugar was 195 mg%. Prothrombin time was normal. Widal was negative and ECG was normal. Ultrasound abdomen showed Hepatomegaly (16cm), multiple hypoechoic areas of varying sizes in both lobes of liver, largest measuring 3.8 cms in segment VII of the right lobe and inflamed, enlarged appendix measuring 1.3cm with thickened mesentery forming appendicular mass in the right iliac fossa. Computed tomography (CT) abdomen showed multiple hypodense lesions in the

liver as shown in (Figure 1) and an appendicular mass. Ultrasound guided aspiration of the largest abscess was done and the pus was sent for culture sensitivity. Pus culture and blood cultures did not reveal any organism. Chest x-ray showed a right sided pleural effusion. Pleural fluid analysis revealed 30,000 cells predominantly neutrophils. Pleural fluid culture did not show any growth. Stool routine did not show any cysts. He was treated with injection meropenem (1gram TID) for 2 weeks and injection metronidazole (500 mg TID) for 10 days followed by oral antibiotics (tab faropenem 200 mg BID) for 2 weeks. Repeat ultrasound abdomen done after 2 months showed complete resolution of the lesions. Interval appendicectomy was done.

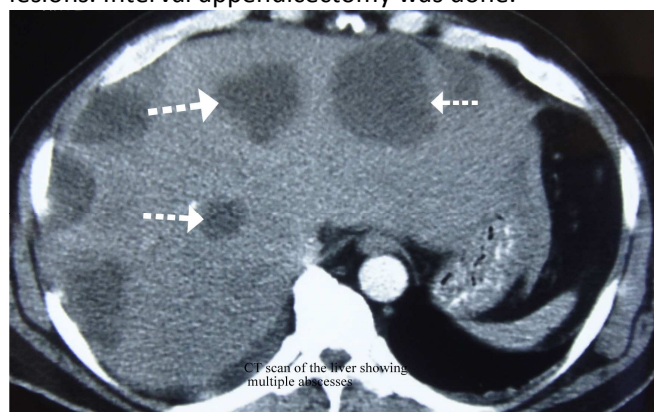


Fig 1. Computed tomography (CT) abdomen showing multiple hypodense lesions in the liver.

## DISCUSSION

Liver abscess was previously regarded a high mortality disease. In the present era mortality due to pyogenic liver abscesses is 5-30%.<sup>6</sup> In the past, appendicitis with rupture was the common source for a liver abscess.

Patients with small solitary lesions have an insidious course associated with weight loss and fatigue.<sup>7</sup> Multiple abscesses usually result in more acute presentations.<sup>7</sup> Fever is the commonest presenting symptom. Abdominal signs are non-specific in most cases. Jaundice is late unless there is biliary disease.

Micro organisms implicated are gram negative bacilli. The species vary depending on the source of sepsis. *Escherichia coli* is still the most common causative organism.<sup>8</sup> Pyogenic liver abscess caused by *Klebsiella* is seen in patients with cryptogenic etiology.

The causative organism cannot be isolated in 21% of patients.<sup>9</sup> Pus, blood and pleural fluid cultures did not reveal any organism in our patient. Abscesses due to biliary sepsis, presence of shock, multiple abscesses are independent predictors of mortality.<sup>10</sup>

Early initiation of antibiotics coupled with percutaneous drainage resulted in complete resolution of the abscess in our patient. Imaging guided needle aspiration was favoured over catheter drainage at our institution. Some groups prefer needle aspiration over catheter drainage, and some prefer catheter drainage over needle aspiration.<sup>9</sup>

Multiple liver abscess have been rarely reported in world literature. Bahloul *et al* have reported a fatal case of multiple liver abscess in a 38 yr old woman which required surgical drainage.<sup>11</sup> Singh *et al* have reported a case of multiple liver abscess in a 50 yr old female due to Fusobacterium and cytomegalovirus.<sup>12</sup> Ergas D *et al* have described a case of multiple pyogenic liver abscesses following hemorrhoid banding.<sup>13</sup>

## CONCLUSION

Multiple pyogenic liver abscess does not necessarily require open surgical drainage. Early diagnosis, prompt initiation of sensitive antibiotics and percutaneous drainage ensures resolution of the abscess thereby reducing morbidity and length of hospital stay.

## REFERENCES

- Greenstein AJ, Lowenthal D, Hammer GS, Schaffner F, Aufses AH. Continuing changing patterns of disease in pyogenic liver abscess: a study of 38 patients. *Am J Gastroenterol* 1984; 79:217-226.
- Branum GD, Tyson GS, Branum MA, Meyers WC. Hepatic abscess. Changes in etiology, diagnosis, and management. *Ann Surg* 1990;212(6):655-662.
- Malik AA, Bari SL, Rouf KA, Wani KA. Pyogenic Liver abscess: changing patterns in approach. *World J Gastrointest Surg* 2010; 2: 395-401.
- Pearce NW, Knight R, Irving H, Menon K, Prasad KR, Pollard SG, et al. Non-operative management of pyogenic liver abscess. *HPB (Oxford)* 2003; 5:91-95.
- Schiff E, Pick N, Oliven A, Odeh M. Multiple liver abscesses after dental treatment. *J Clin Gastroenterol* 2003; 36: 369-371.
- Chen SC, Huang CC, Tsai SJ, Yen CH, Lin DB, Wang PH, et al. Severity of disease as main predictor for mortality in patients with pyogenic liver abscess. *Am J Surg* 2009; 198(2):164-172.
- Heneghan HM, Healy NA, Martin ST, Ryan RS, Nolan N, Traynor O, et al. Modern management of pyogenic hepatic abscess: a case series and review of the literature. *BMC Res Notes* 2011; 4:80.
- Cerwenka H, Bacher H, Werkgartner G, El-Shabrawi A, Kornprat P, Bernhardt GA, et al. Treatment of patients with pyogenic liver abscess. *Chemotherapy* 2005; 51: 366-369.
- Pang TCY, Fung T, Samra J, Hugh TJ, Smith RC. Pyogenic liver abscess: An audit of 10 years' experience. *World J Gastroenterol* 2011; 17: 1622-1630.
- Alvarez Perez JA, Gonzalez JJ, Baldonado RF, Sanz L, Carreno G, Junco A, et al. Clinical course, treatment, and multivariate analysis of risk factors for pyogenic liver abscess. *Am J Surg* 2001; 181:177-186.
- Bahloul M, Chaari A, Bouaziz-Khlaf N, Kallel H, Herguefi L, Chelly H, et al. Multiple pyogenic liver abscess. *World J Gastroenterol* 2006; 12: 2962-2963.
- Singh RM, Singh A, Qadri A, Crock RD, Fahmy N. CMV as a Cause of Multiple Liver Abscesses in an Immunocompetent Host: A Case Report and Review of the Literature. *Pract Gastroenterol* 2002; 26:44-49.
- Ergas D, Abdul-Hai A, Sthoeger Z, Menahem BH, Miller R. Multiple pyogenic liver abscesses following hemorrhoid banding. *Isr Med Assoc J* 2007; 9:753-754.

### Authors Contributions:

**DM, JTR, ML and NC** were the treating physicians.  
**DM and BA** prepared the initial draft.  
**ML, SM and SY** helped in the final preparation of the manuscript.

### Conflict of Interest: None

**Date of Submission: 24.9.2013**

**Date of Peer review: 29.9.2013**

**Date of submission of revised version: 3.10.2013**

**Date of peer review: 6.10.2013**

**Date of Acceptance: 6.10.2013**

**Date of Publication: 10.1.2014**