

# A comparative study of analgesic effect between ultrasound-guided posterior *vis-a-vis* lateral transversus abdominis plane block in patients undergoing total abdominal hysterectomy with bilateral salpingo-oophorectomy under spinal anesthesia



Rajib Sikder<sup>1</sup>, Sankar Roy<sup>2</sup>, Arunava Biswas<sup>3</sup>, Dipasri Bhattacharya<sup>4</sup>

<sup>1</sup>Deputy Medical Superintendent, Sanctoria Hospital, ECL Head Quarter, Asansol, West Bengal, India, <sup>2</sup>Associate Professor, Department of Anesthesiology, Jalpaiguri Government Medical College and Hospital, Jalpaiguri, West Bengal, India, <sup>3</sup>Professor and Head, Department of Pharmacology, Barasat Government Medical College and Hospital, Barasat, West Bengal, India, <sup>4</sup>Professor and Head, Department of Anesthesiology, Santiniketan Medical College, Birbhum, West Bengal, India

Submission: 19-09-2024

Revision: 28-12-2024

Publication: 01-02-2025

## ABSTRACT

**Background:** Transversus abdominis plane (TAP) block is used to reduce pain after total abdominal hysterectomy and bilateral salpingo-oophorectomy (TAH+BSO). Two important approaches are ultrasound-guided lateral and posterior approaches. Ultrasound-guided blocks help in the correct localization of the plane and proper deposition of drugs. **Aims and Objectives:** This study was done to compare the analgesic effect of posterior TAP block and lateral TAP block in TAH+BSO. **Materials and Methods:** A double-arm observational study was conducted on eighty patients (ASA 1 and 2) posted for TAH+BSO under spinal anesthesia. They were randomly divided into two equal groups, 40 each (Groups L and P). Ultrasound-guided lateral TAP block and posterior TAP block were administered bilaterally with 20 mL 0.25% bupivacaine in the L group and P group, respectively, on each side of the abdomen after skin closure at the end of the operation. The intensity of post-operative pain was evaluated by a 10 cm Visual Analog Scale (VAS) Score at 1, 3, 6, 9, 12, and 24 h. If VAS was more than 4, 1 g paracetamol infusion was given. Duration of analgesia, total rescue analgesic requirement, and hemodynamic changes by measuring mean arterial pressure and pulse rate were also observed. **Results:** VAS score was significantly less in Group P than in Group L ( $P < 0.05$ ). The time of first rescue analgesia requirement was longer in Group P compared to Group L. Total analgesic requirement in 24 h was less in Group P compared to Group L. Hemodynamic changes were comparable in both groups. **Conclusion:** Posterior TAP block provides better post-operative analgesia than lateral TAP block with stable hemodynamics in patients undergoing TAH BSO operation under spinal anesthesia.

**Key words:** Posterior TAP block; lateral TAP block; ultrasound; bupivacaine; TAH BSO

## INTRODUCTION

Transversus abdominis plane (TAP) block was first described in 2001, as a regional anesthesia technique, used to alleviate

somatic pain in the lower abdominal surgery. Ultrasound imaging helps to detect the perfect localization of the needle in the proper plane and proper deposition of the

### Address for Correspondence:

Dr. Arunava Biswas, Professor and Head, Department of Pharmacology, Barasat Government Medical College & Hospital, Barasat-700124, West Bengal, India. **Mobile:** +91-9674328329. **E-mail:** drabiswas@gmail.com

### Access this article online

#### Website:

<https://ajmsjournal.info/index.php/AJMS/index>

**DOI:** 10.71152/ajms.v16i2.4348

**E-ISSN:** 2091-0576

**P-ISSN:** 2467-9100

Copyright (c) 2025 Asian Journal of Medical Sciences



This work is licensed under a Creative Commons Attribution-NonCommercial 4.0 International License.

drug. Reliable blockade of dermatome achieved. After lower abdominal surgery, the patient experienced moderate to severe pain. The anterolateral abdominal wall was innervated by ventral rami of spinal nerve T7-L1. The intercostal nerve (T7-T11) exits the intercostal space and run in the neuromuscular plane in between the internal oblique and transversus abdominis muscle.<sup>1</sup> Local anesthetic deposition in this plane will provide good analgesia after lower abdominal surgery. At present, TAP block is used for post-operative analgesia in various kinds of surgical procedures, namely, open and laparoscopic cholecystectomy, appendectomy, cesarean section, open retro pubic prostatectomy,<sup>2-5</sup> total abdominal hysterectomy (TAH),<sup>6-8</sup> and hernia repair.<sup>9</sup> Anterolateral abdominal wall block depends on the spread of local anesthetic agents through the musculo-fascial plane to anesthetized multiple small nerves and plexus.<sup>1</sup> Reliable blockade of dermatomes can be accomplished with a good volume of local anesthetic agents (20–30 mL). With the use of a large volume of local anesthetic, there is a markedly higher chance of systemic toxicity.<sup>10</sup> There are two major types of TAP block, the lateral approach and the posterior approach. The lateral TAP approach is commonly used. According to certain publications, the posterior TAP block is being employed with greater success these days.<sup>11,12</sup> However, according to the study of Mutlu et al.<sup>13</sup> and Morimoto,<sup>14</sup> lateral TAP appeared better in some other surgical cases. Hence, to clear this ambiguity as reflected in different earlier studies, an attempt was made to compare the analgesic efficacy of the posterior TAP block with the lateral TAP block following total abdominal hysterectomy with bilateral salpingo-oophorectomy (TAH+BSO) for pain relief.

### Aims and objectives

The objective of this study was to compare the analgesic effect, duration of analgesia and requirement of rescue analgesic between lateral TAP Block and Posterior TAP block following TAH+BSO under spinal anesthesia.

## MATERIALS AND METHOD

A double-arm observational study was conducted on the patients planned for TAH+BSO in the Obstetrics and Gynecology operation theater at R.G. KAR Medical College and Hospital, Kolkata, for a period of 1 year (March 2021–2022) after prior approval from the Institutional Ethics Committee [Memo No. RKC/314 dated 06.03.2021]. Based on the prevalence of TAH in the hospital as mentioned in the study of Desai et al.<sup>15</sup> which was around 20.7% and matched with the current hospital's patient load, the sample size was calculated around n=80 with a power of 90%.

Prior written informed consent was obtained from patients with ASA Grade 1 and 2 and body mass index

<30 waiting for the planned surgery and they were divided into two equal groups: Group P (ultrasound-guided bilateral posterior TAP Block with injection bupivacaine 0.25%) and Group L (ultrasound-guided bilateral lateral TAP Block with injection bupivacaine 0.25%) with n=40 each, respectively. Uncooperative patients or refusal, ASA Grade 3 and 4, suffering from cardiac and neurological diseases, uncontrolled diabetes and hypertension, chronic obstructive pulmonary disease, and bronchial asthma, those on psychiatric medications, previously known allergy to the drug used, epilepsy, and any kind of pre-existing neuropathy were excluded from the study.

After the initial application of the standard anesthetic technique in both the study groups, blood pressure (systolic, diastolic, and mean), heart rate, electrocardiogram, and oxygen saturation level were monitored at regular intervals. Subsequent to the completion of the operation and skin closure, bilateral TAP block was given, followed by an antiseptic dressing done at the skin incision site. During ultrasound-guided posterior TAP nerve block, the linear transducer was placed in the axial plane in the mid-axillary line and moved posteriorly to the most posterior limit of the TAP between the internal oblique and transversus abdominis muscles.<sup>16</sup> The same technique was used, that is, linear probe in ultrasonography-guided TAP block in the present study. In Group P, an ultrasound probe was placed posterior to the mid-axillary line between the costal margin and the iliac crest and scanned posteriorly where the transversus abdominis tailed off and turned into aponeurosis and the quadratus lumborum muscle has started. Then, the needle was introduced into the TAP between the internal oblique and transversus abdominis, posterior to the mid-axillary line and close to the aponeurosis. After locating the plane, 20 mL 0.25% bupivacaine was administered bilaterally. In Group L, high-frequency linear probe was placed at the midpoint of the costal margin and the highest point of the iliac crest in the mid-axillary line. The needle of the syringe was introduced in that plane medial to lateral in direction and 20 mL 0.25% bupivacaine was injected bilaterally. The group distribution/selection of patients to either group was decided and done by one of the investigators based on convenience sampling after the operation was over and the operating physician had no role in selection other than observation and follow-up of the patients. The intensity of the pain was measured by Visual Analog Scale (VAS) Score at 1, 3, 6, 9, 12, and 24 h intervals. Duration of analgesia by the time of administration of block to the requirement of rescue analgesic (if any) was assessed. The total analgesic requirement in 24 h was also noted. The effect on the hemodynamic status of the operated patients was observed by measuring the mean arterial pressure (MAP) and pulse rate (PR). The flow of the study is depicted in Figure 1.

## Statistical analysis

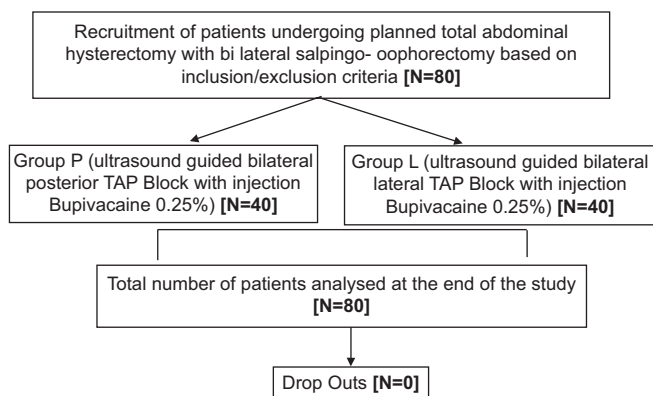
For statistical analysis, data were entered into a Microsoft Excel spreadsheet and then analyzed by SPSS (version 27.0; SPSS Inc., Chicago, IL, USA) and GraphPad Prism version 5. Data had been summarized as mean and standard deviation for numerical variables and count and percentages for categorical variables. Unpaired proportions were compared by Chi-square test or Fischer's exact test, as appropriate.  $P \leq 0.05$  was considered statistically significant.

## RESULTS

In this study, all the recruited patients ( $n=80$ ) were analyzed at the end and there were no dropouts. The demographic characteristic features of the study participants are depicted in Table 1 which reveals that the two groups were comparable in every aspect.

In both the groups, majority of the patients belong to 41–50 years, that is, Group L: (45%) and Group P: 57.5%, respectively. The mean VAS scores for assessment of post-operative pain in the patients as observed at different time intervals during the study were illustrated in the line diagram Figure 2.

Difference in cumulative VAS score at 3, 6, 12, and 24 h was statistically significant  $P < 0.0001$ . The total dose of



**Figure 1:** Study participant's selection flow chart

**Table 1: Demographic data and ASA distribution**

Parameters	Group L (n=40)	Group P (n=40)	P-value
Age (years)*	47.58±6.05	48.95±4.44	0.253
Weight (Kg)*	55.89±8.46	56.95±8.85	0.588
Height (cm)*	154.58±9.41	156.26±08.44	0.403
Body mass index (kg/m <sup>2</sup> )*	23.24±3.34	23.07±2.83	0.805
ASA			
1	23	25	0.466
2	17	15	

\*Mean±standard deviation

rescue analgesic requirement (Paracetamol infusion in grams) during the post-operative period first 24 h for Group L was  $1.775 \pm 0.422$  and Group P was  $0.575 \pm 0.549$  and the difference was statistically significant ( $P < 0.0001$ ). The variation in PR and MAP during the post-operative period was assessed, presented in the following Table 2 revealed no statistically significant changes among the two groups.

## DISCUSSION

While comparing the analgesic effect between posterior TAP block versus lateral TAP block using ultrasound in patient undergoing TAH+BSO under spinal anesthesia in the present study revealed certain outcome which were compared and discussed with the end result of previous published studies.

Posterior TAP block provides prolong duration of analgesia and less requirement of analgesic in 1<sup>st</sup> 24 h after operation similar to the study conducted by Elsharkawy et al. 2016,<sup>16</sup> Faiz et al.<sup>17</sup> Posterior TAP block produces sympathetic blockade which might be the reason behind better analgesia as stated by Yoshiyama et al.<sup>11</sup> and Hussain et al.<sup>18</sup> Posterior TAP block could provide better analgesia than the lateral TAP block for laparoscopic gynecological surgery in perioperative period. Better analgesia enabled us to decrease the incidence of complications and the usage of additional analgesics.

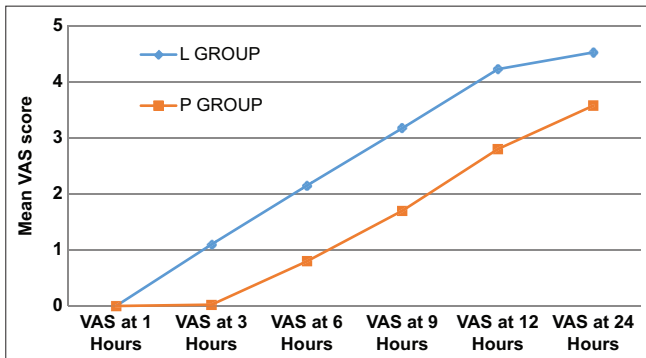
Benabou et al.<sup>19</sup> compared laparoscopic posterior versus lateral TAP block in gynecological surgery. Posterior TAP block was also associated with lower pain scores at 24, 36, and 48 h compared to the lateral TAP which was similar to our study.

A meta-analysis conducted by Abdallah et al.,<sup>20</sup> compared the length of analgesic effect in both posterior and lateral approaches. It was concluded that the posterior approach was more effective in reducing post-operative pain at rest and in the dynamic state and provided longer analgesia than the lateral approach. In addition, it reduced morphine consumption 48 h after the surgery. The results of the above analysis are consistent with the results of the present study. Guo et al.<sup>21</sup> showed that post-operative ultrasound-guided TAP block and rectus sheath block reduced post-operative opioid use in patients following laparoscopy-assisted radical resection of rectal cancer. We have also found the requirement of rescue analgesic was less in the posterior TAP block group.

**Table 2: Variation in pulse rate and mean arterial pressure at different time interval**

PR at time interval (Hours)	Group L (n=40) (Mean±SD)	Group P (n=40)	P-value	MAP at time interval (Hours)	Group L (n=40) (Mean±SD)	Group P (n=40)	P-value
Baseline	87.84±10.26	88.88±9.73	0.522	Baseline	85.53±8.06	87.80±8.68	0.23
1	88.92±11.83	82.55±9.25	0.001	1	86.46±7.73	84.87±7.63	0.35
3	87.38±11.13	89.44±8.53	0.2054	3	89.82±8.31	87.87±7.52	0.276
6	91.51±10.39	90.55±9.64	0.263	6	89.61±10.49	91.34±6.84	0.383
9	96.23±10.38	80.44±9.19	0.400	9	93.33±9.19	92.39±5.67	0.58
12	98.05±10.64	95.44±6.77	0.438	12	97.53±10.24	96.87±6.28	0.727
24	91.29±8.71	93.44±7.24	0.464	24	97.05±8.02	95.53±6.51	0.356

PR: Pulse rate, MAP: Mean arterial pressure, SD: Standard deviation



**Figure 2:** Mean Visual Analog Scale score at the different time intervals

### Limitations of the study

As the study patients belonged to ASA-PS I-II, caution should be exercised to generalize it for patients with serious medical issues. Moreover, only gynecological surgeries were considered for this study. Variable tissue handling by different surgeons can be a confounding factor in generating different levels of pain.

### CONCLUSION

The use of ultrasound-guided posterior TAP block for pain control after TAH+BSO is more worthy than the lateral TAP block as it provides a longer duration of analgesia with less requirement of rescue analgesic during the first 24 h of the post-operative period.

### ACKNOWLEDGMENT

The authors would like to acknowledge all the supporting and paramedical staff from the Department of Obstetrics and Gynecology and Anesthesiology for their assistance and contribution in successful completion of the study.

### REFERENCES

- Chin KJ, McDonnell JG, Carvalho B, Sharkey A, Pawa A and Gadsden J. Essentials of our current understanding: Abdominal wall blocks. *Reg Anesth Pain Med.* 2017;42(2):133-183. <https://doi.org/10.1097/AAP.0000000000000545>

- El-Dawlatly AA, Turkistani A, Kettner SC, Machata AM, Delvi MB, Thallaj A, et al. Ultrasound-guided transversus abdominis plane block: Description of a new technique and comparison with conventional systemic analgesia during laparoscopic cholecystectomy. *Br J Anaesth.* 2009;102(6):763-767. <https://doi.org/10.1093/bja/aep067>
- Niraj G, Searle A, Mathews M, Misra V, Baban M, Kiani S, et al. Analgesic efficacy of ultrasound-guided transversus abdominis plane block in patients undergoing open appendectomy. *Br J Anaesth.* 2009;103(4):601-605. <https://doi.org/10.1093/bja/aep175>
- McDonnell JG, Curley G, Carney J, Benton A, Costello J, Maharaj CH, et al. The analgesic efficacy of transversus abdominis plane block after cesarean delivery: A randomized controlled trial. *Anesth Analg.* 2008;106(1):186-191. <https://doi.org/10.1213/01.ane.0000290294.64090.f3>
- O'Donnell BD. The transversus abdominis plane (TAP) block in open retropubic prostatectomy. *Reg Anesth Pain Med.* 2006;31(1):91. <https://doi.org/10.1016/j.rapm.2005.10.006>
- Carney J, McDonnell JG, Ochana A, Bhinder R and Laffey JG. The transversus abdominis plane block provides effective postoperative analgesia in patients undergoing total abdominal hysterectomy. *Anesth Analg.* 2008;107(6):2056-2060. <https://doi.org/10.1213/ane.0b013e3181871313>
- Bhattacharjee S, Ray M, Ghose T, Maitra S and Layek A. Analgesic efficacy of transversus abdominis plane block in providing effective perioperative analgesia in patients undergoing total abdominal hysterectomy: A randomized controlled trial. *J Anaesthesiol Clin Pharmacol.* 2014;30(3):391.
- Atim A, Bilgin F, Kilickaya O, Purtuloglu T, Alanbay I, Orhan ME, et al. The efficacy of ultrasound-guided transversus abdominis plane block in patients undergoing hysterectomy. *Anaesth Intensive Care.* 2011;39(4):630-634. <https://doi.org/10.1177/0310057X1103900415>
- Venkatraman R, Abhinaya RJ, Sakthivel A and Sivarajan G. Efficacy of ultrasound-guided transversus abdominis plane block for postoperative analgesia in patients undergoing inguinal hernia repair. *Local Regional Anesthesia.* 2016;9:7. <https://doi.org/10.2147/LRA.S93673>
- Hebbard P, Fujiwara Y, Shibata Y and Royse C. Ultrasound-guided transversus abdominis plane (TAP) block. *Anaesth Intensive Care.* 2007;35(4):616-618.
- Yoshiyama S, Ueshima H, Sakai R and Otake H. A posterior TAP block provides more effective analgesia than a lateral TAP block in patients undergoing laparoscopic gynecologic surgery: A retrospective study. *Anesthesiol Res Pract.* 2016;2016:4598583. <https://doi.org/10.1155/2016/4598583>
- Patil S, Karnalkar A and Jadhav K. Comparison of ultrasound



- guided transversus abdominis plane (TAP) block by posterior and lateral approach for their analgesic efficacy after lower abdominal surgery. *Med Pulse Int J Anesthesiol* 2019;10(1):22-27.
13. Mutlu ÖP, Tütüncü AÇ, Kendigelen P and Esen BK. Posterior transversus abdominis plane block versus lateral quadratus lumborum block in children undergoing open orchiopexy: A randomized clinical trial. *Braz J Anesthesiol*. 2024;74(5):744443.  
<https://doi.org/10.1016/j.bjane.2023.06.004>
  14. Morimoto Y. Transversus abdominis plane block: A review of the technique and its efficacy. *USG Anesth Pain Intensive Care*. 2015;19:357-60.
  15. Desai S, Campbell OM, Sinha T, Mahal A and Cousens S. Incidence and determinants of hysterectomy in a low-income setting in Gujarat, India. *Health Policy Plan*. 2017;32(1):68-78.  
<https://doi.org/10.1093/heapol/czw099>
  16. Elsharkawy H and Bendtsen TF. Ultrasound-Guided Transversus Abdominis Plane and Quadratus Lumborum Nerve Blocks. Available from: <https://www.nysora.com/topics/abdomen/ultrasound-guided-transversus-abdominis-plane-quadratus-lumborum-blocks/> [Last accessed on 2021 Jun 23].
  17. Faiz SH, Alebouyeh MR, Derakhshan P, Imani F, Rahimzadeh P and Ashtiani MG. Comparison of ultrasound-guided posterior transversus abdominis plane block and lateral transversus abdominis plane block for postoperative pain management in patients undergoing cesarean section: A randomized double-blind clinical trial study. *J Pain Res*. 2018;11:5-9.  
<https://doi.org/10.2147/JPR.S146970>
  18. Hussain N, Brull R, Weaver T, Zhou M, Essandoh M and Abdallah FW. Postoperative Analgesic effectiveness of quadratus lumborum block for cesarean delivery under spinal anesthesia a systematic review and meta-analysis. *Anesthesiology*. 2021;134(1):72-87.  
<https://doi.org/10.1097/ALN.0000000000003611>
  19. Benabou K, Kim S, Tierney CH, Messom JE, Kyriakides TC, Kashani SM, et al. Laparoscopic posterior versus lateral transversus abdominis plane block in gynecology. *JLS*. 2020;24(3):e2020.00032.  
<https://doi.org/10.4293/JLS.2020.00032>
  20. Abdallah FW, Laffey JG, Halpern SH and Brull R. Duration of analgesic effectiveness after the posterior and lateral transversus abdominis plane block techniques for transverse lower abdominal incisions: A meta-analysis. *Br J Anaesth*. 2013;111(5):721-735.  
<https://doi.org/10.1093/bja/aet214>
  21. Guo Q, Li R, Wang L, Zhang D and Ma Y. Transversus abdominis plane block versus local anaesthetic wound infiltration for postoperative analgesia: A systematic review and meta-analysis. *Int J Clin Exp Med*. 2015;8(10):17343-17352.

**Authors Contribution:**

**RS, SR-** Concept, design of study and literature search, experimental studies; **RS, SR-** Data acquisition, data analysis, statistical analysis; **AB, DB-** Manuscript preparation; **AB, DB, RS-** Manuscript editing and manuscript review.

**Work attributed to:**

R.G. Kar Medical College and Hospital, Kolkata, West Bengal, India.

**Orcid ID:**

Arunava Biswas -  <https://orcid.org/0000-0002-9676-3410>

**Source of Funding:** Nil, **Conflicts of Interest:** None declared.