

Granulomatous mastitis and other inflammatory mastitis simulating breast neoplasms – A retrospective study in the fine needle aspiration cytology clinic of a tertiary care center in eastern India



Pamela Nayak¹, Meghadipa Mandal², Srishtidhar Mangal³

¹Assistant Professor, ²Senior Resident, ³Associate Professor and Head, Department of Pathology, Jhargram Government Medical College and Hospital, Jhargram, West Bengal, India

Submission: 02-06-2024

Revision: 04-07-2024

Publication: 01-08-2024

ABSTRACT

Background: Fine needle aspiration cytology (FNAC) is an important diagnostic modality in palpable breast lesions. This together with imaging modality is important in distinguishing benign from malignant lesions of the breast. Granulomatous/inflammatory mastitis forms a small subset of breast lesions that may present as a breast lump. Clinical and radiological features in these cases may mimic malignant breast pathology. **Aims and Objectives:** The aim of this study was to study the frequency of granulomatous mastitis and other inflammatory mastitis with respect to other neoplastic lesions of the breast, presented in FNAC clinics and to correlate the cytological findings with the clinical presentation of granulomatous and other inflammatory mastitis. **Materials and Methods:** A retrospective study was conducted in the Department of Pathology in a tertiary care center in Eastern India for duration of 4 years 5 months. Details of all patients who underwent FNAC for breast lesions during the study period were recorded in terms of their clinical presentation, cytological findings, imaging, and ancillary investigations. The findings were then tabulated in a master sheet and analysis done by descriptive statistics using SPSS 25. **Results:** A total of 154 cases were included with 5 cases (3.2%) of granulomatous and 12 cases (7.8%) of inflammatory mastitis. Age range for granulomatous/inflammatory mastitis was 20–70 years. Lump and pain were the most common complaints followed by inflammatory skin changes and nipple discharge. Very few cases also showed nipple retractions and very occasional systemic symptoms like fever. History of lactation was seen among five cases. Three cases showed positive acid-fast bacilli in Ziehl–Neelsen stain. Radiology was discordant with cytological findings in three cases, where the former suggested a breast neoplastic process. **Conclusion:** Granulomatous/inflammatory mastitis is a rarely diagnosed entity in breast cytopathology with no standard guidelines for management. Antibiotics antitubercular therapy and corticosteroids are some proposed lines of medical management. In treatment-resistant cases, wide local excision may be done depending on available resources and surveillance opportunities.

Key words: Acid-fast bacilli; Fine needle aspiration cytology; Granulomatous mastitis; Inflammatory mastitis

INTRODUCTION

Fine needle aspiration cytology (FNAC) is a simple, cheap yet effective tool in rapid diagnosis of palpable

breast lesions. It is the first line of investigation, due to the minimal invasive nature of the procedure, in all cases of suspected breast neoplasms. The cytological interpretation of all cases is done in corroboration with

Access this article online

Website:

<http://nepjol.info/index.php/AJMS>

DOI: 10.3126/ajms.v15i8.66871

E-ISSN: 2091-0576

P-ISSN: 2467-9100

Copyright (c) 2024 Asian Journal of Medical Sciences



This work is licensed under a Creative Commons Attribution-NonCommercial 4.0 International License.

Address for Correspondence:

Dr. Meghadipa Mandal, Senior Resident, Department of Pathology, Jhargram Government Medical College and Hospital, Jhargram, West Bengal, India. **Mobile:** +91-7003013909. **E-mail:** meghadipa.mandal41@gmail.com

clinical and radiological findings, popularly known as triple assessment. It is an invaluable tool in differentiating benign from malignant breast lesions when all results of triple assessment are in unison. This is followed by a core biopsy of the lesion and this approach may obviate the need for standard excision biopsy of breast lesions.¹ There may be many cases of non-neoplastic processes of breast that may simulate breast mass clinically and in imaging studies. Granulomatous mastitis (GM) is one such group of inflammatory breast disorders that can mimic breast neoplasms or infectious mastitis, both clinically and radiologically.² The etiopathogenesis is vastly idiopathic with possible roles of trauma, hormonal effect, metabolic process, previous therapy-related changes or even infections,³ tuberculosis being an important etiology behind this entity. There is a lack of any consensus on management in the literature due to the rarity of this condition.⁴ There can be varied etiologies behind other inflammatory mastitis as well. GM or other inflammatory mastitis cases usually present with a lump with/without the features of inflammation.

The present study aims to measure the frequency of GM and other inflammatory mastitis cases present with breast lesions in FNAC clinic of this study setting. All the cases were studied concerning their clinical presentation and ancillary investigations to arrive at the diagnosis.

Aims and objectives

1. To study the frequency of GM and other inflammatory mastitis with respect to other neoplastic lesions of the breast, presented in FNAC clinics
2. To correlate the cytological findings with the clinical presentation of granulomatous and other inflammatory mastitis.

MATERIALS AND METHODS

A retrospective descriptive study was conducted in the Department of Pathology of a tertiary care center in eastern India following approval from institutional ethics committee. The study duration was of 4 years 5 months (September, 2019–February, 2024). All cases of FNACs performed for suspected breast lesions during this period were retrieved from archive and included as the study population. During data entry, details of cases that were partly or fully lost were excluded from the study. A master sheet was prepared with respect to age, duration, clinical, cytological, and radiological findings of all study subjects. Appropriate photomicrographs were taken where deemed necessary. Descriptive statistics were performed using SPSS 25, wherever applicable.

RESULTS

The total number of subjects during the study period whose records were completely available in the archive was 154, which was the sample size for this study population. The cytological diagnosis of these cases was divided as follows: Fibroadenoma (74 cases), fibroadenosis with fibrocystic changes or fibroadenomatoid hyperplasia (18 cases), proliferative breast disease without atypia (6 cases), proliferative breast disease with atypia (13 cases), breast (ductal) carcinoma (17 cases), phyllodes tumor (2 cases), other cystic/benign lesions (7 cases), GM (5 cases), and inflammatory/suppurative mastitis (12 cases) (Table 1 and Figures 1-4). *Mycobacterium tuberculosis* was the known etiology behind three cases proven by Ziehl–Neelsen stain (ZN stain) (Figure 5) and cartridge-based nucleic acid amplification test.

The age range for this study population was 13–73 years. Patients of GM group belonged to the range of 20–35 years, whereas those of Inflammatory mastitis belonged to the range of 23–70 years. The symptoms of these cases were mostly lump, pain, rarely nipple discharge, and very rarely systemic symptoms like fever. The duration of symptoms of

Table 1: Distribution of cases as per their cytological diagnosis (n=154)

Diagnosis	Number (n=154)	Frequency (%)
Fibroadenoma	74	48
Fibroadenosis with fibrocystic changes or fibroadenomatoid hyperplasia	18	11.8
Proliferative breast disease without atypia	6	4
Proliferative breast disease with atypia	13	8.4
breast (ductal) carcinoma	17	11
Phyllodes tumor	2	1.3
Granulomatous mastitis	5	3.2
Inflammatory/suppurative mastitis	12	7.8
Other cystic/benign lesions	7	4.5

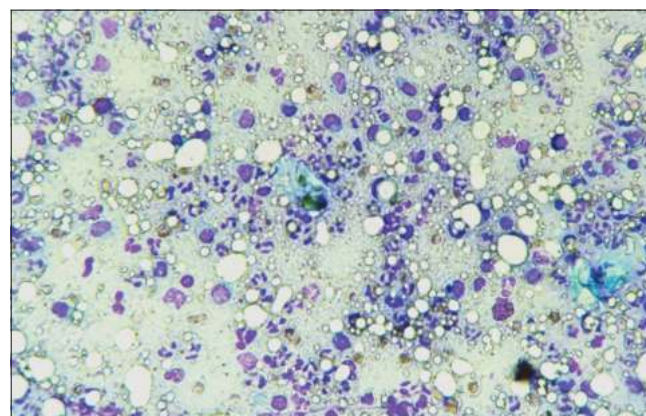


Figure 1: Cytological smear showing acute inflammatory mastitis in the background of lactational changes (Leishman-Giemsa stain, x100 magnification)

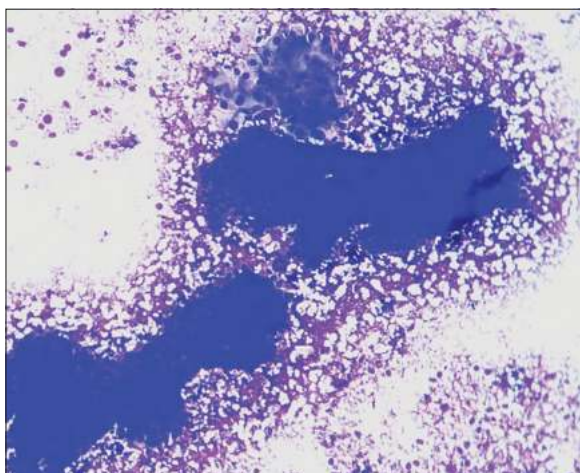


Figure 2: Cytological smear showing fibroadenoma with apocrine changes (Leishman-Giemsa stain, x100 magnification)

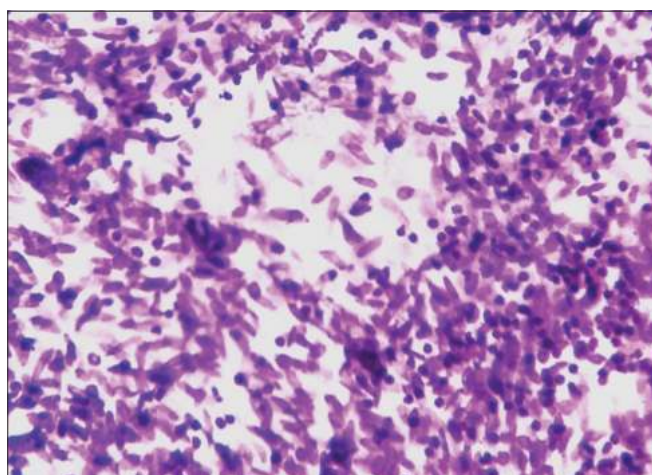


Figure 3: Cytological smear showing granulomatous mastitis (PAP stain, x400 magnification)

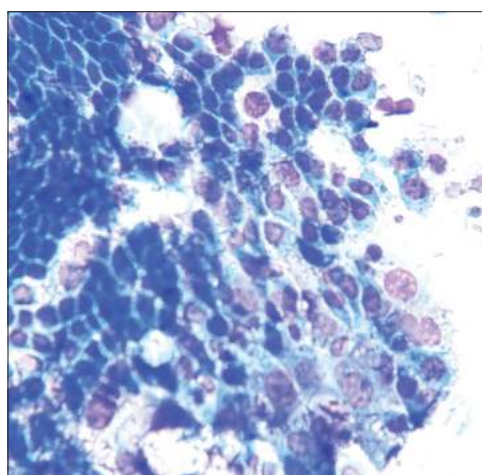


Figure 4: Cytological smear showing atypical ductal hyperplasia (Leishman-Giemsa stain, x400 magnification)

granulomatous and other inflammatory mastitis was from 4 days to 1 year, whereas those with diagnosed malignancies

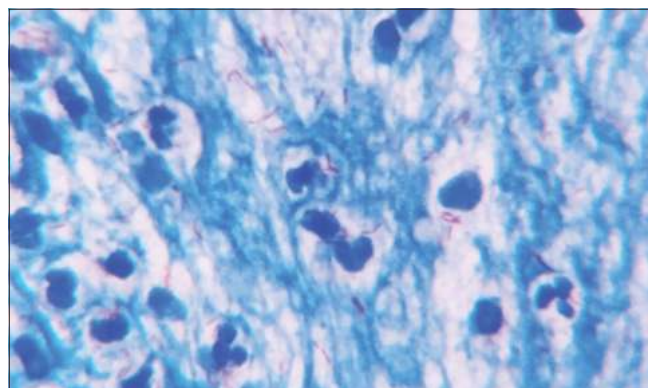


Figure 5: Plenty of acid-fast bacilli in the background of inflammation (ZN stain, x1000 magnification)

were 6 months–6 years, with recent rapid progression in terms of rapid increase in size of lump, etc. Fever was seen in only one case of inflammatory mastitis out of the entire study population. Pain was seen in 43 cases (27.9%) of the study population, of which, two were of GM and six were of inflammatory mastitis. A total of five patients were lactating, of which, one was cytologically diagnosed as GM. Skin changes in terms of redness, inflammation, occasional Peau d'orange changes were seen in 20 cases and five of them were granulomatous/inflammatory in nature. Nipple discharge was seen among four cases and three out of them were diagnosed as granulomatous/inflammatory mastitis. Nine cases showed nipple retraction, of which two were granulomatous/inflammatory mastitis (Table 2 and Figure 6).

Fifty-one cases of this study population underwent radiological study, mostly ultrasonogram, which included four cases of granulomatous/inflammatory mastitis. In three cases, the cytological diagnosis was discordant, where space-occupying lesion was seen in radiology and cytology showed inflammatory/suppurative mastitis.

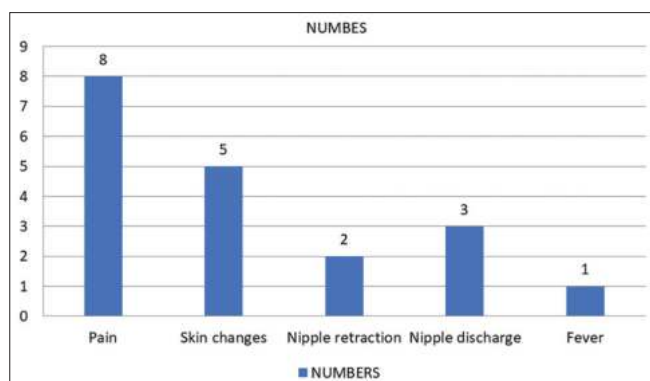
DISCUSSION

FNAC is a very common minimally invasive, almost painless, hassle-free procedure that has proved its worth over time as an invaluable tool in the initial screening of palpable breast lesions. It is an important tool in distinguishing benign and malignant lesions of the breast when combined with radiology. Often some rare entities are encountered in breast cytology cases, GM is one such pathology.

GM is a rare benign chronic inflammatory breast disease which has diverse etiology such as trauma, metabolic or hormonal processes, autoimmunity, and infections. Radiological findings are non-specific with no standard management protocol.² The radiological findings may often

Table 2: Frequency of occurrence of different signs/symptoms among the study population

Signs/Symptoms	Number	Frequency (%)
Pain	43	28
Skin changes (inflammation, peau d'orange change, etc.)	20	13
Nipple discharge	4	2.6
Nipple retraction	9	16.8
Systemic symptoms (fever)	1	0.6

**Figure 6:** Frequency of occurrence of signs/symptoms among patients of granulomatous/inflammatory mastitis

be dubious giving false impression of neoplasm as was seen in four cases in this population. A retrospective study from south India reported 76 cases of idiopathic GM over 8-year period; however, they excluded tubercular mastitis cases.⁵ Another study from central India reported a total of 83 cases over 2 years 7 month's period. Among them, the acid-fast bacilli (AFB) were demonstrated in 14.5% of cases.⁶ A tertiary care center from the northern part of West Bengal reported a total of 19 cases of GM of which one case demonstrated AFB on Z-N stain smear, and five cases, PCR from retrieved material gave positive results for *M. tuberculosis*.⁷ Another study from the southern part of West Bengal reported 75 cases of GM over 7 years, where they evaluated the role of FNAC in diagnosing idiopathic GM.⁸ This study showed five cases of GM, of which, three were of tubercular etiology over the duration of around 4 years.

Inflammatory mastitis is however a multifactorial inflammatory disease of the mammary gland where well-defined granulomas are not demonstrated in cytology smears, but plenty of polymorphs and inflammatory exudate is seen in the smears. This can be due to bacterial infections other than *M. tuberculosis*, like Gram-positive bacilli corynebacteria as was seen by Taylor et al.⁹ Lactation may also be an important contributing factor behind inflammatory mastitis in some cases,¹⁰ as was seen in five cases of this population.

There is a wide variability in clinical and radiological features in GM, often mimicking inflammatory breast

carcinoma.¹¹ In such a scenario, cytology and biopsy are crucial for confirmatory opinion. Palpable lump/lumpiness was seen in all cases of granulomatous/inflammatory mastitis, followed by pain and tenderness. Inflamed, reddish skin changes were also seen along with nipple discharge. Strikingly, nipple retraction was also seen in a small subset of cases. Lump with inflamed skin together with skin changes gave a false suspicion of malignancy that was ruled out in cytological study. Despite an ongoing inflammatory process, systemic manifestations of inflammation like fever were seen in just one case of this study.

Treatment and management of granulomatous and inflammatory mastitis pose a major challenge to clinicians. Due to the low incidence and prevalence of these cases, along with the lack of randomized control studies,³ the management of GM is controversial. If there is a definitive infective etiology such as tubercle bacilli or corynebacteria, the therapy may be initiated along the lines of antitubercular therapy and others. In idiopathic cases, there are proposed regimens such as antibiotics and corticosteroids.^{12,13} In treatment-resistant cases, surgical procedures such as wide local excision of the lesion may be done,¹⁴⁻¹⁶ depending on available resources, patients' expectations, and surveillance opportunities.

Limitations of this study

The study is limited by relatively small sample size during the study period. Retrospective study design is another limiting factor that made follow-up of cases of granulomatous/inflammatory mastitis difficult. A study of longer duration with a bigger sample size with prospective follow-up of cases to determine therapeutic strategies may be undertaken to address this problem in the future.

CONCLUSION

FNAC is an important hassle-free, painless, minimally-invasive procedure to diagnose breast lumps. The cytological diagnosis may be varied ranging from benign fibroadenomas to ductal carcinomas. There is a small subset of population showing granulomatous and inflammatory mastitis, few with *M. tuberculosis* as the known offending agent. Granulomatous/inflammatory mastitis may have varied clinical manifestations, with few mimicking like inflammatory breast carcinomas. Radiology may also be dubious giving a false impression of neoplastic process. Cytology followed by biopsy is the gold-standard investigation for confirmatory opinion. There is diverse school of thoughts regarding the treatment and management of these cases due to paucity of literature in this regard. Medical therapies such as antibiotics and corticosteroids and surgery in treatment-resistant cases are plausible modalities.

ACKNOWLEDGMENT

I would sincerely like to thank all the co-authors for their intellectual contributions toward completion of this paper. They have not produced this work in any form on any other platform and have committed to the submission of this case for publication in this journal.

REFERENCES

- Morris KT, Pommier RF, Morris A, Schmidt WA, Beagle G, Alexander PW, et al. Usefulness of the triple test score for palpable breast masses; discussion 1012-3. *Arch Surg.* 2001;136(9):1008-1012.
<https://doi.org/10.1001/archsurg.136.9.1008>
- Ahmed R and Sultan F. Granulomatous mastitis: A review of 14 cases. *J Ayub Med Coll Abbottabad.* 2006;18(1):52-54.
- Wolfrum A, Kümmel S, Theuerkauf I, Pelz E and Reinisch M. Granulomatous mastitis: A therapeutic and diagnostic challenge. *Breast Care (Basel).* 2018;13(6):413-418.
<https://doi.org/10.1159/000495146>
- Freeman CM, Lewis JD, Lower EE, Khan S, Shaughnessy E. Refractory granulomas of breast: Benign or malignant disease. *J Clin Oncol.* 2014;32(26):21.
- Prasad S, Jaiprakash P, Dave A and Pai D. Idiopathic granulomatous mastitis: an institutional experience. *Turk J Surg.* 2017;33(2):100-103.
<https://doi.org/10.5152/turkjsurg.2017.3439>
- Tirpude BH, Annamwar A, Gajbhiye R and Deshpande G. A descriptive study of chronic granulomatous mastitis in Central India. *Int Surg J.* 2022;9(10):1715-1719.
<https://doi.org/10.18203/2349-2902.isj20222595>
- Gangopadhyay M, De A, Chakrabarti I, Ray S, Giri A and Das R. Idiopathic granulomatous mastitis-utility of fine needle aspiration cytology (FNAC) in preventing unnecessary surgery. *J Turk Ger Gynecol Assoc.* 2010;11(3):127-130.
<https://doi.org/10.5152/jtgga.2010.18>
- Halder A, Bhattacharya S, Bhattacharya S and Banerjee TJ. Role of fine-needle aspiration cytology as an inexpensive tool for diagnosis of idiopathic granulomatous mastitis. *Hamdan Med J.* 2023;16(3):226-229.
https://doi.org/10.4103/hmj.hmj_42_23
- Taylor GB, Paviour SD, Musaad S, Jones WO and Holland DJ. A clinicopathological review of 34 cases of inflammatory breast disease showing an association between corynebacteria infection and granulomatous mastitis. *Pathology.* 2003;35(2):109-119.
- Wilson E, Woodd SL and Benova L. Incidence of and risk factors for lactational mastitis: A systematic review. *J Hum Lact.* 2020;36(4):673-686.
<https://doi.org/10.1177/0890334420907898>
- Grover H, Grover SB, Goyal P, Hegde R, Gupta S, Malhotra S, et al. Clinical and imaging features of idiopathic granulomatous mastitis - the diagnostic challenges and a brief review. *Clin Imaging.* 2021;69:126-132.
<https://doi.org/10.1016/j.clinimag.2020.06.022>
- DeHertogh DA, Rossof AH, Harris AA, Economou SG. Prednisone management of granulomatous mastitis. *N Engl J Med.* 1980;303(14):799-800.
<https://doi.org/10.1056/NEJM198010023031406>
- Freeman CM, Xia BT, Wilson GC, Lewis JD, Khan S, Lee SJ, et al. Idiopathic granulomatous mastitis: A diagnostic and therapeutic challenge. *Am J Surg.* 2017;214(4):701-706.
<https://doi.org/10.1016/j.amjsurg.2017.07.002>
- Calis H and Karabeyoglu SM. Follow-up of granulomatous mastitis with monitoring versus surgery. *Breast Dis.* 2017;37(2):69-72.
<https://doi.org/10.3233/BD-160259>
- Ozel L, Unal A, Unal E, Kara M, Erdoğdu E, Krand O, et al. Granulomatous mastitis: Is it an autoimmune disease? Diagnostic and therapeutic dilemmas. *Surg Today.* 2012;42(8):729-733.
<https://doi.org/10.1007/s00595-011-0046-z>
- Bashir MU, Ramcharan A, Alothman S, Beaugris A, Khan SA, Sbeih MA, et al. The enigma of granulomatous mastitis: A series. *Breast Dis.* 2017;37(1):17-20.
<https://doi.org/10.3233/BD-160261>

Authors' Contributions:

PN- Definition of intellectual content, coordination and manuscript revision, preparation of figures; **MM**- Literature survey and preparation of figures, collection of cases, coordination and manuscript revision, prepared first draft of manuscript, submission of article; **SM**- Definition of intellectual content, manuscript preparation, coordination, and manuscript revision.

Work attributed to:

Department of Pathology, Jhargram Government Medical College and Hospital

Orcid ID:

Pamela Nayak - <https://orcid.org/0000-0003-2088-4846>
Meghadipa Mandal - <https://orcid.org/0000-0002-6972-1100>
Srishidhar Mangal - <https://orcid.org/0000-0001-9706-7081>

Source of Support: Nil, **Conflicts of Interest:** None declared.