

Twist and turn of an unusual entity: A rare case report of torsion of huge epididymal cyst from a tertiary hospital



Manojit Sarkar¹, Arup Kumar Ghosh², Purnendu Dutta³, Amit Ray⁴

¹Senior Resident, ^{2,3}Assistant Professor, ⁴Professor, Department of Surgery, Burdwan Medical College and Hospital, Purba Bardhaman, West Bengal, India

Submission: 29-05-2024

Revision: 03-06-2024

Publication: 01-08-2024

ABSTRACT

An epididymal cyst (EC) is a benign lesion. It arises due to cystic degeneration of the epididymis. The torsion of it is extremely rare. The usual presentation of the cyst is asymptomatic scrotal swelling. The swelling has a lobulated surface and feels like a bunch of grapes. The huge EC is rare and moreover, it is associated with torsion-rarest presentation.

Key words: : Epididymal cyst; Management, Transillumination; Torsion

Access this article online

Website:

<http://nepjol.info/index.php/AJMS>

DOI: 10.3126/ajms.v15i8.66369

E-ISSN: 2091-0576

P-ISSN: 2467-9100

Copyright (c) 2024 Asian Journal of Medical Sciences



This work is licensed under a Creative Commons Attribution-NonCommercial 4.0 International License.

INTRODUCTION

A fluid-filled sac made of serous fluid that emerges from the epididymis is called an epididymal cyst (EC) or spermatocele. Males in their middle age are usually affected. While their occurrence is uncommon, they are often benign and unilateral in character.¹ There are incredibly few examples of multilocular big EC torsion that have been documented up to this point.² Fewer men have greater spermatoceles than the estimated 30% of men with minor spermatoceles. The age of the men affects the occurrence of spermatocele.³ If the cysts are bigger than 10 mm or 1 cm, surgery is necessary. If not, cautious management is suggested. We are presenting a unique case report of an adult with torsion of enormous multilocular ECs.

CASE REPORT

A 46-year-old male patient presented with acute scrotal pain with huge swelling in an emergency. The swelling was gradually progressive and painless. However, there was a sudden onset of excruciating pain and the patient came to an emergency.

Emergency ultrasound (Figure 1a) color Doppler scrotum showed that the testes were normal with homogeneous arterial perfusion, 15×8 cm well-defined cyst with few internal echoes pushing the right testis toward the left, and many septations without internal vascularity. We were planning it for emergency exploration as the pain had not subsided even after medication.

Address for Correspondence:

Dr. Amit Ray, Professor, Department of Surgery, Burdwan Medical College and Hospital, Purba Bardhaman - 713 104, West Bengal, India.

Mobile: +91-7001304457. **E-mail:** msmanojit94@gmail.com

During the operation, both the testes were found normal. A huge cyst was found within the caput epididymis and it had torsion of 360° anti-clockwise (Figure 1b) on its own pedicle. Detorsion followed by excision of the cyst was done. A post-operative transillumination test was done and it was brilliantly transilluminant (Figure 2a). On aspiration crystal clear fluid came out. The histopathological diagnosis (Figure 3) was EC with no necrosis in the cells of the epididymal duct. The patient was discharged on 3rd post-operative day and post-operative period was uneventful.

DISCUSSION

ECs are benign lesions. It arises due to cystic degeneration of the epididymis. An EC is a fluid collection in either a single (unilocular) or more than one sac (multilocular) due to efferent epididymal tubule dilatation as a result of tubular obstruction. Multilocularity of EC is rarer and rarely reported in the literature.

Furthermore, ECs can be symptomatic and can present with variable clinical presentations. A patient may narrate scrotal swellings as a third testicle.

They may also present with testicular pain or orchialgia. Moreover, the torsion of huge EC is extremely rare. The usual presentation of the cyst is asymptomatic scrotal swelling. The swelling has a lobulated surface and feels like a bunch of grapes.

On clinical examination, the EC is palpated as an extra testicular mass, usually smooth, round, and characteristically located adjacent to the testis. These ECs are translucent in appearance since they contain clear fluid in them, but in some cases, it appears to be turbid due to the presence of spermatozoa within them. The huge EC is rare and moreover, it is associated with torsion. In our patient, the size of the cyst was found to be larger as compared to the other similar reported cases.³

An ultrasound examination was done to confirm the diagnosis. Ultrasound helps to determine the location, site of origin, content of the cyst, size, shape, and vascularity of the testes.⁴ The head of the epididymis is identified as the most common site of origin of the cyst.

Treatment options for ECs depend on the patient's presentation, symptoms, and clinical findings. Most of the EC involute with time. Conservative management is sclerotherapy, aspiration of the cyst, etc. The surgical modality is used when the patient presents with acute symptoms, such as acute scrotal or inguinal pain, scrotal swelling, and redness.

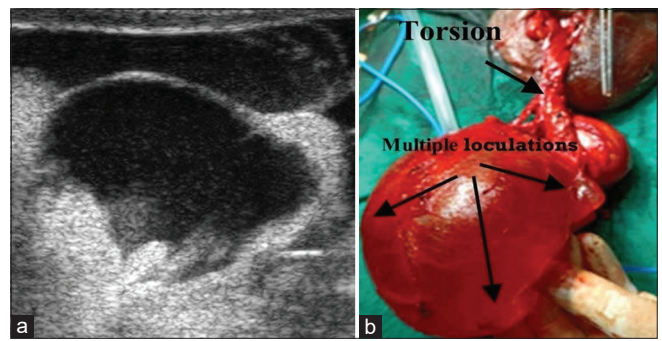


Figure 1: (a) USG scrotum shows a huge epididymal cyst, (b) Huge multiloculated cyst with torsion

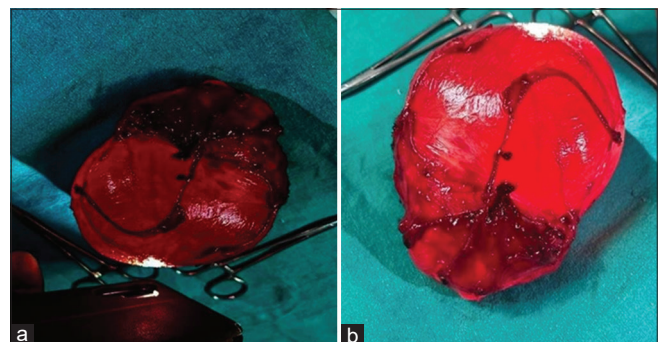


Figure 2: (a) Transillumination test- brilliantly transilluminant, (b) Post-operative specimen showing multiple lobules

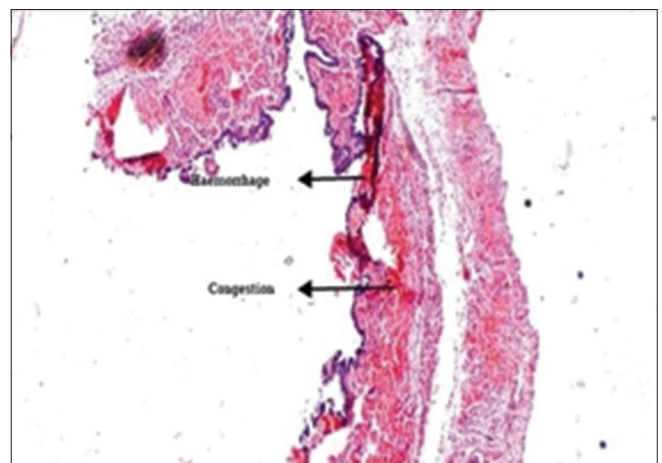


Figure 3: Histopathological examination (low power views) of the epididymal cyst wall with columnar epithelium showing congestion and hemorrhage

Surgery is indicated when the cyst is larger than 10 mm or 1 cm and does not involute with time. In our case, we were planning for emergency exploration as the pain had not subsided even after medication.

During the operation, both the testes were found normal. A huge cyst found within caput epididymis it had torsion of 360° anti-clockwise on its own pedicle. Detorsion followed by excision of the cyst was done. A post-operative transillumination test was done and it was brilliantly

transilluminant. On aspiration crystal clear fluid came out. The histopathological diagnosis was EC with no necrosis in the cells of the epididymal duct. The patient was discharged on 3rd post-operative day and post-operative period was uneventful.

CONCLUSION

Conservative management remains the initial choice of treatment for asymptomatic EC with a size measuring <1 cm, while surgical modality is the only mainstay of treatment for patients with acute symptomatology like intractable scrotal pain, swelling, and redness, and also when the size of the cyst does not regress on its own but instead increases with time. From this rare case presentation, we would like to conclude that while dealing with the case of huge scrotal swelling we should also keep in mind about the differential diagnoses, such as pyocele,

testicular neoplasm, and EC. It is also very challenging to deal with the torsion of a huge EC.

REFERENCES

1. Fernández-Ibieta M, Villalon-Ferrero F and Ramos-García JL. Benign scrotal tumor in a pediatric patient: Epididymal Cyst. *Case Rep Urol*. 2018;2018:1635635. <https://doi.org/10.1155/2018/1635635>
2. Ushida H, Hayashida H, Kim CJ, Park KI and Okada Y. Bilateral synchronous multilocular epididymal cysts: A case report. *Jpn J Urol*. 1999;90(7):692-695. <https://doi.org/10.5980/jpnjurol1989.90.692>
3. Akin Y, Sarac M, Basara I, Yucel S and Kazez A. Bilateral epididymal cyst in 14-year-old boy: A case report. *J Health Sci*. 2014;4(1):68-71. <https://doi.org/10.17532/jhsci.2014.150>
4. Finkelstein MS, Rosenberg HK, Snyder HM 3rd and Duckett JW. Ultrasound evaluation of scrotum in pediatrics. *Urology*. 1986;27(1):1-9. [https://doi.org/10.1016/0090-4295\(86\)90196-2](https://doi.org/10.1016/0090-4295(86)90196-2)

Authors' Contributions:

MS- Concept, design, and material preparation and resident in charge, **AKG**- Proofreading, **PD**- Data analysis and data collection, and **AR**- Revision, drafting, and final approval.

Work attributed to:

Burdwan Medical College and Hospital, Purba Bardhaman, West Bengal, India.

Orcid ID:

Dr. Manojit Sarkar - <https://orcid.org/0009-0003-1580-8213>

Dr. Arup Kumar Ghosh - <https://orcid.org/0009-0009-8237-2951>

Dr. Purnendu Dutta - <https://orcid.org/0009-0002-5037-0539>

Dr. Amit Ray - <https://orcid.org/0000-0001-8548-1306>

Source of Support: Nil, **Conflicts of Interest:** None declared.