

Littoral cell angioma: An incidental finding in a traumatic spleen



Madhurima Das¹, Rupsha Dutta Pal², Dwaipayan Samaddar³, Jaya Bagchi Samaddar⁴, Bidyut Krishna Goswami⁵

¹2nd Year Postgraduate Trainee, ²Assistant Professor, ⁴Demonstrator, ⁵Professor and Head, Department of Pathology, ³Associate Professor, Department of Surgery, North Bengal Medical College and Hospital, Siliguri, West Bengal, India

Submission: 22-12-2023

Revision: 26-01-2024

Publication: 01-03-2024

ABSTRACT

Littoral cell angioma (LCA) of the spleen, a rare vascular tumor, is usually asymptomatic, often discovered incidentally and a majority of them are benign in nature. A 20-year-old boy with a history of blunt abdominal trauma, who underwent splenectomy showed the presence of a capsular tear and variegated outer surface on gross examination of the spleen. On the cut section, multiple nodular areas with areas of hemorrhage were noted. Microscopical examination revealed the proliferation of anastomosing, irregular, tortuous blood-filled channels with plenty of histiocytes in the splenic tissue and extensive areas of hemorrhage, inflammatory cell infiltration, and fibrinoid deposits. Immunohistochemistry revealed positivity for CD31 (endothelial differentiation), CD68, and lysozyme (histiocytic differentiation) but was negative for CD34. The final diagnosis was LCA in a case of ruptured spleen after ruling out angiosarcoma. The possibility of this benign entity to have contributed to the potentially fatal splenic injury cannot be overlooked.

Key words: Littoral angioma; Spleen; Trauma; Immunohistochemistry

Access this article online

Website:

<http://nepjol.info/index.php/AJMS>

DOI: 10.3126/ajms.v15i3.60970

E-ISSN: 2091-0576

P-ISSN: 2467-9100

Copyright (c) 2024 Asian Journal of Medical Sciences



This work is licensed under a Creative Commons Attribution-NonCommercial 4.0 International License.

INTRODUCTION

Littoral cell angioma (LCA) of the spleen, a rare vascular tumor was first described by Falk et al., in 1991.¹ It is usually asymptomatic and is often discovered incidentally. Clinically, a majority of the LCAs described in the literature have been found to be benign in nature but rare metastasizing cases have also been described.² Definite diagnosis of LCA can only be made by histopathological examination after splenectomy, which is usually performed because of the concern for malignancy.

Pathologically, LCA is a vascular tumor of the spleen that represents a tumoral counterpart of the normally present littoral cells that line the splenic sinus channels of the red pulp. The endothelial cells lining the channels are tall and

plump compared to the flat endothelial cells lining the channels in a normal spleen.³ Sometimes, trivial trauma might lead to disproportionate splenic injury due to the presence of asymptomatic LCA and our case report is a perfect example in this regard.

CASE REPORT

A 20-year-old boy presented to the Emergency Department of NBMCH with complaints of left upper abdominal pain following minor scuffles with friends. eFAST revealed a gross collection of fluid in the hepatorenal recess, splenorenal recess, and pelvis. USG showed multiple hyperechoic heterogenous areas in the spleen. Pre-operative hematological investigations were within normal limits. A decision of exploratory laparotomy was made and splenectomy was performed. The specimen was

Address for Correspondence:

Dr. Jaya Bagchi Samaddar, K 4, 100 Pearls, Jyotinagar, Zilla Parishad Road, Siliguri - 734 001, West Bengal, India.

Mobile: +91-9564779777. **E-mail:** jbsam_ae@yahoo.com

sent to the department of pathology for histopathological examination.

On gross examination, the spleen measured 12×9.5×3 cm³ and weighed 80 g with the presence of capsular tear and variegated outer surface. On the cut section, multiple nodular areas were noted along with areas of hemorrhages. Microscopical examination revealed anastomosing vascular channels with large cyst formations which were lined predominantly by tall, histiocytoid cells projecting into the vascular spaces in papillary fashion along with interspersed flat endothelial cells in addition to extensive areas of hemorrhages, inflammatory cell infiltration, and fibrinoid deposits (Figure 1a-c).

Immunohistochemistry (IHC) showed strong and intense cytoplasmic and membranous positivity for CD31 in neoplastic endothelial cells. CD34 was positive in normal endothelial cells. CD68 and lysozyme (histiocytic differentiation) showed positivity in neoplastic cells (Figure 2a-d).

The final diagnosis was LCA in a case of ruptured spleen.

DISCUSSION

LCA is a rare vascular tumor which affects both men and women equally.³ LCA has a good prognosis except

in cases of malignant transformation which is usually seen with splenomegaly.⁴ In our case, the spleen was within normal limits and microscopic studies pointed toward a benign pathology. It is most often found incidentally as a splenic mass on abdominal imaging. Rarely, it may be detected accidentally with splenic rupture and hemoperitoneum after trauma.⁵ The sonographic appearance of LCA is variable and ranges from hypoechoic to a hyperechoic mass with a mottled texture.³ Imaging such as a CT scan often guides us to a diagnosis. However, in our case, no CT scan was done owing to the emergency associated with the rupture of the spleen. The differential diagnosis of lesions that can mimic LCA on imaging includes lymphangioma, hamartoma, lymphoma, Kaposi's sarcoma, and hemangioma.³ Therefore, a definitive diagnosis can only be obtained by microscopic examination of the biopsy specimen. There may be associated hematological symptoms such as anemia and/or thrombocytopenia along with complaints of splenomegaly.¹ No such finding was present in our case. One of the most important tools for confirmation of this diagnosis is IHC. LCA has a combined pattern of endothelial and histiocytic cells. Endothelial markers are FVIII, CD31, vWF, and CD34 whereas histiocytic markers are CD68 and lysozyme. The IHC results of our patient were positive for endothelium (CD31+) and histiocyte (CD68+ and lysozyme+) thus confirming our

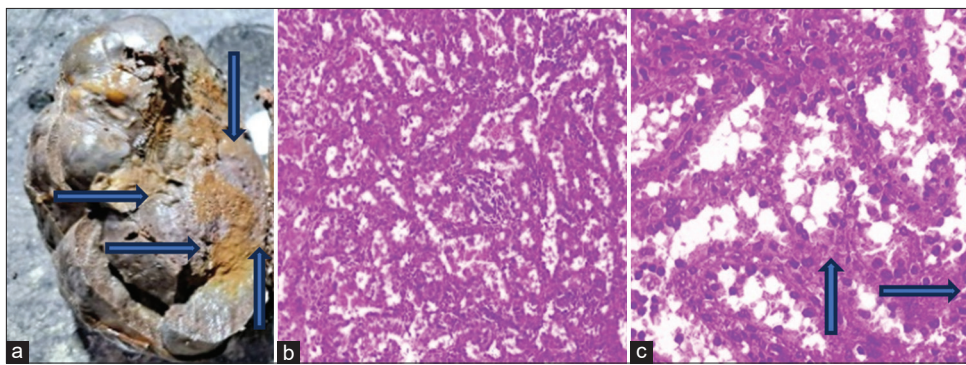


Figure 1: (a) Gross section of the spleen with hemorrhagic areas (blue arrows); (b) Proliferating anastomosing endothelial lined vascular channels (HPE, 10x); (c) Same section depicting hobnailing (blue arrows) of endothelial cells (HPE, 40x)

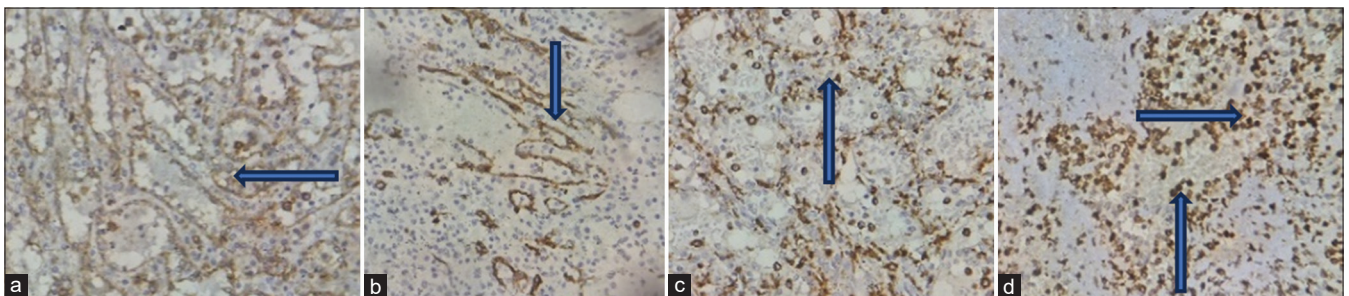


Figure 2: IHC (40x) of (a) CD 31 showing cytoplasmic and membranous positivity in neoplastic endothelial cells (blue arrow); (b) CD 34 showing positivity in non-neoplastic cells (blue arrow); (c and d) CD68 and lysozyme showing positivity in neoplastic cells demonstrating histiocytic differentiation (blue arrows)

diagnosis. CD34 was positive in normal endothelial cells. High expression of formin homology domain protein 1 (FHOD1) by normal littoral cells helps to distinguish them from LCA which does not express it.³

CONCLUSION

The histopathological and IHC findings reflect the dual differentiation potential of the reticuloendothelial cells lining the splenic sinus, justifying the term LCA. Though a rare incidental histopathological finding its presence can lead to potentially fatal hemorrhage from trivial trauma.

ACKNOWLEDGMENT

All the technical staff of the Department of Pathology, North Bengal Medical College and Hospital.

REFERENCES

1. Falk S, Stutte HJ and Frizzera G. Littoral cell angioma. A novel splenic vascular lesion demonstrating histiocytic differentiation. *Am J Surg Pathol.* 1991;15(11):1023-1033.
2. Abbott RM, Levy AD, Aguilera NS, Gorospe L and Thompson WM. From the archives of the AFIP: Primary vascular neoplasms of the spleen: Radiologic-pathologic correlation. *Radiographics.* 2004;24(4):1137-1163.
<https://doi.org/10.1148/rg.244045006>
3. Bailey A, Vos J and Cardinal J. Littoral cell angioma: A case report. *World J Clin Cases.* 2015;3(10):894-899.
<https://doi.org/10.12998/wjcc.v3.110.894>
4. Roldan-Vasquez E, Roldan-Vasquez A, Jarrin-Estupiñan X and Roldan-Crespo J. Case report: Infrequent littoral cell angioma of the spleen. *Int J Surg Case Rep.* 2021;85:106242.
<https://doi.org/10.1016/j.ijscr.2021.106242>
5. Arcuri PP, Taglianetti S, Vavalà B, Battaglia C, Laganà D and Manti F. Incidental littoral cell angioma of the spleen: Cross-sectional imaging findings and review of the literature. *Radiol Case Rep.* 2022;17(10):3545-3550.
<https://doi.org/10.1016/j.radcr.2022.06.063>

Authors' Contributions:

MD- Concept, ethical protocol maintenance, and photography; **RDP**- Data collection and maintenance of records of results and proof editing; **DS**- Patient check-up and follow-up; **JBS**- Concept, manuscript writing, and supervision in totality; **BKG**- Concept, review of literature and research.

Work attributed to:

North Bengal Medical College and Hospital, Sushrutanagar, Darjeeling.

Orcid ID

Dr. Madhurima Das - <https://orcid.org/0009-0008-7767-0324>
 Dr. Rupsha Dutta Pal - <https://orcid.org/0009-0001-6480-8696>
 Dr. Dwaipayan Samaddar - <https://orcid.org/0000-0002-5513-9494>
 Dr. Jaya Bagchi Samaddar - <https://orcid.org/0000-0003-4905-8820>
 Dr. Bidyut Krishna Goswami - <https://orcid.org/0000-0003-4806-5949>

Source of Support: Nil, **Conflicts of Interest:** None declared.