

Temporomandibular joint ankylosis - An anesthesiologist's nightmare: Case series



Priyanka Bansal¹, Nidhi Sultania², Amrish Bhagol³

¹Associate Professor, ²Senior Resident, Department of Anaesthesia, ³Professor, Department of Oral and Maxillofacial Surgery, PT BD Sharma PGIMS, Rohtak, Haryana, India

Submission: 01-11-2023

Revision: 20-01-2024

Publication: 01-03-2024

ABSTRACT

Temporomandibular joint (TMJ) ankylosis is defined as bony or fibrous adhesion of the anatomic joint components accompanied by a limitation in opening the mouth. Airway management is a grueling task and has confronted anesthesiologists ever since. The challenge is even more exaggerated when it is a pediatric patient. We present a case series of five pediatric patients with TMJ ankylosis with age 7 years or less, who were posted for its corrective surgery. Although all patients belonged to the pediatric age group, the challenges faced and techniques employed to overcome them were different partly because of different age groups and partly the nature of the airway, with tailoring of each technique accordingly. Pediatric airway management is no less than waging a war as all necessary skills and expertise are put to the test. It combines fortuity with skills. We have to be prepared for the worst in any unforeseen scenario.

Key words: Temporomandibular joint ankylosis; Pediatric; Fiberoptic intubation

Access this article online

Website:

<http://nepjol.info/index.php/AJMS>

DOI: 10.3126/ajms.v15i3.59640

E-ISSN: 2091-0576

P-ISSN: 2467-9100

Copyright (c) 2024 Asian Journal of Medical Sciences



This work is licensed under a Creative Commons Attribution-NonCommercial 4.0 International License.

INTRODUCTION

Temporomandibular joint (TMJ) ankylosis is defined as bony or fibrous adhesion of the anatomic joint components accompanied by a limitation in opening the mouth. Airway management is a grueling task and has confronted anesthesiologists ever since. More so, the pediatric airway gives goosebumps because of major anatomical disparities as compared to adults. The problem is further aggravated if a major airway joint, i.e., TMJ mobility is restricted. The most significant clinical indicator of the degree of restriction is the interincisor distance which if <5 mm amounts to complete ankylosis. Trauma is the most common cause of TMJ ankylosis (13–100%) followed by infection (10–49%).¹ In pediatrics, it presents as almost nil mouth opening and is a candidate for a difficult airway. Its correction is required at the earliest in children keeping in view increased chances of feeding and speech difficulty, developmental delay, and bird face deformity with growing age.

CASE PRESENTATION

We present a case series of five pediatric patients with TMJ ankylosis who were posted for its corrective surgery (Table 1). Written informed consent was taken from the patients for the publication of data. Although all patients belonged to the pediatric age group, the challenges faced and methods employed to overcome them were different partly because of different age groups and partly the degree of mouth opening, with tailoring of each technique accordingly. Appropriate consent as well as preparation for the “cannot intubate cannot ventilate” situation in the form of front-of-neck access was done before all cases.

Case 1

In the first case, a preanesthetic checkup revealed a mouth opening of 2.2 cm. No other comorbidity is present. Birth history was normal. There was a history of fall

Address for Correspondence:

Dr. Priyanka Bansal, Associate Professor, Department of Anaesthesia, PT BD Sharma PGIMS, Rohtak, Haryana, India.

Mobile: +91-8683921867. **E-mail:** dr.priyankabansal1986@gmail.com

Table 1: Patient details along with management

Variable	Case 1	Case 2	Case 3	Case 4	Case 5
Age (years)	5	2.8	7	2.4	7
Associated abnormality	-	Suppurative otitis media	Goldenhar syndrome	-	-
Probable etiology	Trauma (fall)	Infection	Congenital	Trauma (forceps delivery)	Unknown
Airway					
Mouth opening	2.2 cm	<2 mm	<2 mm	<4 mm	<5 mm
Neck movements	n	n	Flexion restricted	n	n
Mode of intubation	Video laryngoscope Mc Grath with nasal intubation	FOB with an inhalational agent	FOB with IV agent	FOB through 1 nostril and ETT through the other nostril with an inhalational agent	Blind nasal with topical anesthesia

FOB: Fiberoptic bronchoscope, ETT: Endotracheal tube

from height at the age of 1 year. Gap arthroplasty was planned. Videolaryngoscopy using Mc Grath was planned as the patient had adequate mouth opening for video laryngoscopy and anticipated difficult intubation. Adequate nasal preparation with xylometazoline nasal drops was done preoperatively. The patient was premedicated with injection glycopyrrolate 0.005 mg/kg iv, injection fentanyl 2 mcg/kg iv, and injection midazolam 0.02 mg/kg iv along with sevoflurane inhalation. Anesthesia was induced with sevoflurane to maintain spontaneous ventilation and after attaining a minimum alveolar concentration 1.3 video laryngoscopy was done. After identifying the cords, ETT size 5 uncuffed was passed through a more patent nostril and guided through a video laryngoscope under its vision. Intubation was successful in the first attempt.

Case 2

The preoperative examination was significant in terms of mouth opening <2 mm. The oral hygiene was poor. The birth history was normal. There was a history of suppurative otitis media in the past. The patient was quite agitated preoperatively. Sevoflurane induction was started and the iv cannula had to be resecured, as the child had displaced the cannula in situ. Injection glycopyrrolate 0.005 mg/kg iv was given. Sternal retractions were observed because of inadequate ventilation. Therefore, a small-size-cut endotracheal tube nasal airway was inserted through a less patent nostril. Immediately, adequate ventilation was achieved. Injection fentanyl 1 mcg/kg iv was given. Pediatric fibroscope Karl Storz 3.7 mm with ETT 4.5 railroaded was inserted through other nostril, and intubation was done.

Case 3

The patient was a diagnosed case of Goldenhar syndrome with microtia and multiple mandibular cysts, without any other associated abnormality. The patient was taken to the operating theater table after adequate nasal preparation with xylometazoline drops. After securing an intravenous cannula, injection glycopyrrolate 0.005 mg/kg iv, injection ketamine 0.5 mg/kg iv, and injection midazolam 0.02 mg/kg

IV were given. Oxygenation started with a face mask. The patient was breathing spontaneously with adequate chest rise and bag movements (Figures 1 and 2). The bilateral superior laryngeal nerve block was given with 1cc of 2% lignocaine. The face mask was removed and cut endotracheal tube nasal airway was inserted through a less patent nostril and attached to the circuit. Fiberoptic intubation with endotracheal tube no 5.5 was done through the other nostril.

Case 4

There was a history of complications at birth with forceps delivery. Mouth opening was <4 mm. After adequate nasal preparation with xylometazoline drops in the preoperative area, the patient was brought to the operation theater table and sevoflurane induction was started. Injection glycopyrrolate 0.005 mg/kg and injection fentanyl 2 mcg/kg were given iv. After the adequate depth of anesthesia with spontaneous ventilation, endotracheal tube no. 4 was inserted through a more patent nostril, the circuit was attached and inhalational agent delivery was continued through it maintaining spontaneous ventilation and adequate depth of anesthesia. A nasal pediatric fibroscope 3.7 mm was inserted through the other nostril and after an adequate view of vocal cords, the tube in other nostril was guided under its vision. Intubation was successful in the first attempt.

Case 5

The patient had a history of previous surgery for the same 2 years back. No other comorbidity was present. After nasal preparation with xylometazoline drops, nebulization was started with 2 cc of 4% lignocaine in the preoperative area. The patient was taken on the operation theater table and premedicated with injection glycopyrrolate 0.005 mg/kg iv, fentanyl 1 mcg/kg iv. A bilateral superior laryngeal nerve block was given with 2 cc of 2% lignocaine. Endotracheal tube no. 5.5 was inserted through patent nostril and attached to the circuit with monitoring of bag movements. The tube was slowly advanced and the patient was asked to vocalize intermittently taking deep breaths. At a stage

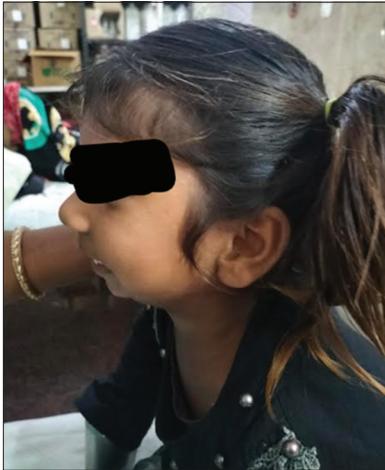

Figure 1: Temporomandibular joint ankylosis with very less mouth opening

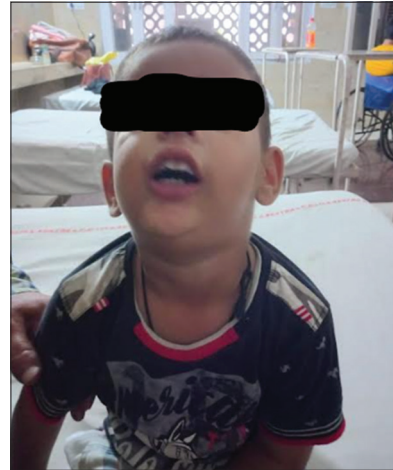

Figure 4: 2 years 4 months child with temporomandibular joint ankylosis

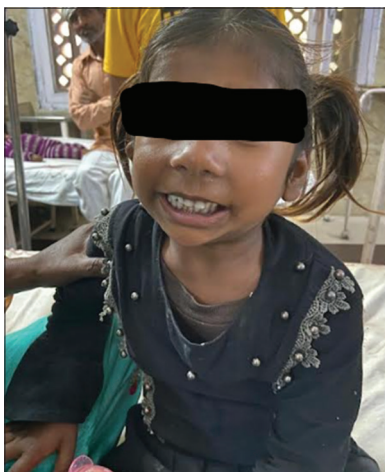

Figure 2: Mouth opening <2 mm

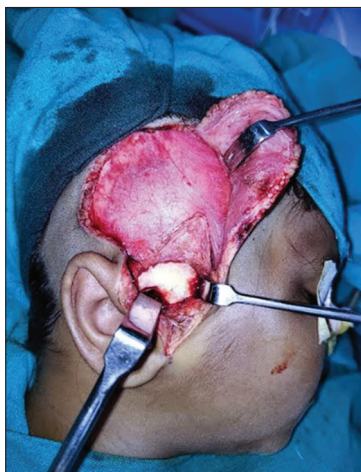


Figure 3: Question mark incision for temporomandibular joint ankylosis

when bag movements increased injection of lignocaine 1cc was put in ETT, after waiting for 30 sec tube was advanced with continuous monitoring of bag movements.

The intubation was successful in the second attempt. Tracheal intubation was confirmed with ETCO₂ tracing and injection of propofol 2 mg/kg iv was given followed by a muscle relaxant.

DISCUSSION

Among the various options available for intubation in TMJ ankylosis patients are intubation using a flexible fibroscope, retrograde intubation, and blind nasal intubation and more recently the use of videolaryngoscope has been advocated in children. Myriad of options and procedure details have been eloquently covered in the literature to handle such cases but not at such a juvenile age. The assessment of the airway in these patients is possible only on the basis of external features such as limited mouth opening, facial dysmorphism, and retrognathia leading to limited submandibular space. Even the bag-mask ventilation can be arduous because chin lift and jaw thrust which specifically involve movement around TMJ, are not possible in such cases. Among our patients, bag-mask ventilation was difficult in Case 4.

Taking into account the degree of TMJ mobility limitation, Sawhney divided TMJ ankylosis into 4 types:²

- Type I: The head of the condylar process is visible but significantly deformed, with the fibroadhesions making TMJ movement impossible
- Type II: Consolidation of the deformed head of the condylar process and articular surface occurs mostly at the edges and in the anterior and posterior parts of the structures, and the medial part of the surface of the condylar head remains undamaged
- Type III: The ankylotic mass involves the mandibular ramus and zygomatic arch; an atrophic and displaced fragment of the anterior part of the condylar head is in a medial location

- Type IV: TMJ is completely obliterated by a bony ankylotic mass growing between the mandibular ramus and cranial base.

The most predictable treatment for the ankylosed TMJ patient includes the release of the ankylosed joint; removal of the heterotopic and reactive bone with thorough debridement of the TMJ and adjacent areas; reconstruction of the TMJ with a patient-fitted total joint prosthesis (TMJ Concepts system) (Figure 3); ipsilateral coronoidotomy or coronoidectomy if the ramus is significantly advanced or vertically lengthened with the prosthesis.^{3,4}

In our first case, videolaryngoscopy was opted in view of adequate mouth opening but anticipated difficult visualization of vocal cords, due to retrognathia and pseudo macroglossia that narrows down the pharyngeal space. In an article by Sinha et al., they have demonstrated the successful use of video laryngoscope C Mac in the pediatric patient with a simulated cervical spine injury.⁵ The successful use of Mc Grath has been demonstrated by Ross and Baxter in a 36-week-old neonate.⁶ Disparity in the exchange of gases leads to difficulty in ventilation and hypoxemia. This is more common in patients with a history of OSA but the present patient did not had this history. The suprahyoid muscle length and tone along with associated jaw deformities makes the ventilation difficult and risky. Direct laryngoscopy is impossible because of limited mouth opening, if possible visualization of vocal cords is inexpedient. Hence, videolaryngoscope as in Case 1.

Awake fiberoptic intubation is not possible in pediatric patients and hence for Case 2, Sevoflurane induction was used followed by watchful chest rise. There were sternal retractions during spontaneous breathing for which nasopharyngeal airway was introduced. The minimum size ETT that could be threaded through the size 3.7 mm fibroscope was 4.5 (ID) which just passed snugly through the glottis. We were fortunate in this regard as we had only this size fibroscope as the smallest size available. Intravenous sedation in 8–18 years has been described with fentanyl/midazolam along with a cocktail infiltration of the anesthetic agent along the surgical site.⁷ A colossal cooperation is required from the patient end. The point which was not present in our case. We opted for sevoflurane induction along with iv fentanyl in Case 2.

Syndromes that can be associated with TMJ ankylosis are Treacher–Collin Syndrome, Goldenhar Syndrome, Proteus, Morquio, etc.⁸ Our patient had features of Goldenhar syndrome with TMJ ankylosis, microtia along multiple mandibular cysts. After IV induction with ketamine and midazolam, a bilateral superior laryngeal nerve block was given. Various other IV induction agents have been

described such as propofol, thiopentone, dexmedetomidine, or a combination of these.

The diameter of our pediatric fibroscope is 3.7 mm through which an ETT size of 4.5 mm could be negotiated. Hence, FOB-guided visualization along with the nasal insertion of a tube through the opposite nostril was planned in Case 4. A similar technique has been described by Sharma et al., in a 5 years old child.⁹ Few more authors described a similar technique (Kundra et al., Fiadjoe and Stricker) (Figure 4).^{10,11} An innovative mind along with actual skills is a must before putting the conventional methods to the test.

Case 5 patient was quite cooperative in terms of anxiety. Nebulization of the airway along with bilateral superior laryngeal nerve blocks was given to prevent sudden laryngospasm during intubation. Blind nasal intubation is a controversial technique in view of chances of bleeding and edema due to repeated attempts along with the possibility of requirement of external maneuvering.¹² We were of utmost cautious and proceeded further only at the point of adequate bilateral chest movements with ETCO₂ tracing. A satisfactory topical preparation of the airway was done before the handling of the airway.

Limitations of the case series are obvious being less sample size, the superiority of one technique over the other could not be decided.

CONCLUSION

Pediatric airway management is no less than waging a war as all necessary skills and expertise are put to the test. It combines fortuity with skills. We have to be prepared for the worst in any unforeseen scenario. Pediatric airway with TMJ ankylosis is a path less treaded and further workup with better equipment and preparation is required, especially in age <2 years. Great minds and our learned readers are expected to contribute more toward this end.

ACKNOWLEDGMENT

None.

REFERENCES

1. Miyamoto H, Kurita K, Ogi N, Ishimaru J and Goss AN. The effect of an intra-articular bone fragment in the genesis of temporomandibular joint ankylosis. *Int J Oral Maxillofac Surg.* 2000;29(4):290-295.
[https://doi.org/10.1016/S0901-5027\(00\)80031-4](https://doi.org/10.1016/S0901-5027(00)80031-4)
2. Sawhney CP. Bony ankylosis of the temporomandibular joint: follow-up of 70 patients treated with arthroplasty and acrylic

- spacer interposition. *Plast Reconstr Surg.* 1986;77(1):29-40.
3. Goswami D, Singh S, Bhutia O, Baidya D and Sawhney C. Management of young patients with temporomandibular joint ankylosis-a surgical and anesthetic challenge. *Indian J Surg.* 2016;78(6):482-489.
<https://doi.org/10.1007/s12262-016-1551-5>
 4. Upadya VH, Bhat HK, Rao BH and Reddy SG. Classification and surgical management of temporomandibular joint ankylosis: A review. *J Korean Assoc Oral Maxillofac Surg.* 2021;47(4):239-248.
<https://doi.org/10.5125/jkaoms.2021.47.4.239>
 5. Sinha R, Ray BR, Sharma A, Pandey RK, Punj J, Darlong V and Trikha A. Comparison of the C-MAC video laryngoscope size 2 Macintosh blade with size 2 C-MAC D-Blade for laryngoscopy and endotracheal intubation in children with simulated cervical spine injury: A prospective randomized crossover study. *J Anaesthesiol Clin Pharmacol.* 2019;35(4):509-514.
https://doi.org/10.4103/joacp.JOACP_106_18
 6. Ross M and Baxter A. Use of the new McGrath® MAC size-1 paediatric videolaryngoscope. *Anaesthesia.* 2015;70:1217-1218.
<https://doi.org/10.1111/anae.13217>
 7. Montepara CA, Bortmas MR, Cochenour CJ, Fleming MK, Gaffey SH, McQuigg MA, et al. The effect of potassium supplementation and concomitant medications on potassium homeostasis for hospitalized patients. *J Clin Diagn Res.* 2012;6(10):1765-1767.
<https://doi.org/10.7860/JCDR/2012/3947.2605>
 8. Santos KC, Dutra ME, Costa C, Lascalea CA, Lascalea CE and De Oliveira JX. Aplasia of the mandibular condyle. *Dentomaxillofac Radiol.* 2007;36:420-422.
<https://doi.org/10.1259/dmfr/23852698>
 9. Sharma A, Dwivedi D and Sharma RM. Temporomandibular Joint Ankylosis: "A pediatric difficult airway management". *Anesth Essays Res.* 2018;12(1):282-284.
https://doi.org/10.4103/aer.AER_122_17
 10. Kundra P, Vasudevan A and Ravishankar M. Video assisted fiberoptic intubation for temporomandibularankylosis. *Paediatr Anaesth.* 2006;16(4):458-461.
<https://doi.org/10.1111/j.1460-9592.2005.01730.x>
 11. Fiadjoe J and Stricker P. Pediatric difficult airway management: current devices and techniques. *Anesthesiol Clin.* 2009;27(2):185-195.
<https://doi.org/10.1016/j.anclin.2009.06.002>
 12. Shetty SR, Bhandary A, Roy A and Shetty V. Anaesthetic management of temporomandibular joint ankylosis in paediatrics: A 5 year audit in a university hospital. *Sch J Appl Med Sci.* 2015;3:333-337.

Authors Contribution:

PB- Review of manuscript; **NS, PB, AB-** Concept and design, manuscript preparation; **AB, PB-** Revision of manuscript.

Work attributed to:

Department of Anaesthesia, PT BD Sharma PGIMS, Rohtak, Haryana, India.

Orcid ID:

Dr. Priyanka Bansal - <https://orcid.org/0000-0002-5900-401X>

Dr. Nidhi Sultania - <https://orcid.org/0009-0009-7616-7089>

Dr Amrish Bhagol - <https://orcid.org/0000-0001-5970-7957>

Source of Support: Nil, **Conflicts of Interest:** None declared.