

Novel triple injection technique - Avante garde for costoclavicular block. A Case series



Priyanka Bansal¹, Nidhi Sultania²

¹Associate Professor, ²Senior Resident, Department of Anesthesia, PT BD Sharma PGIMS, Rohtak, Haryana, India

Submission: 01-11-2023

Revision: 02-02-2024

Publication: 01-03-2024

ABSTRACT

Costoclavicular block has garnered the attention of regional anesthesia enthusiasts because the cords are snugly packed and consistently arranged in a particular pattern around the first part of the axillary artery. The single injection technique has been widely used conventionally, but the effect is unpredictable. The effect is unpredictable because of the septum that compartmentalizes cords in upper and lower compartments. We propose a triple injection technique targeting the individual cords separately. Onset time of sensory block from 16 min to 7 min. The average time for a complete motor block was 9.6 min. The chances of the median nerve sparing, as has been reported in some cases in previous studies, are almost nil by this technique—the corner pocket injection that involves the medial root of the median nerve and the lateral cord that is specifically blocked separately, covering the lateral root of the median nerve. The costoclavicular block has already carved a niche as an excellent choice for surgeries of the upper limb involving the elbow or below the elbow. The use of the triple injection technique makes the block effect more predictable and reliable.

Key words: Costoclavicular block, triple injection, motor

Access this article online

Website:

<http://nepjol.info/index.php/AJMS>

DOI: 10.3126/ajms.v15i3.59639

E-ISSN: 2091-0576

P-ISSN: 2467-9100

Copyright (c) 2024 Asian Journal of Medical Sciences



This work is licensed under a Creative Commons Attribution-NonCommercial 4.0 International License.

INTRODUCTION

Sparing the phrenic nerve has always been a matter of concern. A number of phrenic nerve-sparing block techniques have sprung up recently. Costoclavicular block has garnered the attention of regional anesthesia enthusiasts because of certain advantages. The cords are snugly packed and consistently arranged in a particular pattern around the first part of the axillary artery, unlike the lateral infraclavicular fossa. The single injection technique has been widely used conventionally, but the effect is unpredictable. The presence of septa has been confirmed by high-definition ultrasonographic studies, and it was proposed that a single injection does not suffice to block all cords simultaneously. Redirecting the needle in a double injection technique distributes the drug more efficiently, thereby blocking the anterior and posterior compartments separately. We propose a triple injection technique targeting the individual cords separately, followed by a short discussion justifying it.

CASE SERIES

We placed a costoclavicular block in 15 patients using the triple injection technique after obtaining written informed consent from each patient and after approval by the ethical committee. Using Sonosite M Turbo, the medial infraclavicular fossa was scanned with the patient's arm abducted and externally rotated. A linear transducer was placed below the clavicle with a cranial tilt to visualize cord elements arranged lateral to the axillary artery along with the pectoralis major, subclavius, serratus anterior, pleura, and second rib. On careful examination, septa could be identified in 11 patients, separating the lateral cord from the medial and posterior cords. In one patient, septa were seen separating medial from lateral and posterior cords, and in the rest of the two patients, septa could not be clearly differentiated. The needle was inserted from a lateral to medial direction in a plane piercing the septa that separated the upper (lateral cord) and lower

Address for Correspondence:

Dr. Priyanka Bansal, Associate Professor, Department of Anesthesia, PT BD Sharma PGIMS, Rohtak, Haryana, India.

Mobile: +91-8683921867. **E-mail:** dr.priyankabansal1986@gmail.com

compartments (medial and posterior cord), and the first injection was given at this point. The second injection was given between the artery and medial cord (pocket injection), specifically targeting the medial cord. While withdrawing the needle when it comes into the upper compartment, a third injection is given in the vicinity of the lateral cord (Figure 1).

Case 1

A 37-year-old patient with post-burn contracture on the medial side of the forearm was posted for split skin grafting. The costoclavicular block was placed using the above-mentioned technique.

Similarly, the costoclavicular block was placed in 14 more patients with fractured radius, fractured both bone and forearm, fractured ulna, burn contracture release of the wrist, debridement of the forearm, elbow ligament reconstruction, and fractured metacarpals.

After block placement, sensory and motor block is assessed for four major nerves: radial, median, ulnar, and musculocutaneous.

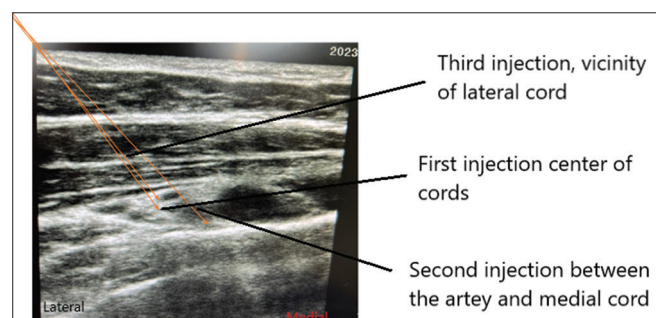


Figure 1: The three sites of costoclavicular injection

DISCUSSION

The attractive topographic arrangement of cords around the axillary artery and the consistent anatomical relation of cords lateral to the first part of the axillary artery between the subclavius and serratus anterior muscles make it a successful block with the low-volume drug.^{1,2} It was later proposed that the effect is unpredictable because of the septum that compartmentalizes cords into upper and lower compartments, with the upper compartment containing the lateral cord and the lower compartment containing the medial and posterior cords.^{3,4} Ultimately, it will block all the cords, but the effect remains unpredictable.⁵ Later on, studies proposed a double injection technique in which two separate injections were given for the lateral cord, and after piercing the septum, a second injection was given for the posterior and medial cord.^{4,6} The results were more encouraging with this technique. We conducted a case series by blocking all three cords separately with the triple injection technique. The results were very satisfactory, with a 100% success rate in 15 patients, including the obese patients, whose anatomy was perplexing. The onset of sensory block was hastened because of the earlier and target spread of the drug to the cords, blocking the medial, lateral, and posterior cords simultaneously. It was 7 min (on average) in our study. In a study, the authors noticed sensory block onset times to be 16 and 25 min, respectively, for double and single injection, respectively.⁶ Therefore, the patient's readiness for surgery is much earlier with the triple injection technique. Targeting all three cords separately by depositing the drug in their vicinity makes the effect more predictable and reliable, thereby validating our technique as it blocks all four major nerves supplying the upper extremity, namely, the median, ulnar, radial, and musculocutaneous, simultaneously. Although it has been proposed that a single

S. No.	No. of needle passes	Needling time (in min)	Sensory block			Motor block		
			5 min	10 min	15 min	5 min	10 min	15 min
1	2	5	U	UMR	UMR		UMR	UMR
2	2	2.4	UMR	UMR	UMR	UMR	UMR	UMR
3	2	3	UMR	UMR	UMR		UMR	UMR
4	2	2	R	MR	UMR		UMR	UMR
5	3	4.2	UMR	UMR	UMR		UMR	UMR
6	3	5.2	UMR	UMR	UMR		UMR	UMR
7	2	4.3	UMR	UMR	UMR		UMR	UMR
8	2	3.2	MR	UMR	UMR		UR	UMR
9	2	3.2		RM	UMR		MR	UMR
10	3	2.5	MR	MR	MR		MR	MR
11	2	3.4	UMR	UMR	UMR		URM	UMR
12	3	3.2	UMR	UMR	UMR		UMR	UMR
13	2	2.4	UMR	UMR	UMR	UMR	UMR	UMR
14	2	3.1		UR	UMR	0	UR	UMR
15	2	4.3	UMR	UMR	UMR	0	UMR	UMR

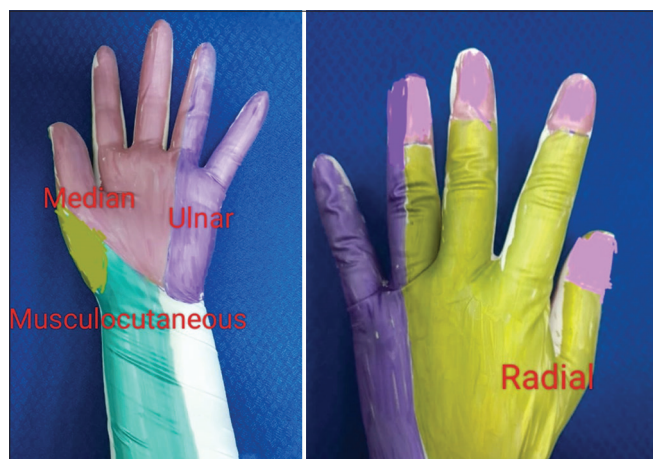

Figure 2: Sensory block assessment

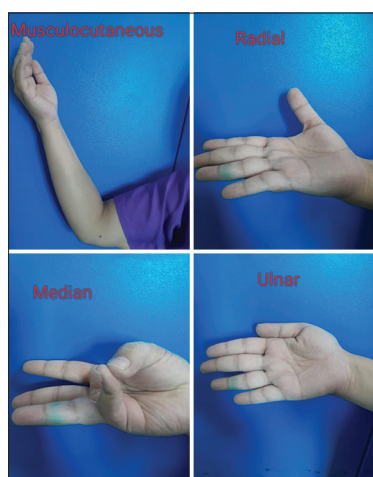


Figure 3: Motor block assessment

injection in the upper or lower compartment will lead to blocking all three cords by drug diffusion, the effect remains unpredictable (Figures 2 and 3).^{7,8}

We propose that a triple injection with the 3rd injection in the vicinity of the lateral cord just before withdrawing the needle apart from the other two injections significantly shortens the onset time of sensory block from 16 min to 7 min.⁴ The average time for a complete motor block was 9.6 min. There was only 1 patient in which the time to complete motor and sensory block was more than 15 min. The chances of the median nerve sparing, as has been reported in some cases in previous studies, are almost nil by this technique: the corner pocket injection that involves the medial root of the median nerve and the lateral cord that is specifically blocked separately, covering the lateral root of the median nerve.^{6,8} We did a case series in 15 cases, and though the sample size is small and this is definitely not a randomized control trial, to make such a bold statement, we would like to decipher the positive future of the costoclavicular block with the triple injection technique, with an RCT already underway.

The fringe of doubt has always been associated with costoclavicular block because of its proximity to the pleura and chances of pneumothorax. Close vigilance, along with the use of ultrasonography, depositing drugs under vision, directing the needle in a plane from lateral to medial direction, and guarded movements, mollify any such complications.

We did not encounter any other complications of dyspnea, hemorrhage, or prolonged paralysis in any of the patients.

CONCLUSION

The costoclavicular block has already carved a niche as an excellent choice for surgeries of the upper limb involving the elbow or below the elbow. The use of the triple injection technique makes the block effect more predictable and reliable.

ACKNOWLEDGMENT

None.

REFERENCES

1. Karmakar MK, Sala-Blanch X, Songthamwat B and Tsui BC. Benefits of the costoclavicular space for ultrasound-guided infraclavicular brachial plexus block: Description of a costoclavicular approach. *Reg Anesth Pain Med.* 2015;40(3):287-288. <https://doi.org/10.1097/AAP.0000000000000232>
2. Li JW, Songthamwat B, Samy W, Sala-Blanch X and Karmakar MK. Ultrasound-guided costoclavicular brachial plexus block: Sonoanatomy, technique, and block dynamics. *Reg Anesth Pain Med.* 2017;42(2):233-240. <https://doi.org/10.1097/AAP.0000000000000566>
3. Areeruk P, Karmakar MK, Reina MA, Mok LY, Sivakumar RK and Sala-Blanch X. High-definition ultrasound imaging defines the paraneural sheath and fascial compartments surrounding the cords of the brachial plexus at the costoclavicular space and lateral infraclavicular fossa. *Reg Anesth Pain Med.* 2021;46(6):500-506. <https://doi.org/10.1136/rapm-2020-102304>
4. Monzó E and Hadzic A. Costoclavicular approach to the brachial plexus block: Simple or double injection? *Reg Anesth Pain Med.* 2019. <https://doi.org/10.1136/rapm-2019-100852>
5. Songthamwat B, Karmakar MK, Li JW, Samy W, Mok LY. Ultrasound-guided infraclavicular brachial plexus block: Prospective randomized comparison of the lateral sagittal and costoclavicular approach. *Reg Anesth Pain Med.* 2018;43(8):825-831. <https://doi.org/10.1097/AAP.0000000000000822>
6. Layera S, Aliste J, Bravo D, Fernández D, García A, Finlayson RJ, et al. Single-versus double-injection costoclavicular block: A randomized comparison. *Reg Anesth Pain Med.* 2020;45(3):209-213. <https://doi.org/10.1136/rapm-2019-101167>

7. Sala-Blanch X, Reina MA, Pangthipumpai P and Karmakar MK. Anatomic basis for brachial plexus block at the costoclavicular space: A cadaver anatomic study. *Reg Anesth Pain Med.* 2016;41(3):387-391.
<https://doi.org/10.1097/AAP.0000000000000393>
8. Koyyalamudi V, Langley NR, Harbell MW, Kraus MB, Craner RC and Seamans DP. Evaluating the spread of costoclavicular brachial plexus block: An anatomical study. *Reg Anesth Pain Med.* 2021;46(1):31-34.
<https://doi.org/10.1136/rapm-2020-101585>

Authors Contribution:

PB- Review of manuscript; **NS, PB-** Concept and design, manuscript preparation, revision of manuscript.

Work attributed to:

Department of Anesthesia, PT BD Sharma PGIMS, Rohtak, Haryana, India.

Orcid ID:

Dr. Priyanka Bansal - <https://orcid.org/0000-0002-5900-401X>

Dr. Nidhi Sultania - <https://orcid.org/0009-0009-7616-7089>

Source of Support: Nil, **Conflicts of Interest:** None declared.