

# Rhomboid intercostal subserratus plane block – the Holy Grail of post-operative analgesia in modified radical mastectomy or just another dot in the long list?



Priyanka Bansal<sup>1</sup>, Nidhi Sultania<sup>2</sup>, Kunal Bansal<sup>3</sup>

<sup>1</sup>Associate Professor, <sup>2</sup>Senior Resident, Department of Anaesthesia, <sup>3</sup>Senior Resident, Department of Microbiology, PT BD Sharma PGIMS, Rohtak, Haryana, India

Submission: 10-10-2023

Revision: 28-10-2023

Publication: 01-12-2023

## ABSTRACT

Despite the presence of numerous options for breast analgesia, our women continue to suffer the consequences of acute post-operative pain that progresses to chronic pain in up to 55% of the post-mastectomy patients a rapid surge in the use of interfacial blocks for analgesia of chest and abdominal procedures. The importance and efficacy of these blocks are because of the continuity of the interfacial planes across varied anatomical tissues. We report a series of cases of modified radical mastectomy (MRM) in five female patients with the American Society of Anesthesiology Grade II/III in whom rhomboid intercostal subserratus was used for post-operative analgesia proved to be a boon. Two were post-radiation with metastasis to axillary lymph nodes. The other three had invasive ductal carcinoma and were on chemotherapy. Rhomboid intercostal subserratus plain block is a novel block and provides pain management for patients of MRM. The analgesic efficacy may not be superior but the non-inferiority to an epidural is certainly an added advantage with safe efficacious profile fulfilling the enhanced recovery after surgery protocols following minimally invasive surgical techniques.

**Key words:** Rhomboid intercostal; Subserratus plane block; Modified radical mastectomy

### Access this article online

**Website:**

<http://nepjol.info/index.php/AJMS>

**DOI:** 10.3126/ajms.v14i12.59188

**E-ISSN:** 2091-0576

**P-ISSN:** 2467-9100

Copyright (c) 2023 Asian Journal of Medical Sciences



This work is licensed under a Creative Commons Attribution-NonCommercial 4.0 International License.

## INTRODUCTION

Breast surgeries are one of the most common. Despite the presence of numerous options for analgesia that has been described in the literature, our women continue to suffer the consequences of acute post-operative pain that progresses to chronic pain in up to 55% of post-mastectomy patients. The source of pain is from stretching and shearing of tissues and fascia as well as post-operative drain placement. Sometimes, implants are placed, and the pocket is the source of pain that involves gradual expansion with balloons or serratus dissection.<sup>1</sup> The woes continue for months and years and hence the importance of a definite analgesia protocol for providing satisfactory post-operative analgesia

and excellent recovery without jeopardizing routine activities is the need. Regional anesthesia is an inseparable part of multimodal analgesia (MMA), starting from epidural, and local anesthetic infiltration to peripheral nerve blocks erector spinae, paravertebral, rhomboid intercostal block (RIB), rhomboid intercostal subserratus (RISS), etc.<sup>2,3</sup>

The 21<sup>st</sup> century has witnessed a rapid surge in the use of interfacial blocks for analgesia of chest and abdominal procedures. The importance and efficacy of these blocks are because of the continuity of the interfacial planes across varied anatomical tissues (Figures 1-4). These planes have various cutaneous as well as sympathetic branches and hence drug given spreads to cover a large dermatomal

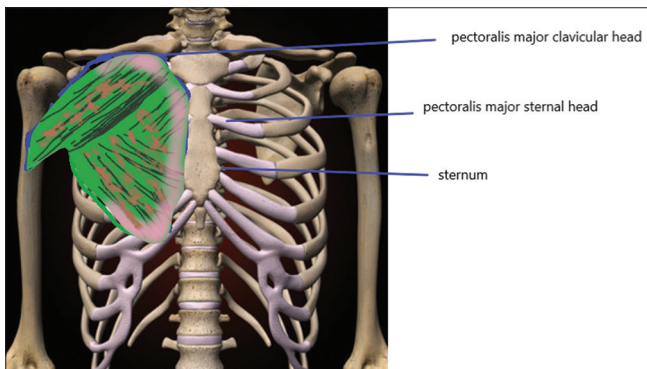
### Address for Correspondence:

Dr. Priyanka Bansal, Associate Professor, Department of anaesthesia, PGIMS, Rohtak, Haryana, India. **Mobile:** +91-8683921867.  
**E-mail:** dr.priyankabansal1986@gmail.com

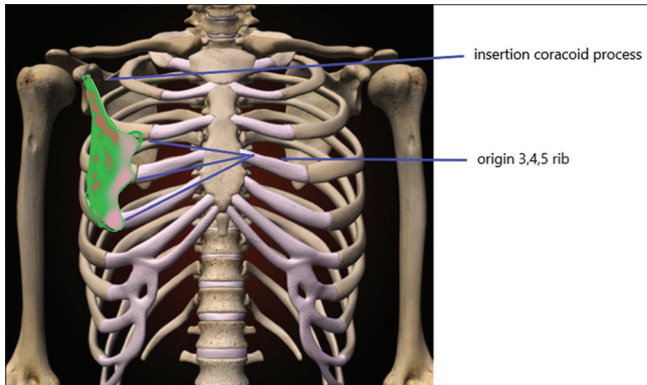
area. RISS plane block spreads to the anterior chest and abdominal area hence providing good analgesia for these regions. The drug spreads deep to the erector spinae plane in the upper thoracic region and extends up to the lumbar level and hence used in a myriad of surgeries - modified radical mastectomy (MRM) acute traumatic pain relief, laparoscopic surgeries, laparotomies, and also, some orthopedic procedures, for example, hip surgeries.<sup>4</sup>

RISS has been proposed to cover lateral cutaneous branches (LCB) of T2 to T11 that extend medially to

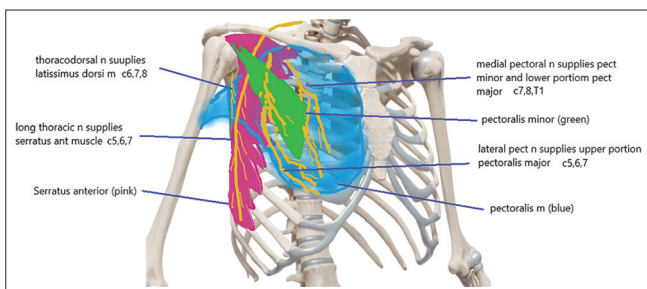
cover dorsal rami deep to the erector spinae plane block (ESP) (Figures 5-8). The site of injectate is at T5- T6. The dermatomal coverage is 4 cm lateral to the midline anteriorly, posteriorly 4 cm medial to posterior axillary line, cranially up to serrated posterior superior caudally up to serratus posterior inferior.<sup>1,3</sup> Apart from the safety considering the logistic issues, it is away from surgical field and also does not involve any major organ or blood vessel in its path, thus making it a sine qua non in such patients.



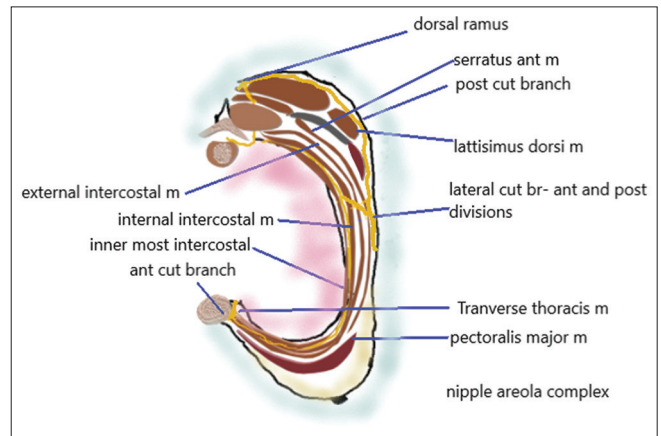
**Figure 1:** Pectoralis major muscle origin insertion (the basic skeletal framework taken from paints application, rest drawn by first and corresponding author PB)



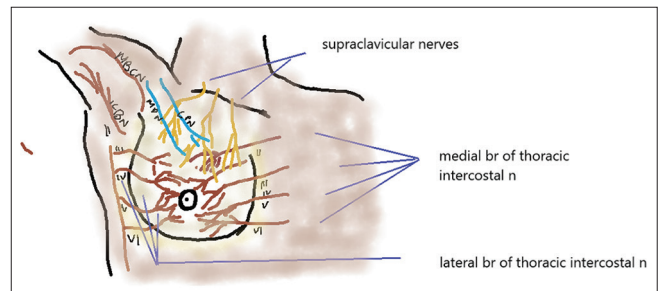
**Figure 2:** Pectoralis minor muscle origin insertion (the basic skeletal framework taken from paints application, rest drawn by first and corresponding author PB)



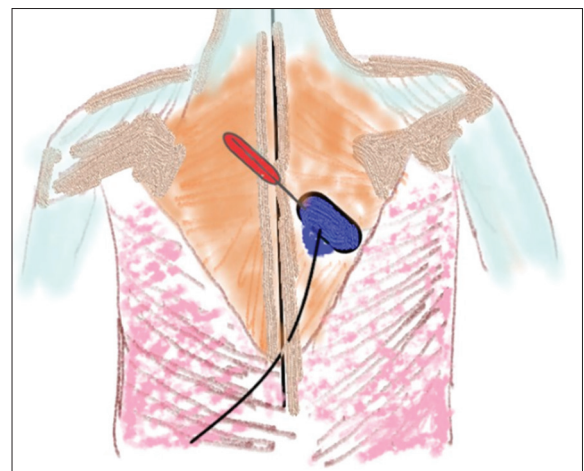
**Figure 3:** Nerve supply of muscles (the basic skeletal framework taken from paints application, rest drawn by first and corresponding author PB)



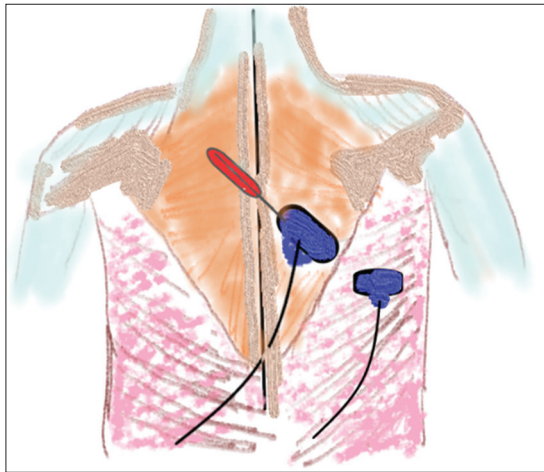
**Figure 4:** Cross section at T6 (Figure drawn by first and corresponding author PB)



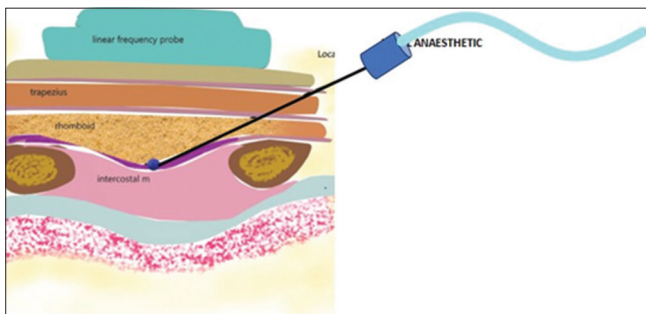
**Figure 5:** Nerve supply breast (Figure drawn by first and corresponding author PB)



**Figure 6:** Probe for rhomboid intercostal block (Figure drawn by first and corresponding author PB)



**Figure 7:** Probe for rhomboid intercostal subserratus (Figure drawn by first and corresponding author PB)



**Figure 8:** Diagrammatic representation of ultrasound of rhomboid intercostal subserratus (Figure drawn by first and corresponding author PB)

We report a series of cases of MRM in five female patients with the American Society of Anesthesiology (ASA) Grade II/III in whom RISS was used for post-operative analgesia proved to be a boon.

## CASE PRESENTATION

A 58-year-old female patient with an average build, ASA grade II, posted for an MRM, with axillary lymph node dissection having a diagnosis of invasive ductal carcinoma. She had the previous two cycles of chemotherapy. A plan for post-induction RISS block as a part of MMA was made. Routine investigations such as complete hemogram, chest X-ray, and ECG were unremarkable.

The patient was taken to the operation theater and monitors were attached. Arterial line on the left is secured along with peripheral cannulation. After induction and intubation patient was put in the left lateral decubitus position, affected side up. Unilateral RISS was performed with 30 mL of 0.25% bupivacaine, using the technique mentioned later. Intraoperatively, patient remained stable throughout the procedure. Mean blood pressure

was 112/64, heart rate 74/min, and SpO<sub>2</sub> 100%. No intraoperative supplementation was required except for relaxant at regular intervals.

Injection fentanyl 100 mcg plus 50 mcg was repeated along with injection of paracetamol 1 g infusion, injection dexamethasone 8 mg, injection tramadol 100 mg before extubating as a part of MMA was given. The patient was quite stable after extubation and follow-up done for 24 h in high dependency unit (Tables 1 and 2).

## DESCRIPTION OF THE TECHNIQUE

The patient was placed in the lateral position after induction of general anesthesia, the arms were abducted and internally rotated to open up his scapula and move the angle laterally. A linear ultrasound (USG) transducer high frequency, Sonosite M-Turbo, was placed in the sagittal plane medial to the medial border of the scapula with the orientation marker directed cranially. The transducer was then rotated so the cranial end was directed slightly medially and the caudal end laterally to produce an oblique sagittal view (paramedian sagittal oblique) approximately 1–2 cm medial to the medial scapular border.

The following structures were identified from superficial to deep: trapezius muscle, rhomboid major muscle, intercostal muscles between ribs, pleura, and lung. The tissue plane between the rhomboid and intercostal muscles was identified. A 23 G, 8 cm long needle was advanced in plane from a superomedial-to-inferolateral direction, through the trapezius and rhomboid major muscles. 10 mL of 0.25% bupivacaine (0.5% bupivacaine diluted in normal saline [NS]) was injected in the fascial plane between the rhomboid major and the external intercostal muscle. The skin entry point for the first injection was at the T5–T6 level. Two landmarks verified the identification of the T5–T6 level: (1) counting down from the C7 spinous process and (2) identifying the base of scapula at the T7 level (Figure 9).

Next, to identify the subserratus plane, the transducer was moved more caudally and laterally, behind the posterior axillary line, below the inferior angle of the scapula. The tissue layers identified on USG from superficial to deep were latissimus dorsi, serratus anterior, intercostal muscles between ribs, the pleura, and lung. The needle was directed medial to the lower angle of the scapula and toward the posterior axillary line. 20 mL of 0.25% bupivacaine (0.5% bupivacaine diluted in NS) was injected in the tissue plane between the serratus anterior and external intercostal muscle. USG spread of the drug was clearly visualized.

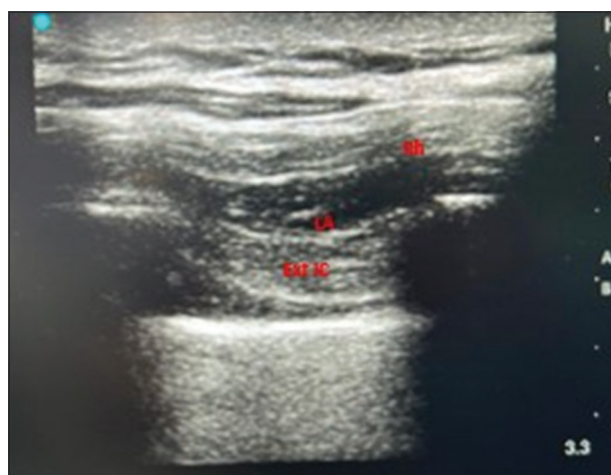
**Table 1: Patients demographic profile**

Patients	Pt 1	Pt 2	Pt3	Pt4	Pt 5
Age (in years)	58	56	48	62	65
BMI (kg/m <sup>2</sup> )	24.2	27.3	26.4	27.5	22.8
ASA	II	II	II	III	III
Comorbidity	chemotherapy laparotomy 12 years back	diabetic	none	Hypertension diabetes chemotherapy	Hypertension diabetes chemotherapy

ASA: American Society of Anesthesiology, BMI: Body mass index

**Table 2: Block characteristics**

Time 1 <sup>st</sup> pain complaint	14 h post-operative	16 h after 1 <sup>st</sup> inj	15 h after 1 <sup>st</sup> inj	16.5 h after 1 <sup>st</sup> inj	13 h after 1 <sup>st</sup> inj
Total number of time requests made in 24 h	Twice	Once	Twice	Once	Once
Pt satisfaction	5	5	4	5	4
Nausea/vomiting	Nil	Nil	Minor	Minor	Nil
Intraoperative fentanyl consumption (in mcg)	150	100	100	100	100
Other complications related to block	None	None	None	None	None

**Figure 9:** Ultrasound image of rhomboid intercostal subserratus block (Figure drawn by first and corresponding author PB)

No arterial puncture or blood aspirate was noticed in any patient. Before each injection, the injection pressure was monitored, the aspirate done, and intermittent aliquots (2 mL) of drugs were injected.

Analogous to the above patient, four more patients ASA grade II/III, posted for MRM were given RISS block. Two were post-radiation with metastasis to axillary lymph nodes. The other two had invasive ductal carcinoma and were on chemotherapy.

## INNERVATION OF THE BREAST

The innervation of breast tissue and skin is quite distinct as well as complicated. The intercostal nerves (ICN) contribute to majority of the cutaneous innervation. The medial breast is innervated by anterior cutaneous branches (ACB) of T2- T5 ICN and lateral breast from LCB of

T2 -T5 with some contributions from T1 and T6 (Figure 5). There is frequent communication of lateral and ACB along their course.

The advantages of RISS block are that the injection is far from the surgical site and hence as the drug does not interfere with the cautery function if given pre-operatively.<sup>1</sup> After induction technically, it is more feasible than serratus plane block or pectoral blocks. Logistically prior catheterization is possible that does not interfere with the sterility of the surgical field. It covers the LCBs from T3 to T11 ventral rami with spread to the dorsal rami that exit superficial to the transverse processes. Inconsistent axillary coverage is present as it does not cover the intercostobrachial nerve (LCB of second ICN T2). The midline, thoracodorsal nerve, and long thoracic nerve are not covered. Complete analgesia is not provided for latissimus dorsi flap, segmental resection surgeries or lymph node dissections, or radical mastectomies. It is one continuous plane between the rhomboid, the external intercostal, erector spinae, serratus anterior, and upper part of external oblique intercostal muscle.<sup>2,3</sup>

Tulgar used RIB in an 82-year-old female for MRM.<sup>4</sup> A unilateral block was placed between the rhomboid muscle and the 5<sup>th</sup> rib and the spread of the drug was seen from the 2<sup>nd</sup> and the 7<sup>th</sup> rib. Post-operatively, sensory block was observed from T3 to T9 vertebral level. The numerical rating scale (NRS) score remained <3 up to the 13<sup>th</sup> post-operative h with bearable pain in the axillary area. This was the first ever reported use of RIB in a patient of MRM. This highlighted the superiority of peri-paravertebral blocks apart from previously used ESP and paravertebral blocks for a similar condition. Similarly, Tulgar had reported safe and effective long-lasting post-operative analgesia with RIB in

the excision of elastofibroma of neck extending up to the subscapular space. The patient was home discharged with just tablet PCM. No decreased range of motion or pain in the shoulder was observed. Balaban and Aydin did bilateral RIB and reported NRS <2 but poor axillary coverage.<sup>5</sup>

Altıparımak conducted a randomized controlled trial on 30 MRM patients with axillary lymph node dissection.<sup>6</sup> They used RISS along with general anesthesia as a part of post-operative analgesia. The patients had enhanced recovery and quality of life score (QoR-40), especially in terms of pain and emotional status. The authors proposed that the reason may be lesser opioid (morphine) consumption which was given through patient-controlled analgesia pump. Opioids are notorious for causing nausea, vomiting, respiratory depression, sedation, urinary retention, itching apart from hyperalgesia, and tolerance at higher doses. Much has been debated about the demand for post-operative analgesia protocols to prevent the opioid pandemic. This study reported NRS <4 at all time points but axillary coverage was poor. Another author pointed out the usefulness of RIB over ESP in a case where a bilateral block is required. The spread of the drug is peripheral to the ICNs, rather than toward the epidural or the paravertebral space hence chances of sympathetic chain blockade leading to hypotension are declined. RIB does not ACBs hence analgesia near the sternum or inner quadrants is less.

Kozenhan described the use of RISS in a morbidly obese patient posted for MRM and axillary curettage. The authors justified its use as the demands of opioids are less, and hence, post-operative respiratory compromise is minimized in such patients.<sup>7</sup>

Various studies have compared paravertebral and epidural blocks as analgesic options in abdominothoracic surgeries.<sup>7-9</sup> The technical difficulties due to the anatomical site close to the neuroaxis which is a non-compressible site. Hence, these blocks are less appreciated than RIB. Pectoralis nerve block II and serratus plane block cover the lateral pectoral, medial pectoral nerve, along with thoracodorsal and long thoracic nerve but it is difficult in fatty, large breast patients and also is close to the surgical site. RISS/RIB does not cover these nerves including superior aspect of pain – the supraclavicular nerves but the dermatomal coverage is wide both on the lateral and the posterior and cranially and caudally.<sup>10</sup> Thus, RISS is excellent as a part of MMA for post-operative pain management in MRM patients, who remain comfortable for up to 14 h and a NRS score <3 was seen in all of our five patients.

The dynamic nature of pain was apparent at 14 h in three of the patients who had extensive axillary lymph node dissection.

The renaissance in the era of blocks is visualizing an invention of a new block almost every month, let's not talk about the feasibility and the technicality of these blocks. Elsharkawy in his article eloquently mentioned that these facial plane blocks are different from nerves or plexus blocks in that no definite nerve is blocked, and hence, the effect is highly unpredictable. We depend on the facial plane anatomy, its structure, and its relation to the surrounding organs and tissues to precisely disseminate the local anesthetic to its desired location.<sup>11</sup> We need to understand the dynamic nature of facial layers and their microanatomy to determine the site of drug spread and predict an outcome thereby increasing the applicability of these blocks in contemporary regional anaesthesia practice. Enthusiasm should not blur our understanding of the basics.<sup>12,13</sup> We should remember Triple A, improve health, enhance patient outcomes, and decrease the cost.

We open the doors for larger studies with more patients, comparing different blocks with RIB/RISS blocks before generalizing the results.

## CONCLUSION

RISS plain block is a novel block and provides pain management for patients of MRM. The analgesic efficacy may not be superior but the non-inferiority to an epidural is certainly an added advantage with safe efficacious profile fulfilling the enhanced recovery after surgery protocols following minimally invasive surgical techniques.

## AVAILABILITY OF DATA

Our data, including raw dataset, are available upon request from the corresponding author.

## REFERENCES

1. Elsharkawy H, Ince I and Pawa A. Rhomboid intercostal and sub-serratus (RISS) plane block for analgesia after lung transplant. *J Clin Anesth.* 2019;56:85-87. <https://doi.org/10.1016/j.jclinane.2019.01.042>
2. Deng W, Hou XM, Zhou XY and Zhou QH. Rhomboid intercostal block combined with sub-serratus plane block versus rhomboid intercostal block for postoperative analgesia after video-assisted thoracoscopic surgery: A prospective randomized-controlled trial. *BMC Pulm Med.* 2021;28(1):68. <https://doi.org/10.1186/s12890-021-01432-7>
3. Elsharkawy H, Saifullah T, Kolli S and Drake R. Rhomboid intercostal block. *Anaesthesia.* 2016;71(7):855-856. <https://doi.org/10.1111/anae.13498>
4. Tulgar S, Thomas DT, Deveci U and Özer Z. Ultrasound guided rhomboid intercostal block provides effective analgesia for excision of elastofibroma extending to the subscapular space: The first report of use in anesthesia practice. *J Clin Anesth.*

- 2018;52:34-35.  
<https://doi.org/10.1016/j.jclinane.2018.08.015>
5. Balaban O and Aydin T. A modified approach of rhomboid intercostal block for postoperative analgesia in modified radical mastectomy: Ultrasound guided bi-level high thoracic injection. *J Clin Anesth.* 2019;57:29-30.  
<https://doi.org/10.1016/j.jclinane.2019.03.002>
  6. Altiparmak B, Tokar KM, Uysal AI, Dere O and Ugur B. Evaluation of ultrasound-guided rhomboid intercostal nerve block for postoperative analgesia in breast cancer surgery: A prospective, randomized controlled trial. *Reg Anesth Pain Med.* 2020;45(4):277-282.  
<https://doi.org/10.1136/rapm-2019-101114>
  7. Kozanhan B, Aksoy N, Yildiz M, Tutar MS, Canitez A and Eryilmaz MA. Rhomboid intercostal and subserratus plane block for modified radical mastectomy and axillary curettage in a patient with severe obstructive sleep apnea and morbid obesity. *J Clin Anesth.* 2019;57:93-94.  
<https://doi.org/10.1016/j.jclinane.2019.03.026>
  8. Camacho FC and Segura-Grau E. Continuous serratus anterior plane block provides analgesia in multiple rib fractures: A case report. *Rev Bras Anesthesiol* 2019;69(1):87-90.  
<https://doi.org/10.1016/j.bjan.2018.03.007>
  9. Tulgar S, Selvi O, Thomas DT, Manukyan M and Özer Z. Rhomboid intercostal block in a modified radical mastectomy and axillary curettage patient; A new indication for novel interfascial block. *J Clin Anesth.* 2019;54:158-9.  
<https://doi.org/10.1016/j.jclinane.2018.12.006>
  10. Yayik AM, Ahiskalioglu A, Ates I, Ahiskalioglu EO and Cinal H. Ultrasound guided bilateral rhomboid intercostal block for breast reduction surgery. *J Clin Anesth.* 2019;57:38-39.  
<https://doi.org/10.1016/j.jclinane.2019.03.001>
  11. Garg R. Regional block: Walking away from central to peripheral nerves and planes for local anaesthetic drug deposition. *Indian J Anaesth.* 2019;63(7):517-519.  
[https://doi.org/10.4103/ija.IJA\\_495\\_19](https://doi.org/10.4103/ija.IJA_495_19)
  12. Jiang CW, Liu F, Zhou Q and Deng W. Comparison of rhomboid intercostal nerve block, erector spinae plane block and serratus plane block on analgesia for modified radical mastectomy: A prospective randomised controlled trial. *Int J Clin Pract.* 2021;75(10):e14539.  
<https://doi.org/10.1111/ijcp.14539>
  13. Woodworth GE, Ivie RM, Nelson SM, Walker CM, Maniker RB. Perioperative breast analgesia: A qualitative review of anatomy and regional techniques. *Reg Anesth Pain Med.* 2017;42(5):609-631.  
<https://doi.org/10.1097/AAP.0000000000000641>

**Authors' Contributions:**

**PB-** Review of manuscript; **NS, KB-** Concept and design, manuscript preparation, revision of manuscript.

**Work attributed to:**

Department of Anaesthesia, PT BD Sharma PGIMS, Rohtak, Haryana, India.

**Orcid ID:**

Dr. Priyanka Bansal - <https://orcid.org/0000-0002-5900-401X>

Dr. Nidhi Sultania - <https://orcid.org/0009-0009-7616-7089>

Dr. Kunal Bansal - <https://orcid.org/0009-0003-7137-0471>

**Source of Support:** Nil, **Conflicts of Interest:** None declared.