

# Meckel's diverticulum with varied clinicopathological presentations: A case series at a rural tertiary care center



Jaya Bagchi<sup>1</sup>, Rupsha Dutta<sup>2</sup>, Dwaipayan Samaddar<sup>3</sup>, Bidyut Krishna Goswami<sup>4</sup>

<sup>1</sup>Demonstrator, <sup>2</sup>Assistant Professor, <sup>4</sup>Professor, Department of Pathology, <sup>3</sup>Associate Professor, Department of General Surgery, North Bengal Medical College and Hospital, Sushrutanagar, West Bengal, India

Submission: 20-09-2023

Revision: 03-01-2024

Publication: 01-01-2024

## ABSTRACT

Meckel's diverticulum (MD), first documented by Wilhelm Fabricius Hildanus in 1598 as a small bowel diverticulum and later detailed by Johann Friedrich Meckel in 1809, is a remnant of the vitellointestinal duct connecting the fetal gut with the yolk sac. It is a true diverticulum, comprising of all the layers of the bowel wall. The commonly cited "rule of 2s" regarding the diverticulum is: Occurs in 2% of the population, has a 2:1 male-to-female ratio, usually discovered by 2 years of age, located 2 feet from the ileocecal valve, and commonly 2 cm in diameter and 2 inches long. Most Meckel diverticula are benign and are incidentally discovered during autopsy, laparotomy, or barium studies. Vitellointestinal duct lining cell being pluripotent, heterotopic tissues such as gastric, pancreatic followed by others might be found. Common clinical presentation in symptomatic cases is gastrointestinal hemorrhages followed by intestinal obstruction, diverticulitis, cystic abdominal mass, patent umbilical fistula, and neoplasm. Clinical signs and symptoms are non-specific simulating other abdominal emergencies and routine radiology is unable to detect the anomaly in rural peripheral centers. Hence, prompt surgical intervention may be needed in emergency cases. Diverticulectomy or ileal segment resection with end-to-end anastomosis is done. Due to the difficulty of diagnosing a pathologic MD pre-operatively, many surgeons recommend prophylactic diverticulectomy in those found incidentally.

**Key words:** Meckel's diverticulum; Vitellointestinal duct; Pluripotent; Heterotopic; Diverticulectomy

## INTRODUCTION

Wilhelm Fabricius Hildanus first documented the presence of a small bowel diverticulum in 1598.<sup>1</sup> This diverticulum in 1809 was named after Johann Friedrich Meckel who detailed its anatomy and embryology.<sup>2</sup> Meckel's diverticulum (MD) is a remnant of the vitellointestinal (omphalomesenteric) duct connecting the fetal gut with the yolk sac and it normally involutes between the 5<sup>th</sup> and 7<sup>th</sup> weeks of gestation. Failure of this involution results in a variety of abnormalities arising from persistence of the remnant. The most common anomaly (90%) is the classic MD - a true diverticulum, comprising of all the layers of

the bowel wall. The usual manifestation is a relatively wide-mouthed diverticulum measuring about 5 cm in length, with a diameter of up to 2 cm.<sup>3</sup>

A systematic review of autopsy studies showed the incidence as 1.2%.<sup>3</sup> The MD association may be more in patients with major anomalies of the umbilicus, alimentary tract, nervous system, or cardiovascular system.<sup>4</sup> The commonly cited "rule of 2s" regarding the diverticulum is: Occurs in 2% of the population, has a 2:1 male-to-female ratio, usually discovered by 2 years of age, located 2 feet from the ileocecal valve, and commonly 2 cm in diameter and 2 inches long. The vitelline duct lining cells

### Access this article online

#### Website:

<http://nepjol.info/index.php/AJMS>

DOI: 10.3126/ajms.v15i1.58682

E-ISSN: 2091-0576

P-ISSN: 2467-9100

Copyright (c) 2024 Asian Journal of Medical Sciences



This work is licensed under a Creative Commons Attribution-NonCommercial 4.0 International License.

### Address for Correspondence:

Dr. Dwaipayan Samaddar, Associate Professor, Department of General Surgery, North Bengal Medical College and Hospital, K 4, 100 Pearls, Jyotinar, Zilla Parishad Road, Siliguri-734001, West Bengal, India. **Mobile:** +91-7001525003.  
**E-mail:** drdsam07@gmail.com

are pluripotent; so, it is common to find heterotopic tissue within the MD, the most common being gastric mucosa (about 50% of all MDs) followed by pancreatic mucosa (about 5%) and rarely colonic mucosa. More rarely, it may contain duodenal, colonic, or endometrial tissue.<sup>3,4</sup>

An estimated 4% of patients with MD will become symptomatic, and the risk of developing symptoms decreases with age. A report based on data from the pediatric health information system database found that 53% of Meckel diverticulectomies are performed before 4 years of age.<sup>5</sup> However, as a whole, no sex predilection is noted.<sup>3</sup>

Common clinical presentation in symptomatic cases is gastrointestinal hemorrhage due to heterotopic gastric mucosal acid secretion inducing ileal ulceration (25–50% – both acute and chronic-chronic ones leading to anemia), intestinal obstruction (causes being volvulus, intussusception, and incarcerated MD, i.e., Littre's hernia in hernial sacs of different sites and thus being symptomatic accordingly), and diverticulitis (10–20% – common in adults-mimicking appendicitis and in severe cases leading to perforation and appendicitis). Less common presentations are cystic abdominal mass, umbilical fistula (patent vitelline duct), and neoplasms (neuroendocrine ones being common – 77%).<sup>3,5</sup>

MD is difficult to diagnose by routine radiology and an acute clinical presentation especially in a rural tertiary care center might not always allow us taking the advantage of sodium <sup>99m</sup>Tc-pertechnetate scintigraphy (85% sensitive in children having MD with gastric mucosa). In adults, sensitivity gets decreased (68%) giving false-negative results and barium contrast imaging, mesenteric arteriography, and double-balloon endoscopy might be helpful. In acute hemorrhage, angiography is sometimes useful. Surgical intervention without any delay is of utmost importance in case of acute hemorrhagic emergencies and hemodynamic instability.<sup>3</sup>

The aim of our study was to present the wide spectrum of clinicopathological presentation and their management of MD at a rural tertiary care center with constrained logistics. To that effect, we are presenting here a case series composed of ten such cases of MD (from January 01, 2022, to October 31, 2022).

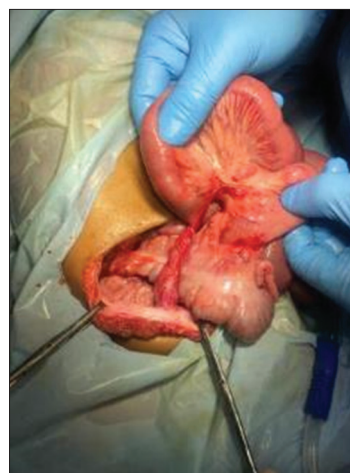## CASE 1

A 3-year-old male baby presented to emergency with symptoms of abdominal pain and distension of 4 days duration and bilious vomiting for 1 day. On examination, the child was stable with abdominal distension and increased peristalsis. Intestinal obstruction was clinically suspected and confirmed by plain X-ray and ultrasound abdomen. On laparotomy distended ileal loops with volvulus over a band

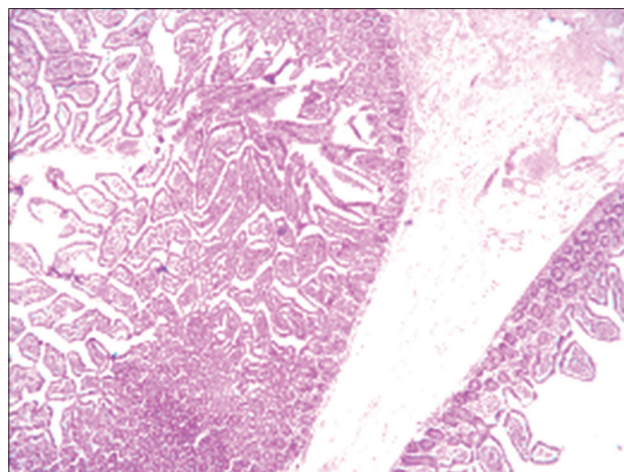
that was nothing but a MD that was stuck to the umbilicus (Figure 1). Volvulus was undone along with resection of MD. Post-operative period was uneventful. Biopsy report showed inflammatory ileal segment and MD without any other significant pathology (Figure 2).

## CASE 2

A 16-year-old female presented to emergency with complaints of pain abdomen and distension for the past 2 days. The patient was hypotensive and had diffuse abdominal tenderness with guarding and rigidity. After resuscitation, X-ray erect abdomen and ultrasound was done which confirmed clinical diagnosis of perforative peritonitis. At laparotomy, MD perforation at the base was detected. Resection of MD and ileal segment along with end-to-end anastomosis was done. Post-operative period was uneventful with biopsy report showing congestion, edema, and inflammatory changes (Figures 3, 4a and 4b) in small bowel, serositis, and acute diverticulitis.



**Figure 1:** Meckel's diverticulum causing band obstruction



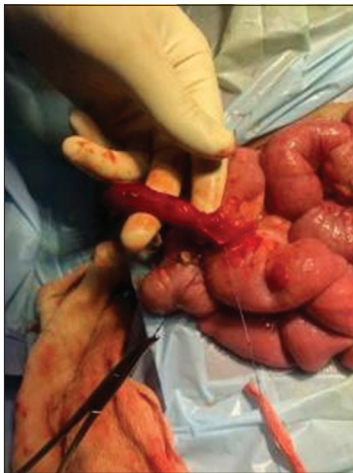**Figure 2:** Meckel's diverticulum with submucosal congestion and edema

### CASE 3

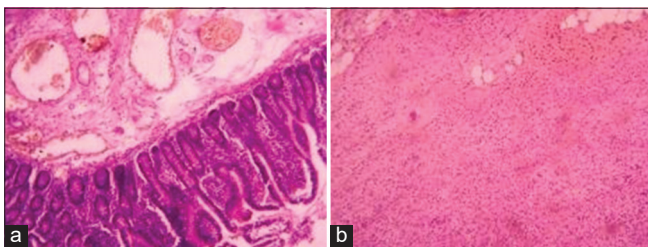
A 45-year-old male presented with distension of abdomen for the past few days, history of not passing stools, and vomiting for 1 day. His vitals were stable. Clinically, abdomen was distended with hyperperistalsis without any palpable mass. Digital rectal examination revealed no mass but there was no fecal staining either. Clinical diagnosis of obstruction was confirmed by X-ray erect abdomen and ultrasound abdomen. At laparotomy, a growth was detected at rectum. Anterior resection was done. Incidentally, MD was noted with wide mouth and was not resected.

### CASE 4

A 41-year-old male presented with fever, nausea, vomiting, and periumbilical pain of 3-day duration. On examination, involuntary guarding of the suprapubic region was noted. Biochemistry revealed a normal lipase and urinary analysis, with leukocytosis ( $19.4 \times 10^9/L$ ). Straight X-ray abdomen showed small bowel obstruction. A contrast enhanced computerized tomography (CECT) scan of the abdomen included a distal small bowel obstruction near the terminal ileum (target lesion) and free fluid in the pelvis. The patient was taken to the emergency with



**Figure 3:** Meckel's diverticulum perforated at base, ligation of vitellointestinal artery

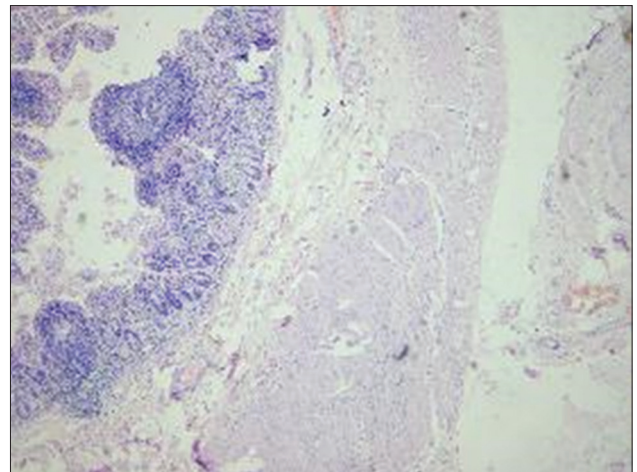


**Figure 4:** (a) Meckel's diverticulum with inflammation. (b) Subserosal inflammation

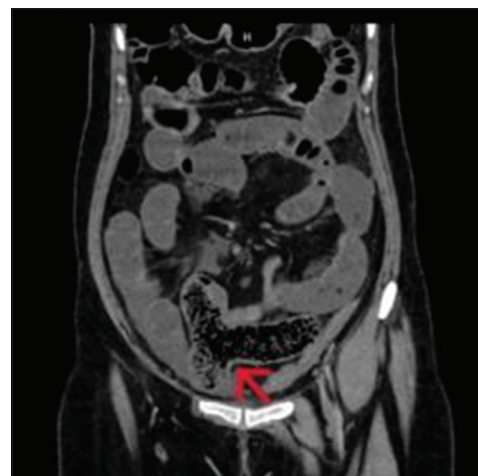an acute abdomen. At surgery, 20 cm of ileum and cecum were resected including a large inflammatory mesenteric mass (limited right hemicolectomy). The patient recovered and was discharged uneventfully. Biopsy showed MD with an acute inflammatory mesenteric mass obstructed by a fecolith, resulting in ulceration and perforation. Hemorrhage and reactive lymphoid hyperplasia were also present in that region of the MD (Figure 5). The MD was found 24 cm from the terminal ileum - consistent with the diagnosis.

### CASE 5

A 19-year-old female presented with hematochezia of 4-day duration, increasing light-headedness, shortness of breath, palpitations, headache, and fatigue. The patient was hemodynamically unstable having a hemoglobin level of 4.8 g/dL. The patient was resuscitated for a presumed lower gastrointestinal



**Figure 5:** Meckel's diverticulum with reactive lymphoid hyperplasia



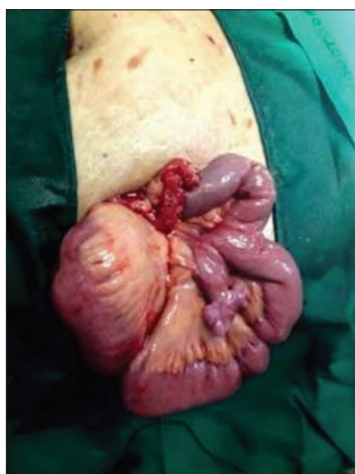**Figure 6:** Contrast-enhanced computerized tomography demonstrating Meckel's diverticulum



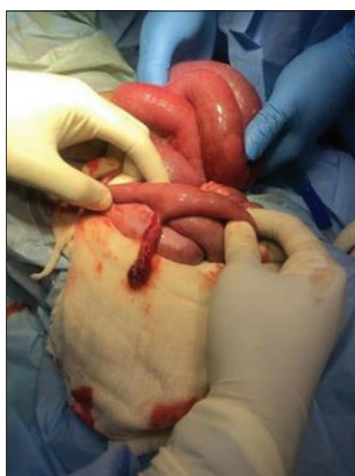bleed. There was no evidence of active hemorrhage on initial investigation such as endoscopy, mesenteric angiogram, or colonoscopy. We do not have Meckel's scan facility here; so, CECT was done that revealed MD (Figure 6). The patient was operated and MD was resected along with adjacent ileum. Recovery was uneventful. Hematochezia subsided. The pathology report showed inflamed MD with antral metaplasia and ulceration present at the base.

## CASE 6

A 16-year-old girl came to emergency with complaints of pain abdomen for 3 days. On examination, vitals were within normal limits. There was tenderness at McBurney's point with rebound tenderness. Diagnosed as acute appendicitis patient was posted for laparoscopic appendectomy; along with inflamed appendix incidentally, we noticed MD. Appendectomy was done and MD left unresected (Figure 7).



**Figure 7:** Meckel's diverticulum in appendicitis



**Figure 8:** Inflamed tip of Meckel's diverticulum

## CASE 7

A 15-year-old girl presented with a history of pain abdomen and vomiting for 2 days. On examination, there was tenderness noted in McBurney's point with rebound tenderness. Diagnosis of acute appendicitis was made, planned for open appendectomy. Appendix was normal and on exploration of ileum, inflamed MD tip (Figure 8) was noted and diverticulectomy was done. The patient was discharged uneventfully. Biopsy showed inflamed MD.

## CASE 8

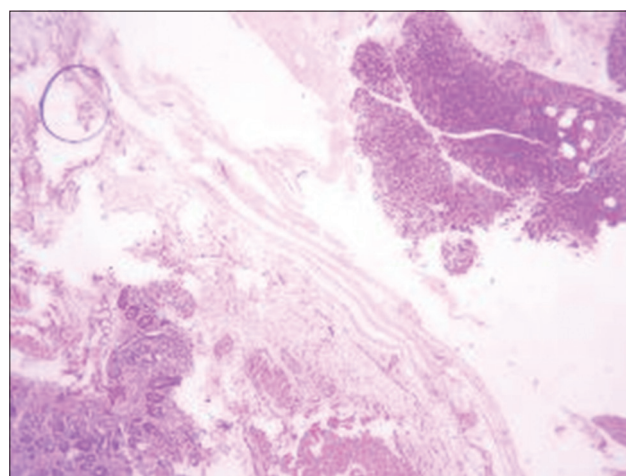
Presentation and the course of the disease were identical to our case 1; only difference being the patient was a 2-year female child.

## CASE 9

Presentation and the course of the disease were identical to our case 7 with differences in the age and sex of the patient and histopathology report. Here, the patient was an 18-year-old male with pancreatic heterotopia (Figure 9).

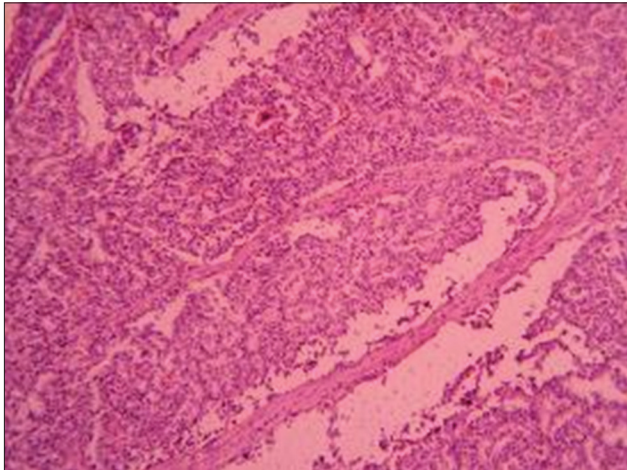
## CASE 10

A 46-year-old male presented with excruciating pain in RIF with all the imaging studies (ultrasound sonography, erect abdominal X-ray, and computed tomography) being normal but having leukocytosis. As pain was not responding to conservative management, emergency laparotomy was performed. Inflamed MD was detected and resected along with normal looking appendix. Histopathology report

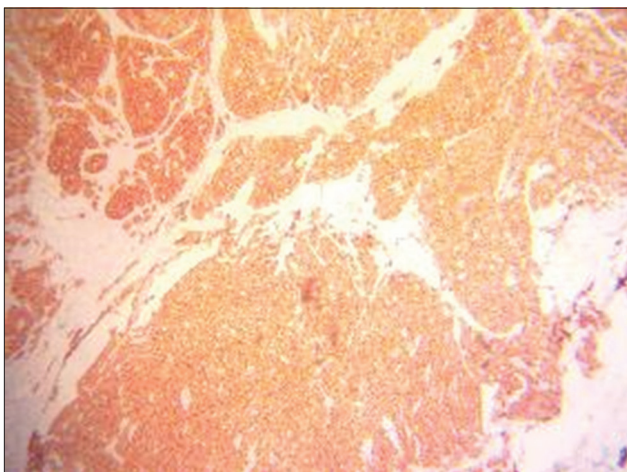


**Figure 9:** Pancreatic heterotopia

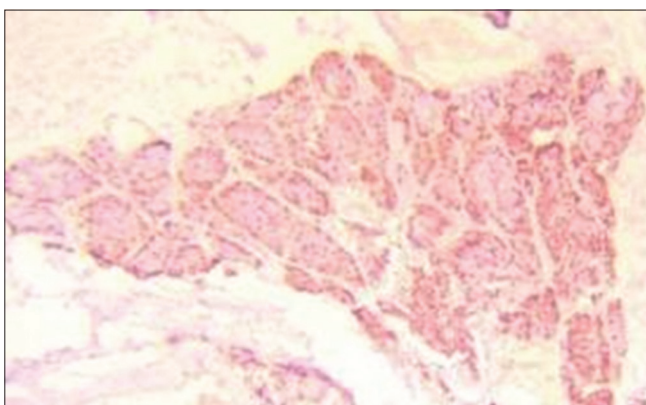
showed the presence of well-differentiated neuroendocrine tumor (NET) of 2 cm size in mucosa not invading in muscle layer, grade 1 expressing strong and intense cytoplasmic positivity for synaptophysin and chromogranin (Figures 10-12).



**Figure 10:** Neuroendocrine tumor in Meckel's diverticulum



**Figure 11:** Synaptophysin in Meckel's diverticulum (neuroendocrine tumor)



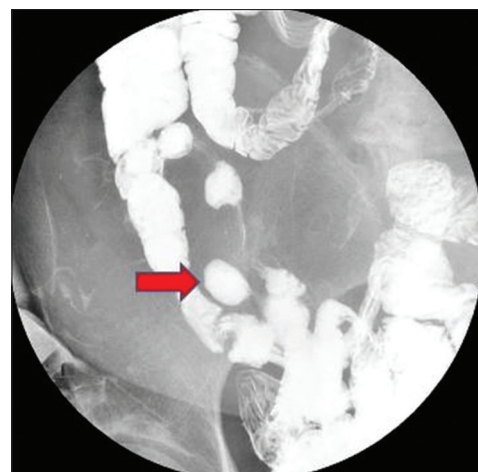**Figure 12:** Chromogranin in Meckel's diverticulum (neuroendocrine tumor)

## DISCUSSION

Out of ten cases with MD, two were children, five were under 20 years of age, and five were females. Two cases were incidentally detected - one had rectal mass and other had inflamed appendix - in both the cases, wide mouthed MDs were left unresected. Both the children presented with obstructive symptoms due to MD and volvulus. Two had MD perforation, one having obstruction due to post-perforation inflammatory mesenteric mass. One patient had GI hemorrhage. Diverticulitis was seen in most of the patients having undergone diverticulectomy. One case had the presence of MD NET. Antral metaplasia was seen in one case with hemorrhage and MDitis and pancreatic heterotopia was also present in one case having MDitis. Most of the patients reported here came to our surgery emergency unit with abdominal complaints resulting in more number of cases with MD pathology than incidentaloma as reported in literatures.

Technetium 99m pertechnetate scan is used for diagnosis which is highly sensitive and specific in both pediatric and adult population.<sup>6,7</sup> Other diagnostic modalities include barium enema/follow through (Figure 13), CECT, capsule endoscopy, and angiography.

If conservative methods fail to control hemorrhage, diverticulectomy or ileal segment resection with end-to-end anastomosis is done. Treatment of perforation is segmental resection with end-to-end anastomosis. Pathophysiology of diverticulitis is similar to that of acute appendicitis, with inflammation secondary to stasis (due to fecolith or parasites or foreign body) and bacterial infection.<sup>7,8</sup> Usually, treatment is diverticulectomy. A wedge resection of the MD is generally carried out, and occasionally, some ileum is resected by end-to-end anastomosis.



**Figure 13:** Barium enema in Meckel's diverticulum



The results of surgical excision are generally excellent. From various studies, the cumulative incidence of early post-operative complications was about 12% and the mortality rate was about 1.5%. The cumulative incidence of late post-operative complications during a 20-year follow-up was 7%. Diverticulectomy for MD found incidentally has been criticized, but incidental diverticulectomies are safer, with an overall rate of morbidity of 2% and a mortality of 1%.<sup>9</sup> Due to the difficulty of diagnosing a pathologic MD pre-operatively, many surgeons recommend prophylactic diverticulectomy in those found incidentally.<sup>10</sup> This recommendation is based on lower morbidity rates when compared to the resection of pathologic diverticula.<sup>11</sup>

Published literature concludes that most of the MD are discovered incidentally and are benign and malignant transformation is unusual with reported incidence to be only 0.5–3.2%. Carcinoid is the most common primary diverticular malignancy 33–44%, followed by leiomyosarcoma 18–25%, adenocarcinoma 12–16%, and gastrointestinal stromal tumors representing 12% of primary tumors in MD. Rare histological subtypes include pancreatic carcinoma and intraductal papillary mucinous neoplasms.<sup>12,13</sup>

## CONCLUSION

MD is largely asymptomatic or an incidentaloma. However, appreciation of the various types of clinical presentation of MD shall help in considering MD as a differential diagnosis in patients with abdominal complaints. Proper histopathology confirms heterotopia and malignancy where present.

## ACKNOWLEDGMENT

We sincerely acknowledge all our patients and the staff of Departments of Surgery and Pathology.

## REFERENCES

- Daniels IR. Historical perspectives on health: Johann Friedrich Meckel the younger and his diverticulum. *J R Soc Promot Health*. 2000;120(2):125-126. <https://doi.org/10.1177/146642400012000211>
- Meckel J. About the diverticula of the intestinal canal. *Arch Physiol*. 1809;9:421-453.
- Gan T and Evers BM. Small Intestine. In: Townsend CM, Beauchamp RD and Mattox KL, editors. *Sabiston Textbook of Surgery: The Biological Basis of Modern Surgical Practice*. 21<sup>st</sup> ed. Missouri: Elsevier; 2022. p. 1288-1290.
- Simms MH and Corkery JJ. Meckel's diverticulum: Its association with congenital malformation and the significance of atypical morphology. *Br J Surg*. 1980;67(3):216-219. <https://doi.org/10.1002/bjs.1800670316>
- Ley's CM. Meckel Diverticulum. In: Holcomb GW, Murphy JP and Peter S editors. *Holcomb and Ashcraft's Pediatric Surgery*. 7<sup>th</sup> ed. China: Elsevier; 2020. p. 641-646.
- Horn F, Trnka J, Simicková M, Duchaj B and Makaiová I. Symptomatic Meckel's diverticulum in children. *Rozhl Chir*. 2007;86(9):480-482.
- Sagar J, Kumar V and Shah DK. Meckel's diverticulum: A systematic review. *J R Soc Med*. 2006;99(10):501-505. <https://doi.org/10.1177/014107680609901011>
- Chirdan LB, Yusufu LM, Ameh EA and Shehu SM. Meckel's diverticulitis due to *Taenia saginata*: Case report. *East Afr Med J*. 2001;78(2):107-108. <https://doi.org/10.4314/eamj.v78i2.9099>
- Cartanese C, Petitti T, Marinelli E, Pignatelli A, Martignetti D, Zuccarino M, et al. Intestinal obstruction caused by torsed gangrenous Meckel's diverticulum encircling terminal ileum. *World J Gastrointest Surg*. 2001;3(7):106-109. <https://doi.org/10.4240/wjgs.v3.i7.106>
- Seth A and Seth J. Axial torsion as a rare and unusual complication of a Meckel's diverticulum: A case report and review of the literature. *J Med Case Rep*. 2011;5:118. <https://doi.org/10.1186/1752-1947-5-118>
- Kumar KR, Rao BA, Krishna DM, Raju KA and Phaniteja P. Meckel's diverticulum and its presentations: A case series. *Int J Sci Stud*. 2015;3(9):173-176. <https://doi.org/10.17354/ijss/2015/579>
- Sharma RK and Jain VK. Emergency surgery for Meckel's diverticulum. *World J Emerg Surg*. 2008;3:27. <https://doi.org/10.1186/1749-7922-3-27>
- Dumper J, Mackenzie S, Mitchell P, Sutherland F, Quan ML and Mew D. Complications of Meckel's diverticula in adults. *Can J Surg*. 2006;49(5):353-357.

### Authors Contribution:

**JBS-** Design, data collection, manuscript review; **RDP-** data collection, proof reading; **DS-** manuscript writing, design, research, treating surgeon; **BKG-** concept, review of literature.

### Work attributed to:

North Bengal Medical College and Hospital, Sushrutnagar, West Bengal, India.

### Orcid ID:

Dr. Jaya Bagchi (Samaddar) - <https://orcid.org/0000-0003-4905-8820>

Dr. Rupsha Dutta (Pal) - <https://orcid.org/0009-0001-6480-8696>

Dr. Dwaipayan Samaddar - <https://orcid.org/0000-0002-5513-9494>

Prof. (Dr.) Bidyut Krishna Goswami - <https://orcid.org/0000-0003-4806-5949>

**Source of Support:** Nil, **Conflicts of Interest:** None declared.