

Cervical intradural extramedullary chaotic lipoma in an elderly patient: A rare case report



Anurup Saha¹, Sibaji Dasgupta²

¹Post-Doctoral Resident, ²Assistant Professor, Department of Neurosurgery, Bangur Institute of Neurosciences, IPGMER and SSKMH, Annex-I, Kolkata, West Bengal, India

Submission: 22-08-2023

Revision: 27-10-2023

Publication: 01-12-2023

ABSTRACT

Intradural spinal lipoma (ISL) prevalent in children and young adults usually presents with spastic progressive quadriparesis, sensory disturbances, and gait abnormalities. Chaotic lipomas named due to their haphazard distribution are an extremely rare variant of ISL present at the dorsal root entry zone. We describe a case of chaotic spinal lipoma and elucidate the challenges faced in the management of this entity.

Key words: Intradural spinal lipoma; Dorsal root entry zone; chaotic

Access this article online

Website:

<http://nepjol.info/index.php/AJMS>

DOI: 10.3126/ajms.v14i12.57876

E-ISSN: 2091-0576

P-ISSN: 2467-9100

Copyright (c) 2023 Asian Journal of Medical Sciences



This work is licensed under a Creative Commons Attribution-NonCommercial 4.0 International License.

INTRODUCTION

Intradural spinal lipoma (ISL) constitutes approximately <1% of all spinal tumors and is usually associated with spinal dysraphism.¹ ISLs unassociated with spinal dysraphism are rare with only a few cases being reported in the literature.²⁻⁴ They are usually detected in children and young adults and are situated on the posterior aspect of the spinal cord in the cervicothoracic or thoracic regions. Association with elderly patients is very rare like in our case. The patients commonly present with a longstanding neurological disability followed by a rapid progress of symptoms. The presenting complaints are spastic weakness in the extremities, dysesthetic sensory changes, and gait difficulties. The neurological deficits are initially subtle and the history can span many years before the patient seeks medical attention.

Theories about their pathogenesis are controversial, but the malformation theory wherein inclusion of the misplaced adipocytes during the formation of the neural tube causes the growth of lipoma. Some believe intraspinal lipomas are congenital lesions and would not only compress but also replace normal tissue during development.⁵ A spinal lipoma without dysraphism has only a small space for expansion and thus, has an early presentation of symptoms as seen in our case. Chaotic lipomas are an extremely rare variant of spinal lipomas. This entity was first defined in 2009 by Pang et al.⁶ Not much has been written about this variant. Its characteristic is the haphazard distribution of dorsal root entry zone, nerve roots, and placode-lipoma interface. Thus complete/near-total excision of this lesion is quite difficult. We describe a case of chaotic spinal lipoma and elucidate the challenges faced in the management of this entity.

Address for Correspondence:

Dr. Sibaji Dasgupta, Department of Neurosurgery, Bangur Institute of Neurosciences, IPGMER and SSKMH, Annex-I, Kolkata-20, West Bengal, India. **Mobile:** +91-9831605074. **E-mail:** drsibaji2010@gmail.com

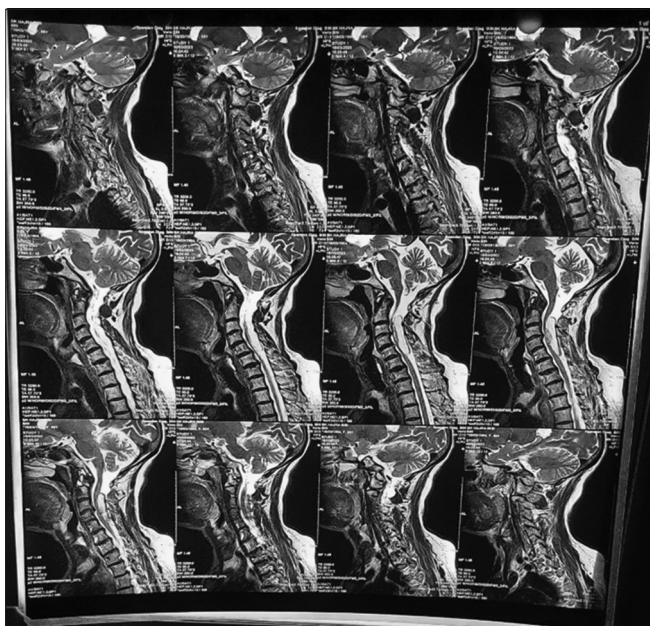

Figure 1: Sagittal T2-weighted images showing the intradural SOL at C2-C5

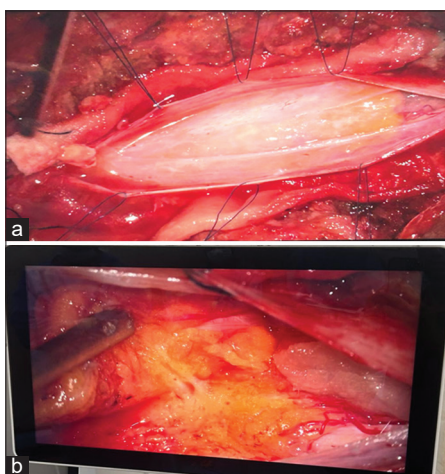


Figure 2: (a) Intraoperative image showing intradural lipoma after midline durotomy (b) Resection of lipoma sparing the nerve roots



Figure 3: Post-operative day 5 showing clinical neurological improvement

CASE REPORT

A 55-year-old lady presented with gradually progressive weakness of all four limbs, in an ascending fashion with pyramidal distribution, difficulty in walking, and numbness in her legs for the past 6 months. There was no cranial nerve involvement, trigeminal sensory loss, or features of Horner's syndrome. She had become wheelchair bound for the past 1 month. However, there was no history of bowel or bladder involvement. Clinical examination did not reveal any stigmata such as dimples, hair, fistulae, or any mass on her spine. Neurological examination showed spastic quadriparesis with 3/5 grade bilateral power in all four limbs. All sensations were markedly diminished below the C2 level. There was no dissociation between joint position and vibration sense. MRI scans revealed a hyperintense, elongated mass intradural extramedullary lesion on the sagittal T1W and T2W images between the C2-C5 segments (Figure 1). Axial T1W image showed that the lipoma was situated dorsal to the spinal cord.

A C2-C6 laminectomy was done and the dura mater was opened in the midline and retracted. A lipoma was identified on the posterior aspect of the cord and there was no clear surgical cleavage between the cord, nerve roots, and the tumor in conformity to a chaotic lipoma. Near total excision was carried out under microscopic guidance with preservation of the nerve roots within (Figure 2a and b). There was a significant neurological improvement with 4/5 power in all four limbs and could be mobilized with support at 1-week post-surgery (Figure 3).

DISCUSSION

Spinal lipoma is a congenital lesion and not a neoplasm, and histologically, spinal intramedullary lipoma is an admixture of lobulated fatty tissue separated by delicate connective tissue and intervening neural tissues.^{1,4} Therefore, if they are asymptomatic, they may be left alone without treatment.¹ However, if symptoms progress, surgical debulking is recommended. Aggressive removal of this mass is not necessary.^{6,7} Even if patients are symptomatic, decompression only is sufficient.^{1,2} Furthermore, the infiltrative nature of the lipoma hinders gross total removal.

Early surgical decompression prevents irreversible spinal cord dysfunction because most symptomatic patients usually do not improve after surgery.³ Therefore, the operative principle is decompression before symptom progression.⁵

CONCLUSION

ISLs are not a frequent spinal space-occupying lesion, they are associated with varied neurologic deficits, and early surgical decompression without attempts for complete excision is an ideal therapeutic option associated with satisfactory neurologic improvement, and serial MRI for follow-up is mandatory.

REFERENCES

1. Giuffre R. Intradural spinal lipomas. Review of the literature (99 cases) and report of an additional case. *Acta Neurochir (Wien)*. 1966;14(1):69-95.
<https://doi.org/10.1007/BF01401892>
2. Ammerman BJ, Henry JM, De Girolami U and Earle KM. Intradural lipomas of the spinal cord. A clinicopathological correlation. *J Neurosurg*. 1976;44(3):331-336.
<https://doi.org/10.3171/jns.1976.44.3.0331>
3. Fujiwara F, Tamaki N, Nagashima T and Nakamura M. Intradural spinal lipomas not associated with spinal dysraphism: A report of four cases. *Neurosurgery*. 1995;37(6):1212-1215.
<https://doi.org/10.1227/00006123-199512000-00024>
4. Kim CH, Wang KC, Kim SK, Chung YN, Choi YL, Chi JG, et al. Spinal intramedullary lipoma: Report of three cases. *Spinal Cord*. 2003;41(5):310-315.
<https://doi.org/10.1038/sj.sc.3101441>
5. Lee M, Rezai , Abbot R, Coelho DH and Epstein FJ. Intramedullary spinal cord lipomas. *J Neurosurg*. 1995;82(3):394-400.
<https://doi.org/10.3171/jns.1995.82.3.0394>
6. Pang D, Zovickian J and Oviedo A. Long-term outcome of total and near-total resection of spinal cord lipomas and radical reconstruction of the neural placode: Part I-surgical technique. *Neurosurgery*. 2009;65(3):511-528; discussion 528-529.
<https://doi.org/10.1227/01.NEU.0000350879.02128.80>
7. El-Mostarchid B, Ali A, Maftah M, Mansouri A, Laghzioui J, Kadir B, et al. Non-dysraphic intramedullary spinal cord lipoma. A case report. *Joint Bone Spine*. 2002;69(5):511-514.
[https://doi.org/10.1016/s1297-319x\(02\)00440-2](https://doi.org/10.1016/s1297-319x(02)00440-2)

Authors Contribution:


AS- Literature survey, prepared the first draft of a manuscript, data collection, data analysis, preparation of manuscript, and submission of an article;
SD- Concept, design, clinical preparation, and manuscript revision.

Work attributed to:

Department of Neurosurgery, Bangur Institute of Neurosciences, IPGMER and SSKMH, Annex –I, Kolkata, West Bengal, India.

Orcid ID:

Anurup Saha-  <https://orcid.org/0009-0008-9497-8136>

Sibaji Dasgupta-  <https://orcid.org/0000-0002-2275-3519>

Source of Support: Nil, **Conflicts of Interest:** None declared.