

# A case of cirroid aneurysm: Case report



Jolly Sinha<sup>1</sup>, Avdhesh Shukla<sup>2</sup>, Vivek Kumar Kankane<sup>3</sup>, Avinash Sharma<sup>4</sup>, Kundan Kumar<sup>5</sup>

<sup>1,5</sup>Senior Resident, <sup>2,4</sup>Professor, <sup>3</sup>Associate Professor, Department of Neurosurgery, Gajra Raja Medical College, Gwalior, Madhya Pradesh, India

Submission: 14-08-2023

Revision: 23-11-2023

Publication: 01-01-2024

## ABSTRACT

Scalp cirroid aneurysm is an arteriovenous fistula of the scalp that is usually unconnected by intracranial or cerebral vessels. Variceal dilatation of draining veins can produce cosmetic concerns, masses, local pain, palpable thrills, audible bruits, headache, tinnitus, and torrential hemorrhage. Its etiopathogenesis is not well understood. Treatment includes surgery (fistula repair by simple surgical ligation until gross total resection), embolization (whether percutaneous or endovascular), or a combination of the two. Here is a case report of a 40-year-old male patient who had right superficial temporal artery cirroid aneurysm who underwent surgical ligation with complete excision of the lesion.

**Key words:** Cirroid aneurysm; Ligation; Embolization; Superficial temporal artery

### Access this article online

**Website:**

<http://nepjol.info/index.php/AJMS>

**DOI:** 10.3126/ajms.v15i1.57609

**E-ISSN:** 2091-0576

**P-ISSN:** 2467-9100

Copyright (c) 2024 Asian Journal of Medical Sciences



This work is licensed under a Creative Commons Attribution-NonCommercial 4.0 International License.

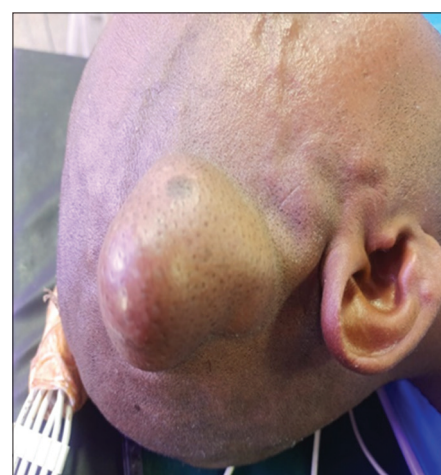## INTRODUCTION

Scalp arteriovenous malformations, also known as cirroid aneurysms, are rare lesions that are congenital, traumatic, or postinfectious in nature. These lesions may be found incidentally or owing to signs and symptoms that they produce, such as an enlarging pulsatile mass, headache, tinnitus, or bleeding. These lesions often constitute high-flow arterial blood from the superficial temporal or occipital arteries with venous outflow into extracranial venous structure. Treatment includes surgery (fistula repair by simple surgical ligation until gross total resection), embolization (whether percutaneous or endovascular), or a combination of the two.<sup>1</sup>

## CASE REPORT

A 40-year-old male came with a swelling in the right frontotemporal region since childhood which was growing

progressively in size. The patient had complaints of headache and growing size of the swelling for which he was cosmetically concerned as shown in Figure 1. The

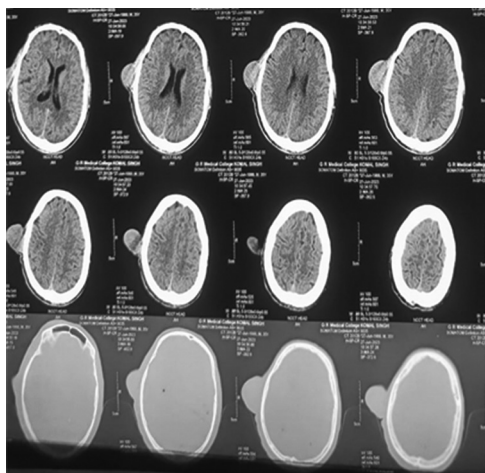


**Figure 1:** Gross image of the cricoid aneurysm

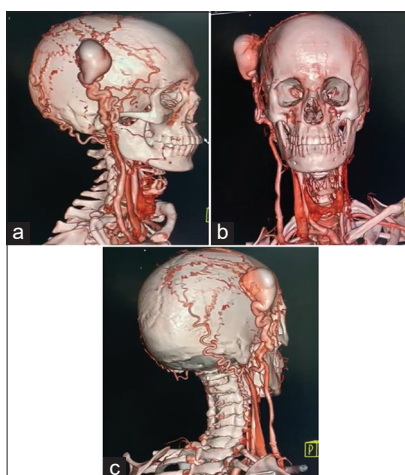
### Address for Correspondence:

Dr. Avdhesh Kumar Shukla, Department of Neurosurgery, Gajra Raja Medical College, Gwalior, Madhya Pradesh, India.

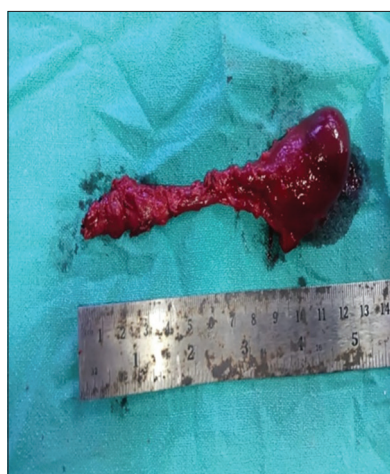**Mobile:** +91-8318100530. **E-mail:** [sinhajolly.gsvm@gmail.com](mailto:sinhajolly.gsvm@gmail.com)



**Figure 2:** Pre-operative non-contrast computed tomography head of the patient showing hyperdense frontoparietal lesion



**Figure 3:** (a-c) Computed tomography angiography of the head and neck showing arteriovenous malformation of the right superficial temporal artery



**Figure 4:** Excised cirroid aneurysm

swelling was soft, pulsatile with palpable thrills and bruit. The swelling diminished in size when the feeder vessels were compressed.

Non-contrast computed tomography head showed a hyperdense lesion in the right frontoparietal region with no intracranial communication as shown in Figure 2.

Computed tomography angiography showed a hyperdense nidus of approximate size 3.8×2.8×2 cm in the right parietal region with multiple serpentine vascular channels in the frontotemporoparietal region with feeding artery from the right superficial temporal artery and draining into the right external jugular vein with no evidence of intraparenchymal communication as shown in Figures 3a-c.

Surgical ligation of the right superficial temporal artery along with other small feeders was performed with complete excision of the arteriovenous malformation (AVM) as shown in Figure 4.

Patient recovered well in the post-operative period with healthy surgical site and was discharged on the 8<sup>th</sup> post-operative day after suture removal.

## DISCUSSION

Aberrant persistence of primitive arteriovenous interconnections is known as AVM. Scalp AVM is rare despite the intense vascularity of scalp and relatively high frequency of trauma to this region.<sup>2-4</sup> The etiology of cirroid aneurysm is still controversial. It is accepted that it may be either congenital or traumatic. Congenital was more common in large series published in the literature.<sup>5,6</sup>

## CONCLUSION

The scalp AVM described was successfully excised. Consideration of risks of intracranial venous drainage must be taken into account when evaluating AVM anatomy.

## REFERENCES

1. Sousa LH, Gatto LA, Junior Z and Koppe GL. Scalp cirroid aneurysm: An updated systematic literature review and an illustrative case report. *World Neurosurg.* 2018;119:416-427. <https://doi.org/10.1016/j.wneu.2018.08.098>

2. Barhate MV, Vhora SS and Pandey RK. Cirroid aneurysm of the scalp: A case report. *Indian J Neurosurg.* 2016;5(2):129.  
<https://doi.org/10.1055/s-0036-1581974>
3. Muthukumar N, Rajagopal V, Manoharan AV and Durairaj N. Surgical management of cirroid aneurysms. *Acta Neurochir (Wien).* 2002;144(4):349-335.  
<https://doi.org/10.1007/s007010200048>
4. Nagasaka S, Fukushima T, Goto K, Ohjimi H, Iwabuchi S and Maehara F. Treatment of scalp arteriovenous malformation. *Neurosurgery* 1996;38(4):671-677, discussion 677.
5. Khodadad G. Familial cirroid aneurysm of the scalp. *J Neurol Neurosurg Psychiatry.* 1971;34(6):664-667.  
<https://doi.org/10.1136/jnnp.34.6.664>
6. Gurkanlar D, Gonul M, Solmaz I and Gonul E. Cirroid aneurysms of the scalp. *Neurosurg Rev.* 2006;29(3):208-212.  
<https://doi.org/10.1007/s10143-006-0023-y>

**Author's Contributions:**

**JS-** Definition of intellectual content, literature survey, prepared first draft of manuscript, Implementation of study protocol, data collection, data analysis, manuscript preparation and submission of article; **VKK-** Concept, design, clinical protocol, manuscript preparation, editing and revision; **AS-** Review manuscript; **AS-** Coordination and manuscript revision; **KK-** Data collection and analysis.

**Work attributed to:**

Department of Neurosurgery, Gajra Raja Medical College, Gwalior, Madhya Pradesh, India.

**Orcid ID:**

Jolly Sinha - <https://orcid.org/0009-0004-4412-3691>

Vivek Kumar Kankane - <https://orcid.org/0000-0001-9068-7886>

Avdhesh Shukla - <https://orcid.org/0000-0003-3583-8332>

Avinash Sharma - <https://orcid.org/0000-0002-2178-3070>

Kundan Kumar - <https://orcid.org/0009-0009-9372-3649>

**Source of Support:** Nil, **Conflicts of Interest:** None declared.