

Endoscopic features of non-IBD colitis



Flavia Pigò¹, Reggiani Bonetti Luca², Conigliaro Rita³

¹Junior Resident, ³Chief Resident, Endoscopy Unit, Azienda Ospedaliero Universitaria of Modena, Civil Hospital of Baggiovara, ²Associate Professor, Department of Pathology, Polyclinic Hospital, University of Modena, Modena, Italy

Submission: 12-07-2023

Revision: 29-10-2023

Publication: 01-12-2023

ABSTRACT

Background: Studies about the endoscopic aspect of non-inflammatory bowel disease (IBD) colitis are scarce. **Aims and Objectives:** The aim of this retrospective study was to describe the endoscopic appearance of non-IBD colitis (NIC) in an outpatient cohort. **Materials and Methods:** All cases of NIC, from 2018 to 2021, with a recent outpatient colonoscopy, were enrolled. Diagnosis was based on clinical, endoscopic, and histological characteristics, and follow-up ≥ 6 months to recognize misdiagnosed IBD because of mimic causes. **Results:** 158 patients (63 males, age 54 years \pm 19) performed a colonoscopy with a final diagnosis of NIC associated with drug-exposition (74), food allergies (26), recent/active gastrointestinal infections (20), ischemic colitis (14), segmental colitis associated diverticulosis (SCAD) (10), obstructed defecation syndrome (ODS) (8) and microscopic colitis (6). Frequencies of endoscopic features and colon distribution were: Drug exposition (hyperemia, erosions/ulcers, 88%; right colon, 70%), recent infection (erosions, 60%; left colon/rectum, 88%), food allergies (red spots/erosions, 67%; all the colon), ischemic colitis (ulcers, 86%; right or left colon), SCAD (hyperemia/edema, 75%; always left colon), ODS (hyperemia, erosions, and loss of vascularity, 90%; always rectum), microscopic colitis (edema and hyperemia; all the colon). **Conclusion:** Drug-exposition is the most frequent cause of out-patient NIC. In an appropriate diagnostic context, red spots, hyperemia, and erosions are associated with drug expositions, recent infections, and food allergies. Ulcers are more frequent with ischemic colitis or drug-exposition.

Key words: Endoscopy; Non-IBD colitis; Outpatients

Access this article online

Website:

<http://nepjol.info/index.php/AJMS>

DOI: 10.3126/ajms.v14i12.56578

E-ISSN: 2091-0576

P-ISSN: 2467-9100

Copyright (c) 2023 Asian Journal of Medical Sciences



This work is licensed under a Creative Commons Attribution-NonCommercial 4.0 International License.

INTRODUCTION

The term non-inflammatory bowel disease colitis (NIC) refers to a variety of inflammatory diseases of the colon, which may be differentiated from Crohn's disease (CD) and ulcerative colitis (UC) by their clinical, endoscopic, and histological characteristics. Real incidence during routine colonoscopy is not established, but previous studies on selected cohorts of patients reported a correlation with drugs and infections.¹⁻³

Aims and objectives

The aim of the study was to describe the endoscopic appearance of NIC in an out-patient cohort.

MATERIALS AND METHODS

Patients

This retrospective study reviewed all cases of NIC in an out-patient base setting from 2018 to 2021. A single gastroenterologist evaluated all patients who received a diagnosis of colon inflammation during a colonoscopy performed in the previous 3 months. All colonoscopies and visits were performed in a single Hospital (Civil Hospital of Baggiovara, Modena, Italy).

During the evaluation, the diagnosis was assumed on the following characteristics: age, sex, symptoms (onset, duration, severity), comorbidities, history of exposure to drugs during the 3 months preceding the consultation,

Address for Correspondence:

Flavia Pigò, Endoscopy Unit, Azienda Ospedaliero Universitaria of Modena, Civil Hospital of Baggiovara, Modena, Italy.

Mobile: 00390593961269. **E-mail:** pigo.flavia@aou.mo.it

smoking and alcohol habits, allergies, pathological familiar history, laboratory evaluations, stool cultures, imaging, bowel preparation, colonoscopy findings, histologic findings, follow-up of at least 6 months.

We excluded cases of inflammatory bowel disease (IBD) (UC, CD), and adequate follow-up was useful to recognize misdiagnosed cases because of mimic causes.

Procedures

All colonoscopies were performed under conscious or deep sedation. Cecum and terminal ileum exploration was always reached. In our hospital, 2–4 biopsies for each colon segment are recommended from the pathologist, including terminal ileum and correctly oriented. The most proximal biopsy is placed at one end of the filters signed by clarinet beak-shaped cut (Bio-Optica®, Milan, Italy), and the most distal biopsies are placed at the opposite end.

Ten endoscopists performed the examinations describing the appearance of colitis with various terms (Figure 1):

- Hyperemia/erythema: Spots or coalescent areas of red mucosa
- Oedema: areas of swollen mucosa
- Erosions: Small, shallow sores. They are frequently encircled by a ring of red, inflammatory tissue. They can also have an uneven shape, such as lengthy, ragged markings
- ULCERS: Caused by breaks in the lining of the mucosa due to inflammation. Small ulcers are also called aphthous ulcers; bigger ulcers can be star-shaped, angular, transverse, longitudinal, occasionally with a cobblestone appearance
- Stricture: Narrowing of the lumen of the colon such as to prevent the passage of the colonoscope

- Pseudopolyps: Scar tissue masses that form during the healing phase following inflammation.

Diagnosis

Drug-induced colitis

The incidence of non-steroidal anti-inflammatory drugs (NSAID) induced colitis is reported as 10% of all cases of colitis. NSAIDs are the most common prescribed drugs worldwide, and most reports of drug-induced colitis have been related to their use.³

Knowledge of the temporal relationship between the medication start date and the onset of symptoms is critical for the diagnosis of drug-induced colitis. Different mechanisms are associated to the damage of colonic mucosa (vasospasm, thrombogenesis, direct mucosal cytotoxicity, immune dysregulation). Various drugs are implicated in damage of the colon: Cocaine, ergotamine, estrogen, sodium polystyrene, alosetron, amphetamines, pseudoephedrine, and vasopressin. Narcotics, phenothiazines, vincristine, atropine, nifedipine, tricyclic antidepressants, flutamide, lansoprazole, and ticlopidine.^{4,5}

NSAIDs are the most frequent drugs associated to NIC. Different pathological findings have been reported. Mucosal ulceration, collagenous colitis, non-gangrenous ischemic colitis, and localized active colitis are examples. Often, endoscopy shows flat or slightly elevated circular hyperchromic lesions compared to the surrounding mucosa, sometimes with an erythematous border, distributed along a small vessel (“cherry tree” appearance). Most of the ulcers are in the right colon. Previous research has found that ulcers prefer the cecum and ascending colon, which has been linked to a higher concentration of the medication

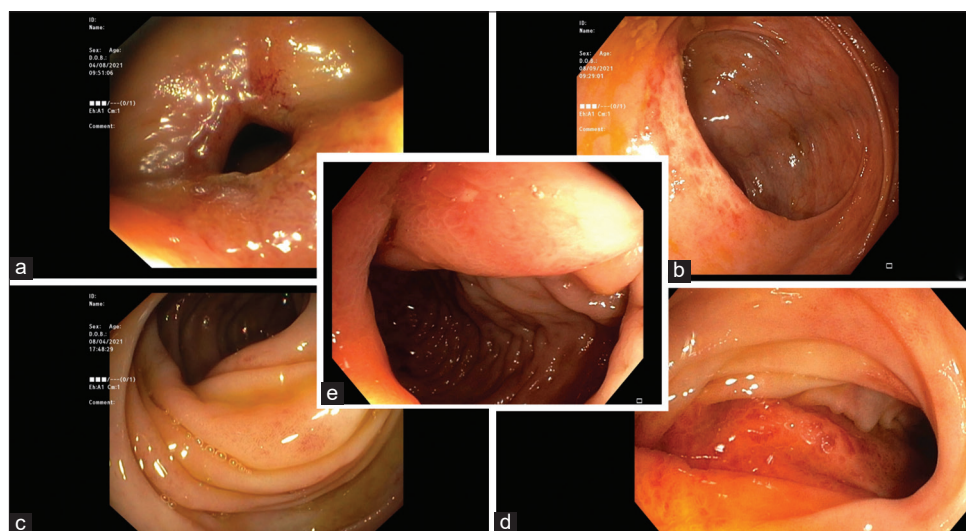


Figure 1: Endoscopic features of non-IBD colitis. Stricture (a). Ileo-cecal valve ulcer (b). Oedema with spot hyperaemia (c). Oedema with coalescent erythema (d). Oedema with aphthous ulcers (e)

in the proximal colon. Strictures are described as well. A strong eosinophilic infiltration is the most prevalent yet non-specific observation. Hemorrhages, hematomas, fibrosis, and epithelial apoptosis are also described.^{6,7}

Also, immune checkpoint inhibitors, anti-interleukin-17, mofetil mycophenolate, chemotherapeutic agents, antibiotics, corticosteroids, gold salt therapy, antifungal agent 5-flucytosine, methyl dopa are associated with cytotoxic effects and immune dysregulation in colonic mucosa.⁸⁻¹⁵

Ischemic colitis

Ischemic colitis refers to a collection of gastrointestinal lesions brought on by the colon and rectum's inadequate blood supply. It involves arterial, venous, or chronic ischemia. The diagnosis is made using a mix of histology, radiological, and clinical suspicion. The most frequent observations in patients with the early onset of ischemic colitis are oedematous and fragile mucosa, segmental erythema, petechial hemorrhages, longitudinal ulcer, and lesions that are always segmented and patchily distributed.¹⁶ The highly specific term "single stripe" describes a single line of erythema with an inflammatory erosion or ulceration along the longitudinal axis of the colon.¹⁷ Ischemic lesions can occasionally develop tumor-like lesions that resemble malignant tumors.¹⁸ A gray-green or black staining of the mucosa, frequently accompanied by pseudomembranes, indicates severe damage. Strictures can also result from chronic ischemia. Atrophic crypts lined with tiny, crowded, or hemorrhagic stroma are among the histological findings in acute cases. Coagulation necrosis and capillary microthrombi are also occasionally seen, mainly in the acute early stages.^{19,20}

Infectious colitis

Colon inflammation brought on by bacterial, viral, fungal, or parasitic diseases is referred to as infectious colitis. Bacterial infection is the most frequent cause in Western nations, whereas parasitic infection is far more frequent in underdeveloped nations.²¹ When compared to IBD, which can sometimes have an insidious onset, acute self-limited (infectious type) colitis often presents with sudden onset of symptoms. However, IBD can occasionally also show with an acute onset since an infectious agent can be the triggering element.

A combination of positive cultures for common infections, parasitology, and toxin testing, as well as serological and molecular tests, as well as recognizable histological abnormalities on rectal biopsies, are used to make the diagnosis of infectious colitis. Patchy or diffuse mucosal edema and erythema could be observed. Sometimes also, ulcerations, mucopurulent exudate are associated

with infectious colitis. The rectum may be intact early in infectious colitis; lesions tend to travel distally and merge as time passes after the commencement of the disease. Histologically, normal architecture, an intensive neutrophilic infiltrate in the early stages of inflammation, mucin depletion, discontinuous inflammation, and localized cryptitis are characteristics that suggest acute self-limiting colitis. However, the importance of each of these results is greatly influenced by how soon after the inflammatory process began and the biopsy was performed. In addition, typical intranuclear inclusions (CMV) or some pathogens can be found in biopsies.^{20,22-24}

Diverticular disease

Some patients with diverticular disease may present with segmental colitis-associated diverticulosis (SCAD), which manifests as abdominal pain and diarrhea. SCAD is characteristically seen over the age of 60 years, with the spare of the rectum and of the diverticular orifice. SCAD could be observed with different patterns: crescentic fold disease (red round lesions 0.5–1.5 cm at the top of mucosal folds, no architectural crypt distortion, neutrophil, and lymphocyte infiltrates limited to crypt epithelium), mild-to-moderate UC-like (diffuse loss of vascular pattern, edema, hyperemia and pinpoint erosions, crypt distortion present together with chronic changes in lamina propria, crypt abscesses, and goblet cell depletion), CD-like (isolated aphthous ulcers, transmucosal inflammation with microfissures, lymphoid follicles, and non-specific infiltrates), severe UC-like (diffuse ulceration and reduced caliber of lumen, crypt distortion present together with chronic changes in lamina propria, crypt abscesses, and goblet cell depletion).^{25,26}

Eosinophilic colitis

Eosinophilic colitis is a rare disorder that affects the colon exclusively in the absence of a known cause of eosinophilia. It is more common in infants and adolescents, and most infantile cases are thought to be caused by an allergy to soy or cow's milk proteins. Adults with various causes (medication-induced, infection/parasites, food allergy, Churg-Strauss syndrome, scleroderma, radiation colitis, systemic mastocytosis, graft versus host disease, lymphoma, idiopathic) had increased numbers of clustering eosinophils within the lamina propria with architecture preservation. Endoscopic appearance of eosinophilic colitis varies and, in most cases, shows normal mucosa; however, several non-specific endoscopic findings, such as erythematous patchy mucosa, ulcers, polyps, and pseudo-polyps, may be present. Because eosinophils are naturally present in the mucosa of the colon, a reasonable cutoff is defined as >50/high-power field (HPF) in the right colon, >35/HPF in the transverse colon, and >25/HPF in the left colon.^{27,28}

Other diseases

Microscopic colitis is a clinical term for patients who have chronic watery diarrhea and otherwise normal endoscopy but have histologic inflammation of the colonic mucosa. It consists primarily of two histopathologic entities: collagenous colitis and lymphocytic colitis. The mucosa is typically unremarkable at colonoscopy, but minor changes such as mild edema or an opalescent appearance, mild erythema, or a diminished vascular pattern have been reported. Lymphocytic colitis is distinguished on biopsy specimens by intraepithelial lymphocytosis, whereas collagenous colitis is distinguished by the thickening of the subepithelial collagen band.^{29,30} Less frequent causes of NIC are obstructive defecation syndrome, radiation colitis, diversion colitis, and Behcet's colitis.

Statistics

Characteristics were described per patient and sometimes can coexist within the same patient (e.g., comorbidities, drugs assumed, endoscopic patterns, histologic patterns). Variables were expressed as mean±standard deviation if continuous or absolute number and percentage if categorical.

RESULTS

One hundred and fifty-eight patients received a definitive diagnosis of NIC from 2018 to 2021. *Drug-associated colitis* was the most frequent cause observed (74/158 cases, 46%). Patients with drug colitis were predominantly females (59%), with the age of 57±11 years with no specific symptoms. Most frequent drugs associated with colitis were NSAIDs (84%) and vasoactives (49%). In 11 % of cases, a recent antibiotic therapy was recorded. In 3 cases, a monoclonal antibody was associated with ulcers (secukinumab, rituximab) and erosions (ocrelizumab) in all the colon. Right colon was the most involved part (70%) interested with inflammation, described mainly as hyperaemic (46%) and oedematous (41%) mucosa with erosions (46%) and ulcers (49%). In 8 cases, strictures and/or pseudopolyps were observed. Acute (51%) or chronic (95%) inflammation was variably observed with eosinophilic infiltrates (32%).

Infective colitis was observed in 20 patients with age of 44±15 years old. Watery (30%) or bloody (30%) diarrhea were the main symptom of presentation. Involvement of the colon was variable: 40% of cases pancolitis, 40% only left colon, and 10% rectum. Endoscopy described mainly erosions (60%) and hyperemia (40%). In 2 cases, the aspect of mucosa appears normal even if a parasite was found in the feces and histologic inflammation was present. Various pathogens were seen in the stools (*Salmonella*, *Shigella*, *Campylobacter*, *Amebiasis* spp, *Giardia*, *Blastocystis* spp).

Acute (40%) or chronic (90%) inflammatory infiltrates was present with eosinophils (20%), apoptotic cells, and nuclear dust (30%).

Allergic colitis was observed in 26 cases. Age was 54±15 years old; Haematochezia (38%) or bloody diarrhea (31%) were the main symptoms. Pancolitis (46%) or left colon distribution (31%) was observed. Edema of the mucosa (39%), loss of vascular pattern (31%) and red spots (31%) were the characteristics more described during colonoscopy. Eosinophilic infiltrates (38%) and acute inflammation (38%) were the main aspects observed during histology.

SCAD was diagnosed in 10 cases and patients were 67±8 years old. Diarrhea with or without blood, was the main presentation. Localization was always in the left colon in the setting of diverticular disease. Hyperemic red spots (100%) and edema (60%) of the mucosa were frequently observed, even if sometimes erosions (40%) and ulcers (40%) were present. Chronic (80%) or acute (60%) inflammation was observed during microscopic observation with edema too (60%).

Ischemic colitis was observed in 14 cases. Mean age was 71±8 years old. Macroscopic or microscopic blood in the feces was frequently present with or without diarrhea (72%). Left or right colon was interested, with no preference for localization. Ulcers were frequently observed (86%), and sometimes strictures occurred (29%). Chronic inflammation (100%) with glandular distortion (29%) and eosinophilic infiltrates (43%) was observed microscopically. In 29% of cases, vascular thrombi were described.

Obstructed defecation syndrome was observed in 8 cases with a mean age of 36±17 years old. Hematochezia and FOBT were the main presentations. Rectum was the only location involved. Proctitis was described as oedematous (50%) and hyperaemic (75%) mucosa with loss of vascular pattern (75%) and erosions (75%). Chronic inflammation (100%) and eosinophilic infiltrates (75%) were the main histologic characteristics.

Microscopic colitis was associated in 6 cases with macroscopic lesions in all colon (67%). The mean age was 66±3 years old. Loss of vascular pattern (67%), red spots (67%), and sometimes oedema of the mucosa (33%) was described during colonoscopy. Chronic inflammation and eosinophilic infiltrates were described microscopically; the thickening of subepithelial collagen band and significative infiltrates of lymphocytes in the submucosa were described in 5 e 1 cases, respectively. Results are described in Tables 1 and 2.

With respect to the endoscopic appearance, hyperemia, red spots, and edema were common to all types of NIC; ulcers

Table 1: Characteristics of patients

Characteristic	Drug colitis (n=74)	Infectious colitis (n=20)	Allergic colitis (n=26)	SCAD (n=10)	Ischemic colitis (n=14)	ODS (n=8)	MC (n=6)
Age	57±11	44±15	54±15	67±8	71±8	36±17	66±3
Sex (female)	44 (59)	8 (40)	12 (46)	4 (40)	10 (71)	4 (50)	4 (67)
Main symptom							
Watery diarrhea	18 (24)	6 (30)	4 (15)	2 (20)	2 (14)	0	6 (100)
Bloody diarrhea	16 (22)	6 (30)	8 (31)	2 (20)	4 (29)	0	
Haematochezia	14 (19)	0	10 (38)	2 (20)	2 (14)	2 (25)	
FOBT	18 (24)	4 (20)	0	2 (20)	4 (29)	6 (75)	
Abdominal pain	8 (11)	4 (20)	2 (8)	2 (20)	2 (14)	0	
Comorbidities							
None	8 (11)	18 (90)	2 (8)	0	0	0	0
Metabolic disorder	24 (32)	2 (10)	8 (31)	6 (60)	6 (43)	8 (100)	4 (67)
Neurological	14 (19)	0	2 (8)	0	4 (29)	2 (25)	0
Cardiovascular	22 (30)	0	8 (31)	6 (60)	8 (57)	8 (100)	4 (67)
Lung diseases	4 (5)	0	2 (8)	0	0	2 (25)	0
Chronic kidney	6 (8)	0	0	0	2 (14)	8 (100)	0
Chronic liver	0	0	0	0	0	0	0
Musculoskeletal	6 (8)	0	2 (8)	2 (20)	0	8 (100)	0
Neoplastic		0	0	0	0	0	2 (33)
≥3 diseases	8 (11)	0	0	2 (20)	4 (29)	0	2 (33)
Smoke habits	18 (24)	6 (30)	8 (31)	6 (60)	2 (14)	0	2 (33)
Alcohol	18 (24)	8 (40)	4 (15)	0	2 (14)	0	0
Drug consumption							
NSAIDs	62 (84)	6 (30)	10 (38)	6 (60)	8 (57)	0	4 (67)
Vasoactive	36 (49)	0	8 (31)	8 (80)	12 (86)	4 (50)	4 (67)
Oral contraceptive	0	0	2 (8)	0	0	2 (25)	0
Recent antibiotic	8 (11)	0	0	0	0	0	0
≥3 drugs	26 (35)	4 (20)	6 (23)	6 (60)	8 (57)	0	4 (67)

Values expressed as n (%), mean±SD, median (range). SCAD: Segmental colitis associated diverticulosis, ODS: Obstructive defecation syndrome, MC: Microscopic colitis, SD: Standard deviation, ODS: Obstructed defecation syndrome

Table 2: Endoscopic and histologic features of non-IBD colitis

Characteristic	Drug colitis (n=74)	Infectious colitis (n=20)	Allergic colitis (n=26)	SCAD (n=10)	Ischemic colitis (n=14)	ODS (n=8)	MC (n=6)
Extension							
Right colon	32 (43)	0	2 (8)	0	6 (43)	0	0
Left colon	12 (16)	8 (40)	8 (31)	10 (100)	6 (43)	0	2 (33)
Rectum	2 (3)	2 (10)	0	0	0	8 (100)	0
Pancolitis	20 (27)	8 (40)	12 (46)	0	2 (14)	0	4 (67)
Endoscopic							
Hyperaemia	34 (46)	8 (40)	4 (15)	10 (100)	6 (43)	6 (75)	0
Oedema	30 (41)	2 (10)	10 (39)	6 (60)	6 (43)	4 (50)	2 (33)
Loss vascular pattern	14 (19)	2 (10)	8 (31)	0	0	6 (75)	4 (67)
Red spots	10 (13)	6 (30)	8 (31)	0	0	0	4 (67)
Erosions	34 (46)	12 (60)	6 (23)	4 (40)	0	6 (75)	0
Ulcers	36 (49)	6 (30)	2 (8)	4 (40)	12 (86)	2 (25)	0
Stricture	4 (5)	0	0 (0)	0	4 (29)	0	0
Pseudopolyps	4 (5)	0	0	0	0	0	0
None	6 (8)	2 (10)	4 (15)	0	0	0	0
Histopathology							
Glandular distortion	18 (24)	0	8 (31)	2 (20)	4 (29)	0	2 (33)
Acute inflammation	38 (51)	8 (40)	10 (38)	6 (60)	2 (14)	2 (25)	0
Chronic inflammation	70 (95)	18 (90)	0	8 (80)	14 (100)	8 (100)	4 (67)
Oedema	10 (13)	0	4 (15)	8 (80)	0	2 (25)	0
Vascular congestion	2 (3)	0	0	0	0	0	0
Eosinophils	24 (32)	4 (20)	10 (38)	2 (20)	6 (43)	6 (75)	4 (67)
Apoptosis/N. dust	0	6 (30)	6 (23)	0	0	0	0
Vascular thrombi	0	0	0	0	4 (29)	0	0
Coagulation necrosis	0	0	0	0	0	0	0

Values expressed as n (%), mean±SD, median (range). SCAD: Segmental colitis associated diverticulosis, ODS: Obstructive defecation syndrome, MC: Microscopic colitis, SD: Standard deviation

were mainly associated with drug-associated colitis (58%) and ischemic colitis (19%); Strictures were described only in drug colitis and ischemic colitis and pseudopolyps only in NSAIDs colitis (Figure 2).

DISCUSSION

Patients with NIC could have clinical presentation and endoscopic features like those observed with IBD.

Most frequent etiologies include infectious colitis, drug-induced colitis, ischemic colitis, and SCAD. The value of endoscopy alone in distinguishing IBD from NIC is not well studied.

This retrospective review of a cohort of patients with the diagnosis of NIC colitis aimed helping to improve the differential diagnosis. As in our cohort, among causes of NIC, drug induced is the most studied.

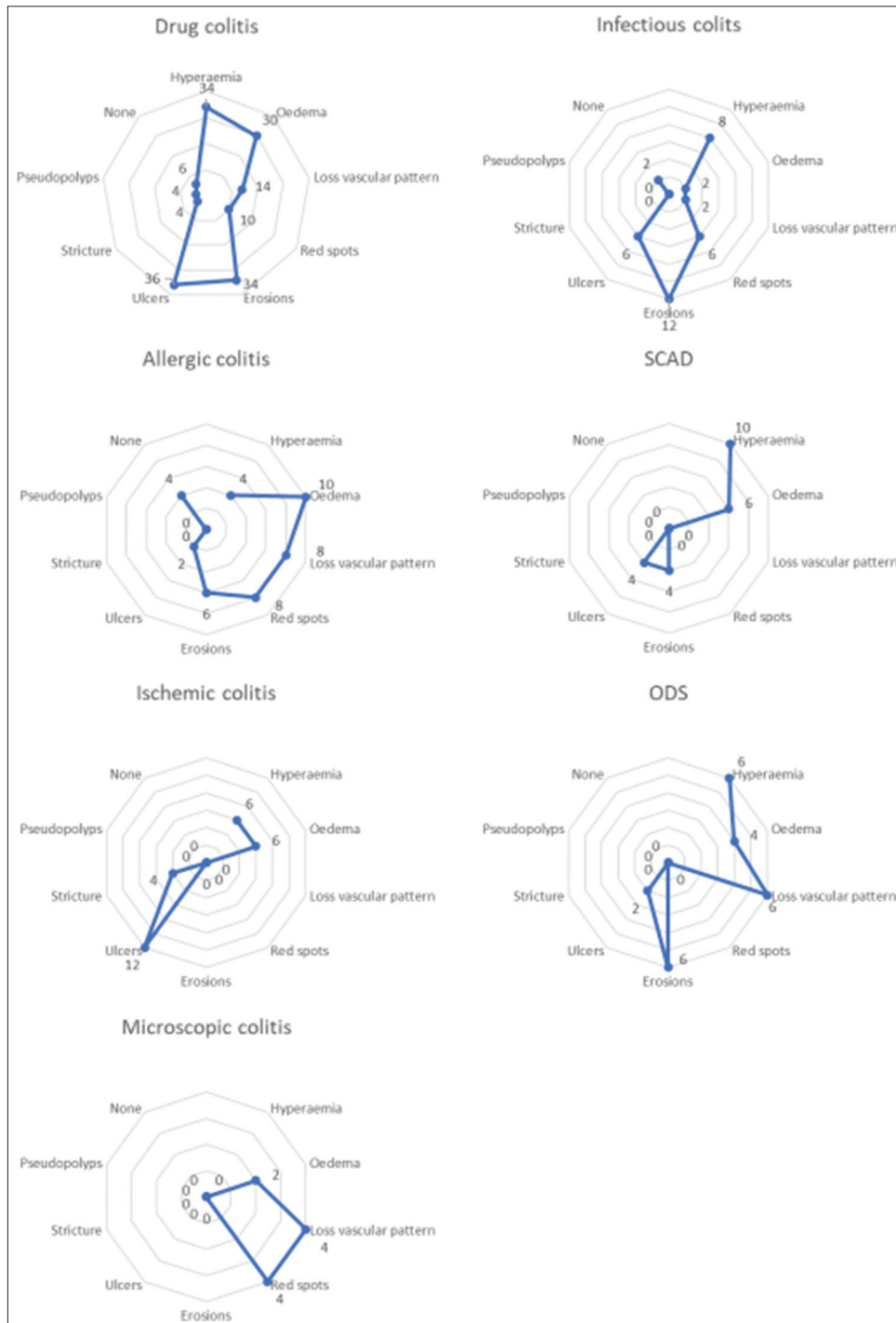


Figure 2: Radar chart of endoscopic aspects for each kind of non-IBD colitis

Drug-induced colitis

Brechmann et al.,³¹ described 211 patients with drug-induced colitis. The endoscopic features included erythema (46.9%), edema (29.9%), erosions (29.9%), and ulcers (14.7%). The inflammation affected the rectum rarely (2.4%) but affected the rest of the colon without predilection in a segmental manner ($P < 0.05$).

In our series, endoscopic manifestation of drug colitis, ulcers (49%), and erosions (46%), were more frequent sometimes with observation of pseudopolyps (5%) and stricture (5%). Cohort of patients described in the study of Brechmann et al., referred to in-patients and triggers associated with colitis were fibrates, NSAIDs, and atherosclerosis. As in our series, NSAIDs are the main drug related to NIC; multiple comorbidities, especially vascular diseases, can contribute directly (through ischemic mechanism) or indirectly (through vasoactive drugs) to the inflammation of the colon.

In other series of 11, 14, and 24 patients exposed to NSAIDs, endoscopy revealed flat ulcers in the entire colon being more severe in the right colon; cases of concentric “diaphragm-like” strictures were seen, all located in the right colon and in the remainder endoscopy nonspecific erosions.^{6,32-34}

The incidence of drug colitis is not definitively established. It is reported that approximately 10% of newly diagnosed colitis may be related to NSAIDs administration.³ In our study, the incidence of drug colitis (mainly related to NSAIDs and vasoactive drugs) is superior (46%). This difference with previous studies could be related by the inclusion of out-patients and with a definitive diagnosis; in fact, an accurate anamnesis is crucial for the association between drug exposure and symptoms.

Stolte et al., investigated biopsy materials obtained from 611 patients taking NSAIDs/ASA in 86% of cases. Endoscopic inspection revealed multiple erosions and/or ulcers in 60.6%, strictures in 15.8%, and diaphragms in 3.0% of the patients. The lesions were located mainly in the right colon, including the transverse colon (79.9%). This data supports our observations that ulcers and stricture are associated with drug colitis and ischemic colitis.³⁴

Recently monoclonal antibodies and immune checkpoint inhibitors have been implicated in causing diarrhoea; In a series of 92 patients symptomatic for diarrhea and treated with anticytotoxic T-lymphocyte antigen-4, antiprogrammed death receptor-1 or a combination of both developed in 42 cases, a pancolitis with ulcers in 32% of cases. In our series, we reported 3 cases associated with monoclonal antibodies underlying this burgeoning cause of diarrhea.³⁵

Other causes of NIC

In our study, other causes of NIC were less frequent maybe because we included only outpatients and adults. Most frequent described etiologies are ischemic, infective non-IBD forms of colitis, microscopic colitis, Behçet’s syndrome, diversion colitis, diverticular colitis, eosinophilic colitis, ischemic colitis, and radiation colitis. Ischemic and infective colitis, especially if severe, usually necessitate of recovery and are rarely seen in outpatient settings. Data on cohorts of patients with non-specific ulcers or erosions of the colon are aged and scarce.³⁶⁻³⁸ Eosinophilic colitis, related to allergies, similarly, are more frequent in a pediatric setting. Moreover, an association between positivity to allergic tests and symptoms is not well established in adults.³⁹ Similarly, diagnosis of infective colitis is not always proved. In a large population-based study, only 16% were identified as proven infectious gastroenteritis. Most acute gastroenteritis present with transient and self-limited symptoms and rarely require colonoscopy.⁴⁰ We have observed various endoscopic features for infectious colitis; from minimal manifestations such as hyperemia, loss of the vascular pattern, edema up to 40% of cases, to more important manifestations such as erosions, ulcers. In 10% of cases, no endoscopic signs were observed, but the diagnosis was hypothesized because of the recent onset of symptoms, typical histological features, and stool examination. This may be related to the different times of endoscopic observation with respect to the time of infection onset. Among emergent causes of NICSCAD and MC are becoming a frequent scenarios during colonoscopy. Colon diverticulosis is frequent, especially among older age and the prevalence of SCAD varies between 1.15% and 11.4% amongst those suffering from diverticular disease.^{41,42} Crescentic fold disease and mild-to-moderate UC-like pattern account for 80% of endoscopic patterns as in our series but sometimes ulcers can occur resembling IBD.⁴³ In our series, 4 cases of microscopic colitis presented macroscopically visible features, mainly edema, hyperemia and loss of the vascular pattern. In the literature, there are several similar reports even if it is not yet established whether this could imply a different clinical evolution. The review of Koulaouzidis and Saeed collected 42 relevant reports for a total of 88 patients with collagenous colitis and endoscopic findings. Typical findings were alteration of the vascular mucosal pattern, mucosal nodularity, a sequence of change from mucosal defects to mucosal cicatricial lesions. Only one publication describing a distinct endoscopic pattern in LC.^{44,45}

Limitations of the study

This study has some limitations. First, the small number of cases depending on the type of etiology of NIC which may have underestimated or overestimated the specific endoscopic characteristics of each type of colitis.

Furthermore, the diagnostic evaluation was performed by only one doctor; diagnostic validation by more than one specialist may have improved the accuracy of the final diagnosis.

CONCLUSION

In conclusion, drug-associated colitis is the most frequent cause of NIC, in an out-patient cohort. In an appropriate clinical, laboratory, and histological context, small lesions such as red spot, hyperemia, and erosions could be associated with drug expositions, recent infection, and food allergies. Ulcers of the colon are more frequent with ischemic colitis or drug exposition.

The work described has been carried out in accordance with the Code of Ethics of the World Medical Association (Declaration of Helsinki) for experiments on human beings.

ACKNOWLEDGMENTS

No fundings or grants were used for this research.

REFERENCES

- Volk EE, Shapiro BD, Easley KA and Goldblum JR. The clinical significance of a biopsy-based diagnosis of focal active colitis: A clinicopathologic study of 31 cases. *Mod Pathol*. 1998;11(8):789-794.
- Shetty S, Anjarwalla SM, Gupta J, Foy CJ, Shaw IS, Valori RM, et al. Focal active colitis: A prospective study of clinicopathological correlations in 90 patients. *Histopathology*. 2011;59(5):850-856. <https://doi.org/10.1111/j.1365-2559.2011.04019.x>
- Tanner AR and Raghunath AS. Colonic inflammation and nonsteroidal anti-inflammatory drug administration. An assessment of the frequency of the problem. *Digestion*. 1988;41(2):116-120. <https://doi.org/10.1159/000199740>
- Bernardino ME and Lawson TL. Discrete colonic ulcers associated with oral contraceptives. *Am J Dig Dis*. 1976;21(6):503-506. <https://doi.org/10.1007/BF01072137>
- Cappell MS. Colonic toxicity of administered drugs and chemicals. *Am J Gastroenterol*. 2004;99(6):1175-1190. <https://doi.org/10.1111/j.1572-0241.2004.30192.x>
- Geramizadeh B, Taghavi A and Banan B. Clinical, endoscopic and pathologic spectrum of non-steroidal anti-inflammatory drug-induced colitis. *Indian J Gastroenterol*. 2009;28(4):150-153. <https://doi.org/10.1007/s12664-009-0053-9>
- Villanacci V, Casella G and Bassotti G. The spectrum of drug-related colitides: Important entities, though frequently overlooked. *Dig Liv Dis*. 2011;43(7):523-528. <https://doi.org/10.1016/j.dld.2010.12.016>
- Mahadea DS, Śledzińska E, Dobrowolska A and Kreła-Kaźmierczak I. A double-edged sword of immunotherapy: New category of colitis mimicking inflammatory bowel disease. *Pol Arch Intern Med*. 2020;130(11):1003-1004. <https://doi.org/10.20452/pamw.15558>
- Liapis G, Boletis J, Skalioti C, Bamias G, Tsimaratou K, Patsouris E, et al. Histological spectrum of mycophenolate mofetil-related colitis: Association with apoptosis. *Histopathology*. 2013;63(5):649-658. <https://doi.org/10.1111/his.12222>
- Ryan ME and Morrissey JF. Typhlitis complicating methimazole-induced agranulocytosis. *Gastrointest Endosc*. 1983;29(4):299-302. [https://doi.org/10.1016/S0016-5107\(83\)72639-8](https://doi.org/10.1016/S0016-5107(83)72639-8)
- Remine SG and McIlrath DC. Bowel perforation in steroid-treated patients. *Ann Surg*. 1980;192(4):581-586. <https://doi.org/10.1097/0000658-198010000-00016>
- Young GP, Ward PB, Bayley DG, Gordon D, Higgins G, Trapani JA, et al. Antibiotic-associated colitis due to *Clostridium difficile*: Double-blind comparison of vancomycin with bacitracin. *Gastroenterology*. 1985;89(5):1038-1045. [https://doi.org/10.1016/0016-5085\(85\)90206-9](https://doi.org/10.1016/0016-5085(85)90206-9)
- Martin DM, Goldman JA, Gilliam J and Nasrallah SM. Gold-induced eosinophilic enterocolitis: Response to oral cromolyn sodium. *Gastroenterology*. 1981;80(6):1567-1570.
- White CA and Traube J. Ulcerating enteritis associated with flucytosine therapy. *Gastroenterology*. 1982;83(5):1127-1129.
- Graham CF, Gallagher K and Jones JK. Acute colitis with methyl dopa. *N Engl J Med*. 1981;304(17):1044-1045.
- Doulberis M, Panagopoulos P, Scherz S, Dellaporta E and Kouklakis G. Update on ischemic colitis: From etiopathology to treatment including patients of intensive care unit. *Scand J Gastroenterol*. 2016;51(8):893-902. <https://doi.org/10.3109/00365521.2016.1162325>
- Brandt LJ, Feuerstadt P, Longstreth GF and Boley SJ. ACG clinical guideline: Epidemiology, risk factors, patterns of presentation, diagnosis, and management of colon ischemia (CI). *Am J Gastroenterol*. 2015;110(1):18-44. <https://doi.org/10.1038/ajg.2014.395>
- Khor TS, Lauwers GY, Odze RD and Srivastava A. "Massforming" variant of ischemic colitis is a distinct entity with predilection for the proximal colon. *Am J Surg Pathol*. 2015;39(9):1275-1281. <https://doi.org/10.1097/PAS.0000000000000438>
- Uberti G, Goldblum JR and Allende DS. Ischemic enterocolitis and its differential diagnosis. *Semin Diagn Pathol*. 2014;31(2):152-164. <https://doi.org/10.1053/j.semdp.2014.02.001>
- Villanacci V, Reggiani-Bonetti L, Leoncini G, Parente P, Cadei M, Albarello L, et al. Histopathology of Non-IBD Colitis. A practical approach from the Italian Group for the study of the gastrointestinal tract (GIPAD). *Pathologica*. 2021;113(1):54-65. <https://doi.org/10.32074/1591-951X-234>
- Mantzaris GJ. Endoscopic diagnosis of infectious colitis. *Ann Gastroenterol*. 2007;20:71-74.
- Shah RJ, Fenoglio-Preiser C, Bleau BL and Giannella RA. Usefulness of colonoscopy with biopsy in the evaluation of patients with chronic diarrhea. *Am J Gastroenterol*. 2001;96(4):1091-1095. <https://doi.org/10.1111/j.1572-0241.2001.03745.x>
- Shieh AC, Guler E, Tirumani SH, Dumot J and Ramaiya NH. Clinical, imaging, endoscopic findings, and management of patients with CMV colitis: A single-institute experience. *Emerg Radiol*. 2020;27(3):277-284. <https://doi.org/10.1007/s10140-020-01750-z>

24. Li N, Wang HH, Zhao XJ and Sheng JQ. Amebic colitis: Colonoscopic appearance. *Endoscopy*. 2015;47 Suppl UCTN: E145-E146.
<https://doi.org/10.1055/s-0034-1377208>
25. Freeman HJ. Segmental colitis associated with diverticulosis syndrome. *World J Gastroenterol*. 2016;22(36):8067-8069.
<https://doi.org/10.3748/wjg.v22.i36.8067>
26. Schembri J, Bonello J, Christodoulou DK, Katsanos KH and Ellul P. Segmental colitis associated with diverticulosis: Is it the coexistence of colonic diverticulosis and inflammatory bowel disease? *Ann Gastroenterol*. 2017;30(3):257-261.
<https://doi.org/10.20524/aog.2017.0126>
27. Okpara N, Aswad B and Baffy G. Eosinophilic colitis. *World J Gastroenterol*. 2009;15(24):2975-2979.
<https://doi.org/10.3748/wjg.15.2975>
28. Yan BM and Shaffer EA. Primary eosinophilic disorders of the gastrointestinal tract. *Gut*. 2009;58(5):721-732.
<https://doi.org/10.1136/gut.2008.165894>
29. Park HS, Han DS, Ro YO, Eun CS and Yoo KS. Does lymphocytic colitis always present with normal endoscopic findings? *Gut Liver*. 2015;9(2):197-201.
<https://doi.org/10.5009/gnl13373>
30. Wickbom A, Lindqvist M, Bohr J, Ung KA, Bergman J, Eriksson S, et al. Colonic mucosal tears in collagenous colitis. *Scand J Gastroenterol*. 2006;41:726-729.
<https://doi.org/10.1080/00365520500453473>
31. Brechmann T, Günther K, Neid M, Tannapfel A and Schmiegel W. Phenotype of histologically suspected drug-induced colitis; results of a comparative, retrospective cohort study. *Scand J Gastroenterol*. 2019;54(7):855-862.
<https://doi.org/10.1080/00365521.2019.1630674>
32. Püspök A, Kiener HP and Oberhuber G. Clinical, endoscopic, and histologic spectrum of nonsteroidal anti-inflammatory drug-induced lesions in the colon. *Dis Colon Rectum*. 2000;43(5):685-691.
<https://doi.org/10.1007/BF02235589>
33. Kurahara K, Matsumoto T, Iida M, Honda K, Yao T and Fujishima M. Clinical and endoscopic features of nonsteroidal anti-inflammatory drug-induced colonic ulcerations. *Am J Gastroenterol*. 2001;96(2):473-480.
<https://doi.org/10.1111/j.1572-0241.2001.03530.x>
34. Stolte M, Karimi D, Vieth M, Volkholz H, Dirschmid K, Rappel S, et al. Strictures, diaphragms, erosions or ulcerations of ischemic type in the colon should always prompt consideration of nonsteroidal anti-inflammatory drug-induced lesions. *World J Gastroenterol*. 2005;11(37):5828-5833.
<https://doi.org/10.3748/wjg.v11.i37.5828>
35. Geukes Foppen MH, Rozeman EA, van Wilpe S, Postma C, Snaebjornsson P, van Thienen JV, et al. Immune checkpoint inhibition-related colitis: Symptoms, endoscopic features, histology and response to management. *ESMO Open*. 2018;3(1):e000278.
<https://doi.org/10.1136/esmoopen-2017-000278>
36. Rubio CA and Nydahl S. "Nonspecific" erosions and ulcers of the colonic mucosa. *Dig Dis Sci*. 1994;39:821-826.
<https://doi.org/10.1007/BF02087429>
37. Shah NC, Ostrov AH, Cavallero JB and Rodgers JB. Benign ulcers of the colon. *Gastrointest Endosc*. 1986;32(2):102-104.
[https://doi.org/10.1016/s0016-5107\(86\)71767-7](https://doi.org/10.1016/s0016-5107(86)71767-7)
38. Nielsen OH, Vainer B and Rask-Madsen J. Non-IBD and noninfectious colitis. *Nat Clin Pract Gastroenterol Hepatol*. 2008;5(1):28-39.
<https://doi.org/10.1038/ncpgasthep1005>
39. Macchia D, Melioli G, Pravettoni V, Nucera E, Piantanida M, Caminati M, et al. Food Allergy Study Group (ATI) of the Italian Society of Allergy, Asthma and Clinical Immunology (SIAAIC). Guidelines for the use and interpretation of diagnostic methods in adult food allergy. *Clin Mol Allergy*. 2015;13:27.
<https://doi.org/10.1186/s12948-015-0033-9>
40. Gastañaduy PA, Hall AJ, Curns AT, Parashar UD and Lopman BA. Burden of norovirus gastroenteritis in the ambulatory setting--United States, 2001-2009. *J Infect Dis*. 2013;207(7):1058-1065.
<https://doi.org/10.1093/infdis/jis942>
41. Tursi A. Segmental colitis associated with diverticulosis: Complication of diverticular disease or autonomous entity? *Dig Dis Sci*. 2011;56(1):27-34.
<https://doi.org/10.1007/s10620-010-1230-5>
42. Imperiali G, Meucci G, Alvisi C, Fasoli R, Ferrara A, Girelli CM, et al. Segmental colitis associated with diverticula: A prospective study. *Am J Gastroenterol*. 2000;95(4):1014-1016.
<https://doi.org/10.1111/j.1572-0241.2000.01943.x>
43. Tursi A, Elisei W, Brandimarte G, Giorgetti GM, Lecca PG, Di Cesare L, et al. The endoscopic spectrum of segmental colitis associated with diverticulosis. *Colorectal Dis*. 2010;12(5):464-470.
<https://doi.org/10.1111/j.1463-1318.2009.01969.x>
44. Koulaouzidis A and Saeed AA. Distinct colonoscopy findings of microscopic colitis: Not so microscopic after all? *World J Gastroenterol*. 2011;17(37):4157-4165.
<https://doi.org/10.3748/wjg.v17.i37.4157>
45. Maroy A. A case of drug-induced lymphocytic colitis with a peculiar colonoscopic mucosal feature. *ACEN*. 2001;31:301-302.
<https://doi.org/10.1007/BF03020900>

Authors Contribution:

FP- Conceptualization, data curation, formal analysis, investigation, methodology, project administration, writing-original draft, and writing-review and editing.
LRB and RC- Supervision and validation.

Work attributed to:

Flavia Pigò.

Orcid ID:

Flavia Pigò - <https://orcid.org/0000-0002-0917-0802>
Reggiani Bonetti Luca - <https://orcid.org/0000-0001-9132-4374>

Source of Support: Nil, **Conflicts of Interest:** None declared.