

# Radiological evaluation of soft-tissue swellings



Rachna Chaurasia<sup>1</sup>, Mohd. Abubakar<sup>2</sup>, Vishal Gupta<sup>3</sup>

<sup>1</sup>Professor, <sup>2,3</sup>Junior Resident, Department of Radio-Diagnosis, Maharani Laxmi Bai Medical College, Jhansi, Uttar Pradesh, India

Submission: 23-05-2023

Revision: 27-09-2023

Publication: 01-11-2023

## ABSTRACT

**Background:** Soft-tissue swellings (STSs) are commonly encountered by a radiologist in routine practice, either as the principal indication for diagnostic examination or as an incidental finding during an examination performed for other indications. **Aims and Objectives:** The aim of the study was to design a basic approach for the evaluation of STS with the help of available imaging modalities (ultrasound [USG], computed tomography [CT], and magnetic resonance imaging [MRI]) and analyzes its imaging characteristics so as to arrive at its final diagnosis. **Materials and Methods:** This prospective study (CTRI/2023/01/048933) was conducted in the Department of Radio-diagnosis, MLBMC, Jhansi, Uttar Pradesh, with 100 cases of STS were primarily evaluated by high-resolution grayscale USG, out of 100 cases, 72 diagnosed on USG and rest equivocal cases were secondarily evaluated with MRI, out of which 25 diagnosed and three cases needed CT evaluation. Three cases were evaluated with MRI + CT scan and finally diagnosed. Diagnosed cases followed by histopathology and surgery. **Results:** In our study, we found that USG is helpful in benign and superficial STS, as 72/100 cases diagnosed with the help of USG. In equivocal, deeply located, and malignant cases, MRI is more helpful in making a final diagnosis. In our study out of 28 cases, 25 diagnosed on MRI. CT scan used as accessory modality in the diagnosis of STS. **Conclusion:** USG remains the first-line imaging modality for the assessment of STS. MRI is an excellent modality in equivocal or suspicious lesion for characterisation of nature and extension. CT can be used for the detection of calcification and bone involvement.

**Key words:** Non-juxta-articular; Soft-tissue swellings; High-resolution ultrasonography

## INTRODUCTION

Soft-tissue lesions are commonly encountered by a radiologist in routine practice, either as the principal indication for diagnostic examination or as an incidental finding during an examination performed for other indications. These lesions range from benign to malignant soft-tissue swellings (STS).<sup>1</sup> The goal of imaging in patients with a STS is to avoid excessive evaluation in a large number of patients with benign pathology while avoiding delayed diagnosis in the small number of patients with malignancy. A proper imaging workup is thus very important to decide on a management plan. Different imaging modalities have been used to assess STS, including various techniques of ultrasonography (US) such as grayscale, color Doppler, computed tomography (CT), and magnetic resonance imaging (MRI). High-resolution

grayscale ultrasound (HRUSG) and Doppler are being used as the first line of investigation to evaluate STS. If the diagnosis is not confirmed on ultrasound (USG), additional imaging such as MRI or biopsy or surgical intervention should be recommended, though CT used as an accessory tool to rule out bony involvement.

### Aims and objectives

The aims of this study were as follows:

1. To design a radiological approach to STS (excluding juxta-articular swellings)
2. To classify the various STS
3. To evaluate the STS using various available imaging modalities and to analyze its image characteristics so as to arrive at the final diagnosis which helps the clinicians for further management of the lesion.

### Access this article online

#### Website:

<http://nepjol.info/index.php/AJMS>

DOI: 10.3126/ajms.v14i11.55091

E-ISSN: 2091-0576

P-ISSN: 2467-9100

Copyright (c) 2023 Asian Journal of Medical Sciences



This work is licensed under a Creative Commons Attribution-NonCommercial 4.0 International License.

### Address for Correspondence:

Mohd. Abubakar, Junior Resident, Department of Radio-diagnosis, Maharani Laxmi Bai Medical College, Jhansi - 284 128, Uttar Pradesh, India. **Mobile:** +91-9336292212. **E-mail:** mas05241@gmail.com

## MATERIALS AND METHODS

### Source of data

The study was conducted for 18 months (March 2021–September 2022) in the Department of Radiodiagnosis, M.L.B. Medical College, Jhansi in collaboration with the Department of Surgery and other referral departments of M.L.B. Medical College, Jhansi.

A minimum number of 100 cases are intended to be taken up; however, it may be extended depending on the availability of cases within the study period.

CTRI No: CTRI/2023/01/048933

### Inclusion criteria

- Patients with STS of 10–70 years age groups were included in the study.

### Exclusion criteria

The following criteria were excluded from the study:

- Patients with swellings related to the skeletal system (Bones, tendons, ligaments, and joints system) and juxta-articular in location
- Patients with STS who presented with associated emergency conditions and severe debilitating conditions
- Pregnant, lactating women (as cannot be evaluated with CT)
- Patient having a history of claustrophobia, metallic implants insertion, cardiac pacemakers, and metallic foreign body *in situ* (as not evaluated with MRI)
- Patients who refuse to give consent.

### Equipment's

These studies will be concluded with the following equipment's:

1. Medison sono Ace-X8 USG machine, Vivid –T8, and Hitachi Aloka SSDF-31
2. PHILIPS- MX-16 slice CT machine
3. Hitachi – AIRIS ELITE 0.3 TESLA MRI machine with kodak dry view 6800 laser image printer.

### Method

The total number of patients included in our study was 100 satisfying our inclusion criteria. They primarily evaluated by HRUSG, out of 100 cases, 72 diagnosed on USG and the rest equivocal cases were secondarily evaluated with MRI, out of which 25 diagnosed and three cases needed CT evaluation. Three cases were evaluated with MRI+CT scan and finally diagnosed. Diagnosed cases followed by histopathology and surgery.

## RESULTS

Our study was conducted on patients referred to the Department of Radiodiagnosis, Maharani Laxmi Bai

Medical College, Jhansi, Uttar Pradesh. The patients were between 10- and 70-year age group. A total of 100 cases with non-juxta-articular STS were included in our study. All these patients presented with various signs and symptoms of STS. All patients were subjected to thorough clinical examination before being subjected to radiological evaluation. The goal is to classify according to its origin and its nature. In all these studies, benign tumors predominated over malignant tumors. High-resolution grayscale USG and Doppler are being used as the first line of investigation to evaluate these superficial STS. The benefits of USG include its applicability, availability, relatively low cost, higher accuracy in differentiating tissue layers, good spatial, and contrast resolution as well as real-time imaging capability.

In our study, all 100 patients were first evaluated with USG, out of 100 patients, 28 required USG+MRI, and three patients required USG+MRI+CT scan for diagnosis.

Lipoma is the most common finding followed by epidermal inclusion cyst and the least common dermatofibroma and tibialis anterior hernia.

Out of 100 patients, 62 patients managed surgically, 21 medically, and 17 puts on follow-up. Out of 100 patients, 92 followed histologically, and 84 correctly diagnosed.

## DISCUSSION

### Age and gender

In our study, out of 100 cases, 38% below 20 years, 35% between 21 and 40 years, 20% between 41 and 60 years, and 7% are >60 years. Mean age 32.3, Hiremath et al.,<sup>2</sup> found out in this prospective study, 100 subjects were enrolled. Subjects of varied aged groups were included in this study ranging from 10 years to 72 years of age with a mean of 39.9 years. In our study out of 100 cases, there were 55 males (55%) and 45 (45%) females in our study. There are more males included than females in our study.

Hiremath et al.,<sup>2</sup> found out in this prospective study, 100 subjects were enrolled, out of which 59 were female and 41 were male.

### Anatomical region

The majority of the cases in our study were found in the head and neck (35%) followed by chest and abdomen (34%) and extremities (31%). The study by Lazim and Al-Irhayim<sup>3</sup> and Fang et al.,<sup>4</sup> states that the most common site was the extremities for the malignant soft-tissue tumors mainly lower extremities followed by the trunk and abdomen, whereas in the study by Mandong et al.,<sup>5</sup> extremities followed by head and neck.

## Modalities

In our study, all 100 cases first evaluated with USG, 28 cases on USG+MRI, and the three cases were evaluated on USG+CT+MRI (Table 1). Jacobson<sup>6</sup> concluded that US is an excellent first-line imaging method in the evaluation of a superficial soft-tissue mass. Many diagnoses can be made with confidence, as summarized earlier in this article. In most other instances, a combination of US findings and clinical history is adequate to guide appropriate management. Follow-up or alternative imaging and/or possible biopsy will be required for atypical, non-specific, or suspicious US findings or a conflicting clinical history.

Nagano et al.,<sup>7</sup> in 2015, in a prospective study of 189 biopsy-proven soft-tissue tumors proposed the US-based sarcoma screening (USS) score and found that USS scores combined with characteristic clinical features and MRI features helped in differentiating benign from malignant soft-tissue tumors. In their study, the malignant tumors had significantly higher USS scores than the benign tumors.

## Radiological diagnosis

### Lipoma (Figure 1)

In our study, 33 (33%) cases out of 100 cases were lipoma which contribute a maximum number of cases. Studies done by Wagner et al.,<sup>8</sup> and Hung et al.,<sup>9</sup> where all lipomas were in subcutaneous plane, except the study done by Inampudi et al.,<sup>10</sup> which included deeper masses. Typically, there is no detectable internal vascularity on Doppler USG images, uncommonly minimal blood flow identified within a septum. According to Wagner et al.,<sup>11</sup> lipomas (including angiolipomas) should have no more than a minimal Doppler signal. A lesion with more than minimal color Doppler signal should not be diagnosed as a lipoma.

### Epidermal inclusion cyst (Figure 2)

In our study, 19 (19%) cases out of 100 cases were epidermal inclusion cysts, all are located in subcutaneous plain superficial lesion. Hung et al.,<sup>12</sup> Hung et al.,<sup>9</sup> and Huang et al.,<sup>13</sup> also show that an epidermal inclusion cyst is a superficial lesion that involves the hair-bearing areas of the body, most commonly the head or neck, trunk, and scrotum, and less commonly involves the extremities.

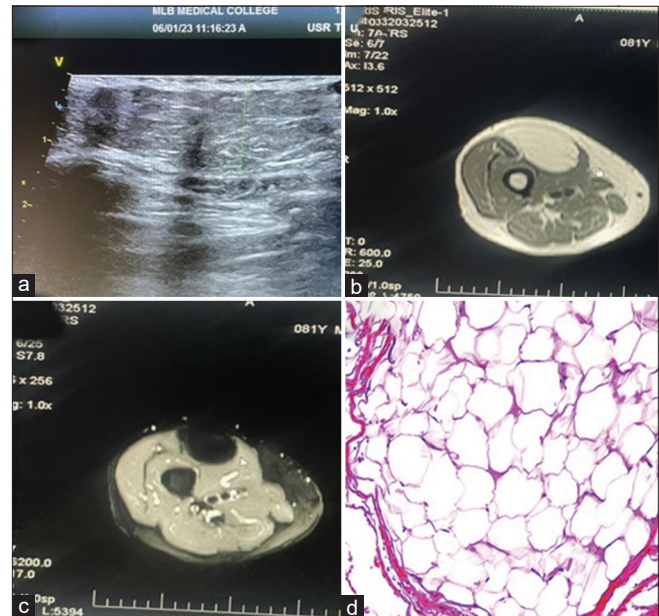
### Vascular causes

In our study, 13% were hemangiomas, 7% were venous malformations and 3% were AV malformations. Infantile hemangioma is the most common vascular tumor of the newborn and the most common childhood tumor seen to occur in infants. The majority of the lesions in our study were found in the head and neck. They often associated with blueish discoloration, which was similar to the study. They may show phlebolith. Dubois et al.,<sup>14</sup> in their study on USG of 116 vascular anomalies,

**Table 1: Distribution of cases according to modalities**

Modalities	Number of patients
USG	100
USG+MRI	28
USG+CT scan+MRI	3

MRI: Magnetic resonance imaging, CT: Computed tomography



**Figure 1:** Lipoma (a): HRUSG image shows a well-defined smooth margined oval-shaped hyperechoic lesion at the subcutaneous plain, showing posterior acoustic enhancement without any vascularity. (b): T1 axial image shows a well-defined hyperintense lesion. (c): STIR axial image shows suppression of lesion. (d): H and E stained section showing the sheet of mature adipocytes separated by fibrous septa)

concluded that high vessel density and high peak arterial Doppler shifts can be used to differentiate hemangiomas from other lesions.

### Lymphatic malformation

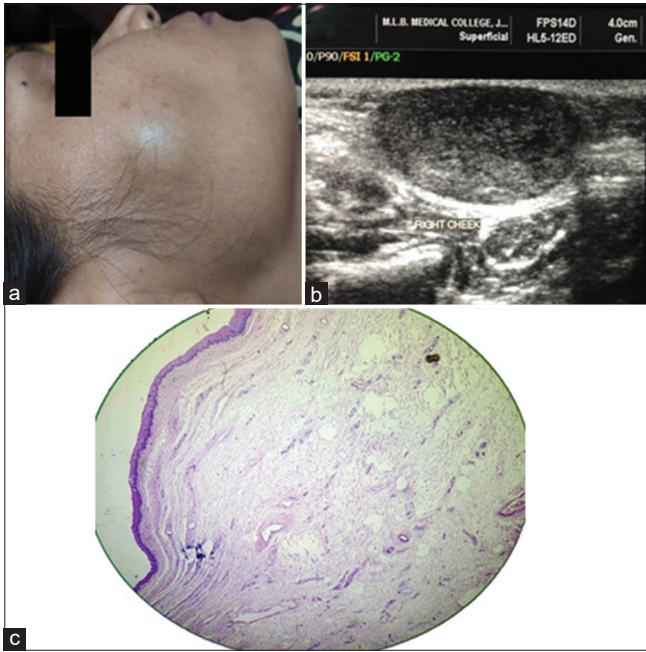
In our study, four cases out of 100 cases were lymphatic malformation. The age of onset of the lesion was since birth in 03 cases (75%) and early childhood in the remaining 01 cases (25%). Fordham et al.,<sup>15</sup> in 1999, and Brown and Azizkhan,<sup>16</sup> in 1998, found out that most lymphatic malformations present in early childhood, with 65% at birth and 90% by the age of 2. The most common location is neck (75%) followed by axilla (25%).

### Abscess

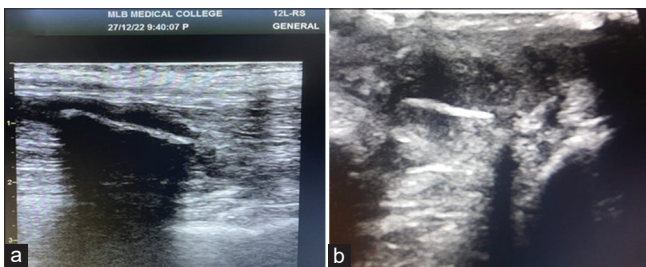
In our study, seven cases out of 100 cases were all of them diagnosed on USG and correctly correlated with surgical and histopathological correlation.

A study done by Squire et al.,<sup>17</sup> in 2005 where a total of 107 cases with clinical signs of soft-tissue infections





**Figure 2:** Epidermal inclusion cyst (a): Right cheek swelling. (b): HRUSG image shows well-circumscribed oval-shaped, predominantly hypoechoic mass at the subcutaneous plane showing posterior acoustic enhancement without vascularity. (c): H and E stained section image shows cyst wall lined by stratified squamous epithelium with the absence of skin appendages)



**Figure 3:** Foreign bodies (a): HRUSG image shows an echogenic linear structure with posterior acoustic shadowing with surrounding hypochoic collection. (b): HRUSG image shows echogenic linear structure without posterior acoustic shadowing with surrounding hypochoic collection)

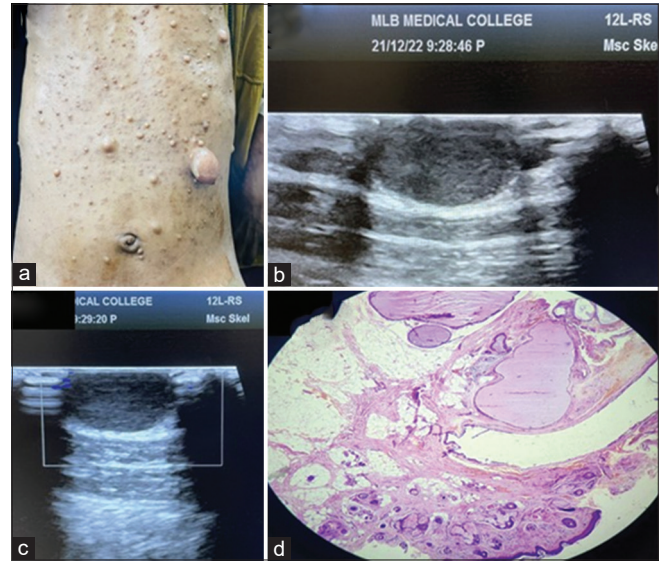
were evaluated, stated that USG improves accuracy in the detection of superficial abscesses.

**Isolated lymph nodes**

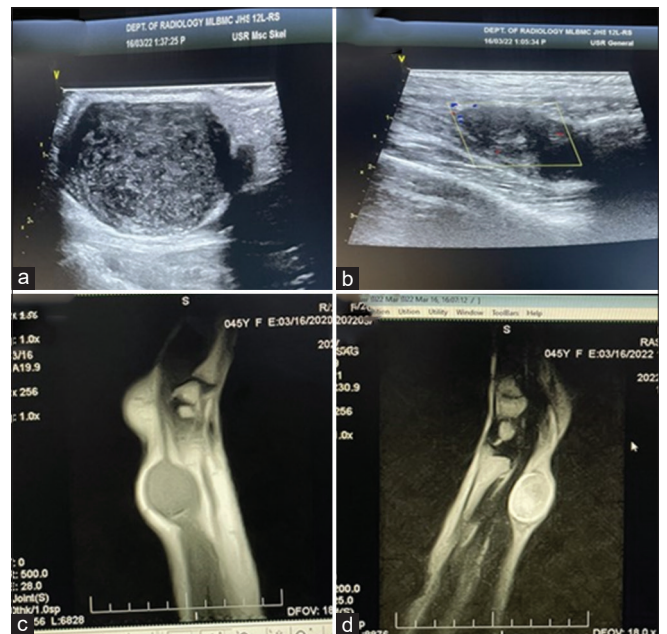
In our study, three cases out of 100 cases were all of them diagnosed with USG. Hajek et al.,<sup>18</sup> studied and found that USG proved highly effective for the detection, localization, and delineation of enlarged lymph nodes of the neck. Infiltration of adjacent structures, specifically the common, internal, and external carotid arteries, and the neck muscles was reliably demonstrated.

**Foreign body (Figure 3)**

In our study, three cases out of 100 cases were foreign bodies. Foreign body granuloma is granulation tissue



**Figure 4:** Neurofibroma (a): Multiple swellings in abdomen. (b): HRUSG image shows a well-defined hypoechoic lesion in the subcutaneous plane and showing posterior acoustic enhancement. (c): Color Doppler image shows no vascularity. (d): H and E stained section shows proliferation of hypocellular spindle cells with wavy serpentine nuclei



**Figure 5:** Malignant peripheral nerves sheath tumors (a): HRUSG image shows a well-defined heterogenous hypoechoic lesion in the subcutaneous plane along radial nerve. (b): Color Doppler image shows internal vascularity. (c): T1 coronal image shows hypointense lesion. (d): T2 sagittal image shows hyperintense lesion)

formation in response to penetrating injury. All are diagnosed on USG and confirmed by surgical correlation. In a study done by Shields<sup>19</sup> in 1990, the localization of foreign body procedure was performed in 19 patients with 21 foreign bodies. They concluded that the USG is a very useful tool to localize soft-tissue foreign bodies and thereby guide removal.

**Neurofibroma (Figure 4)**

In our study, two cases out of 100 cases were neurofibroma. Wise et al.,<sup>20</sup> in 2005 showed in their study that plexiform neurofibromas (PN) are most common in the head and neck location, followed by spine, extremities, mediastinum, and abdomen.

**Malignant peripheral nerves sheath tumors (Figure 5)**

In our study, two cases out of 100 cases were MPNST, two were malignant nerve sheath tumors. Malignant lesions were MPNST which was diagnosed with the help of USG and MRI and confirmed by biopsy. Reynolds et al.,<sup>21</sup> in 2004 had retrospectively reviewed images of 12 biopsy-proven peripheral nerve sheath tumors. The tumors in their series were predominantly hypoechoic.

**Scar endometriosis (Figure 6)**

In our study, two cases out of 100 cases were scar endometriosis, which diagnosed with the help of USG and MRI and confirmed with biopsy report. Wolf and Kopecky<sup>22</sup> concluded that endometriosis of the abdominal wall is rare and usually arises in a surgical incision. MR has been used to evaluate endometriosis of the ovaries. A case of endometriosis in a cesarean section scar is presented and evaluated with CT and MRI.

**Dermatofibroma**

In our study, one case out of 100 cases was dermatofibroma, which diagnosed with the help of USG, MRI, CT, and

histopathology. Han et al.,<sup>23</sup> concluded that dermatofibroma, also known as fibrous histiocytoma, is one of the most common cutaneous soft-tissue lesions, accounting for approximately 3% of skin lesion specimens received by dermatopathology laboratories.

**Tibialis anterior hernia**

In our study, one case out of 100 cases was tibialis anterior hernia, was diagnosed on USG, and confirms after surgical follow-up. Zhou et al.,<sup>24</sup> concluded that a muscle hernia may also protrude through a fascial defect into the subcutaneous tissues in continuity with the underlying muscle, commonly the tibialis anterior muscle.

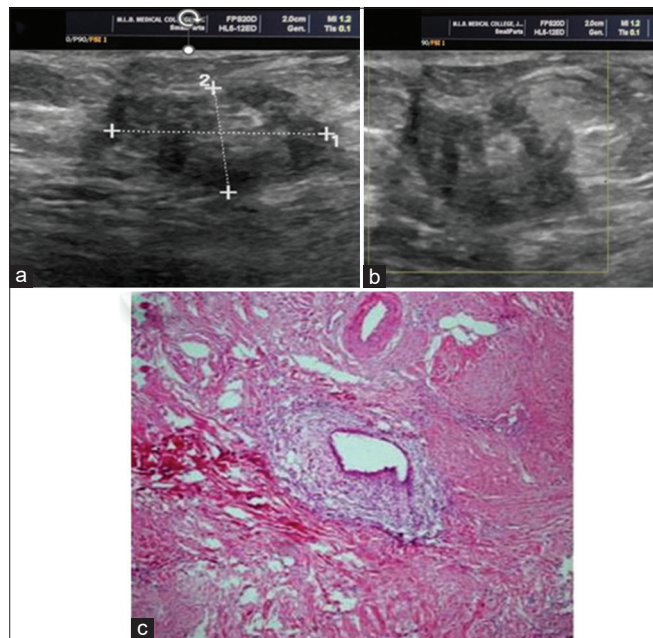
**Plane**

In our study, 100 out of 77 cases were superficial, 20 cases were deep and three cases were superficial+deep which are in concordance with the studies done by Wagner et al.,<sup>8</sup> and Hung et al.,<sup>9</sup> where all lipomas were in the subcutaneous plane, except the study done by Inampudi et al.,<sup>10</sup> which included deeper masses.

Congenital versus acquired: In our study, the majority of cases are acquired (66%) and 34% of cases were congenital. Darrow et al.,<sup>25</sup> studied and found that infantile hemangioma is the most common tumor in childhood (Table 2).

**Management**

In our study, the majority of 62 cases out of 100 managed surgically, 21 cases out of 100 managed medically, and 17 cases followed up. Out of 100 cases, 92 cases have histopathology reports of which 84 cases diagnosed correctly using various basic imaging modalities (Table 3). Padia et al.,<sup>26</sup> studied and found that medical therapy for vascular anomalies has become more prominent as a treatment modality.



**Figure 6:** Scar endometriosis (a) HRUSG image shows an ill-defined predominantly hypoechoic lesion in the right rectus abdominus muscle. (b): Color Doppler images show no vascularity. (c): H and E stained section shows endometrial gland lined by stroma surrounded by dense fibrocollagenous tissue

**Table 2: Distribution of cases according to radiological diagnosis**

Radiological diagnosis	Number of patients (%)
Lipoma	33 (33)
Epidermal inclusion cyst	19 (19)
Haemangioma	13 (13)
AV malformation	3 (3)
Venous malformation	7 (7)
Lymphatic malformation	4 (4)
Abscesses	7 (7)
Isolated lymph node	3 (3)
Foreign body	3 (3)
MPNST	2 (2)
Neurofibroma	2 (2)
Scar endometriosis	2 (2)
Dermatofibroma	1 (1)
Tibialis anterior hernia	1 (1)

MPNST: Malignant peripheral nerve sheath tumor, AV: Arteriovenous



**Table 3: Distribution of cases according to management and histopathological correlation**

Type of management	Number of cases	Available histopathological report	Correct radiological diagnosis
Surgical	62	59	53
Medical	21	18	17
Follow-up	17	15	14

### Limitations of the study

This was a single-centered study.

### CONCLUSION

- Role of radiology in the management of STS is to diagnose it early with a less expensive radiation-free modality so as to avoid delayed diagnosis and providing early correct management.
- USG remains the first-line imaging modality for the assessment of STS. It is diagnostic in benign, cystic, and superficial lesions.
- MRI is overall the best imaging modality in equivocal or suspicious lesion. It has surpassed its role in malignant, vascular, and deep lesions.
- CT scan is an accessory tool used to see mineralization, calcification, and bone involvement.

### ACKNOWLEDGMENT

The authors would like to thank the Department of Radio-diagnosis, Maharani Laxmi Bai Medical College, Jhansi, Uttar Pradesh.

### REFERENCES

1. Wu JS and Hochman MG. Soft-tissue tumors and tumorlike lesions: A systematic imaging approach. *Radiology*. 2009;253(2):297-316.  
<https://doi.org/10.1148/radiol.2532081199>
2. Hiremath R, Gowda G, Reddy HT, Ibrahim J, Shah RS and Chodiboina H. Superficial soft tissue swellings: Accuracy of ultrasonography in diagnosis with pathological correlation. *J Clin Diagn Res*. 2018;12(1):TC01-TC05.  
<https://doi.org/10.7860/JCDR/2018/26028.11081>
3. Lazim AF and Al-Irhayim BA. Soft tissue sarcomas in Mosul: A pathologic evaluation. *Ann Coll Med*. 2008;34(2):152-160.  
<https://doi.org/10.33899/mmed.2008.32311>
4. Fang ZW, Chen J, Teng S, Chen Y and Xue RF. Analysis of soft tissue sarcomas in 1118 cases. *Chin Med J (Engl)*. 2009;122(1):51-53.  
<https://pubmed.ncbi.nlm.nih.gov/19187617/>
5. Mandong BM, Kidmas AT, Manasseh AN, Echejoh GO, Tanko MN and Madaki AJ. Epidemiology of soft tissue sarcomas in Jos, North Central Nigeria. *Niger J Med*. 2007;16(3):246-249.  
<https://doi.org/10.4314/njm.v19i4.61975>
6. Jacobson JA, Middleton WD, Allison SJ, Dahiya N, Lee KS, Levine BD, et al. Ultrasonography of superficial soft-tissue masses: Society of radiologists in ultrasound consensus conference statement. *Radiology*. 2022;304:18-30.  
<https://doi.org/10.1148/radiol.211101>
7. Nagano S, Yahiro Y, Yokouchi M, Setoguchi T, Ishidou Y, Sasaki H, et al. Doppler ultrasound for diagnosis of soft tissue sarcoma: Efficacy of ultrasound-based screening score. *Radiol Oncol*. 2015;49(2):135-140.  
<https://doi.org/10.1515/raon-2015-0011>
8. Wagner JM, Lee KS, Rosas H and Kliewer MA. Accuracy of sonographic diagnosis of superficial masses. *J Ultrasound Med*. 2013;32(8):1443-1450.  
<https://doi.org/10.7863/ultra.32.8.1443>
9. Hung EH, Griffith JF, Ng AW, Lee RK, Lau DT and Leung JC. Ultrasound of musculoskeletal soft-tissue tumors superficial to the investing fascia. *AJR Am J Roentgenol*. 2014;202(6):W532-W540.  
<https://doi.org/10.2214/ajr.13.11457>
10. Inampudi P, Jacobson JA, Fessell DP, Carlos RC, Patel SV, Delaney-Sathy LO, et al. Soft-tissue lipomas: Accuracy of sonography in diagnosis with pathologic correlation. *Radiology*. 2004;233(3):763-767.  
<https://doi.org/10.1148/radiol.2333031410>
11. Wagner JM, Rebik K and Spicer PJ. Ultrasound of soft tissue masses and fluid collections. *Radiol Clin North Am*. 2019;57(3):657-669.  
<https://doi.org/10.1016/j.rcl.2019.01.013>
12. Hung EH, Griffith JF, Yip SW, Ivory M, Lee JC, Ng AW, et al. Accuracy of ultrasound in the characterization of superficial soft tissue tumors: A prospective study. *Skeletal Radiol*. 2020;49(6):883-892.  
<https://doi.org/10.1007/s00256-019-03365-z>
13. Huang CC, Ko SF, Huang HY, Ng SH, Lee TY, Lee YW, et al. Epidermal cysts in the superficial soft tissue: Sonographic features with an emphasis on the pseudotestis pattern. *J Ultrasound Med*. 2011;30(1):11-17.  
<https://doi.org/10.7863/jum.2011.30.1.11>
14. Dubois JE, Patriquin HB, Garel L, Powell J, Filiatrault D, David M, et al. Soft-tissue hemangiomas in infants and children: Diagnosis using Doppler sonography. *AJR Am J Roentgenol*. 1998;171(1):247-252.  
<https://doi.org/10.2214/ajr.171.1.9648798>
15. Fordham LA, Chung CJ and Donnelly LF. Imaging of congenital vascular and lymphatic anomalies of the head and neck. *Neuroimaging Clin N Am*. 2000;10(1):117-136, viii.
16. Brown RL and Azizkhan RG. Pediatric head and neck lesions. *Pediatr Clin North Am*. 1998;45(4):889-905.  
[https://doi.org/10.1016/s0031-3955\(05\)70052-3](https://doi.org/10.1016/s0031-3955(05)70052-3)
17. Squire BT, Fox JC and Anderson C. ABSCESS: Applied bedside sonography for convenient evaluation of superficial soft tissue infections. *Acad Emerg Med*. 2005;12(7):601-606.  
<https://doi.org/10.1197/j.aem.2005.01.016>
18. Hajek PC, Salomonowitz E, Turk R, Tscholakoff D, Kumpan W and Czembirek H. Lymph nodes of the neck: Evaluation with US. *Radiology*. 1986;158(3):739-742.  
<https://doi.org/10.1148/radiology.158.3.3511503>
19. Shiels WE 2<sup>nd</sup>, Babcock DS, Wilson JL and Burch RA. Localization and guided removal of soft-tissue foreign bodies with sonography. *AJR Am J Roentgenol*. 1990;155(6):1277-1281.  
<https://doi.org/10.2214/ajr.155.6.2122680>
20. Wise JB, Cryer JE, Belasco JB, Jacobs I and Elden L. Management of head and neck plexiform neurofibromas

- in pediatric patients with neurofibromatosis Type 1. Arch Otolaryngol Head Neck Surg. 2005;131(8):712-718.  
<https://doi.org/10.1001/archotol.131.8.712>
21. Reynolds DL Jr., Jacobson JA, Inampudi P, Jamadar DA, Ebrahim FS and Hayes CW. Sonographic characteristics of peripheral nerve sheath tumors. AJR Am J Roentgenol. 2004;182(3):741-744.  
<https://doi.org/10.2214/ajr.182.3.1820741>
  22. Wolf GC and Kopecky KK. MR imaging of endometriosis arising in cesarean section scar. J Comput Assist Tomogr. 1989;13(1):150-152.  
<https://doi.org/10.1097/00004728-198901000-00038>
  23. Han TY, Chang HS, Lee JH, Lee WM and Son SJ. A clinical and histopathological study of 122 cases of dermatofibroma (benign fibrous histiocytoma). Ann Dermatol. 2011;23(2):185-192.  
<https://doi.org/10.5021/ad.2011.23.2.185>
  24. Zhou X, Zhan W, Chen W, Wu D, Wei K, Wu C, et al. The value of ultrasound in the preoperative diagnosis of muscle herniation: A comparison with magnetic resonance imaging. Eur J Radiol. 2017;94:191-194.  
<https://doi.org/10.1016/j.ejrad.2017.06.026>
  25. Darrow DH, Greene AK, Mancini AJ, Nopper AJ, Section on Dermatology, Section on Otolaryngology-Head and Neck Surgery and Section on Plastic Surgery. Diagnosis and management of infantile hemangioma. Pediatrics. 2015;136(4):e1060-e1104.  
<https://doi.org/10.1542/peds.2015-2485>
  26. Padia R, Bly R, Bull C, Geddis AE and Perkins J. Medical management of vascular anomalies. Curr Treat Options Pediatr. 2018;4(2):221-236.  
<https://doi.org/10.1007/s40746-018-0130-3>

**Authors' Contributions:**

**RC, MA, VG-** Definition of intellectual content, literature survey, prepared the first draft of manuscript, implementation of the study protocol, data collection, data analysis, manuscript preparation and submission of article, concept, design, clinical protocol, editing, and manuscript revision, design of the study, statistical analysis and interpretation, review manuscript, literature survey, and coordination.

**Work attributed to:**

Department of Radio-diagnosis, Maharani Laxmi Bai Medical College, Jhansi – 284 128, Uttar Pradesh, India.

**Orcid ID:**

Rachna Chaurasia - <https://orcid.org/0000-0003-4261-6324>

Mohd. Abubakar - <https://orcid.org/0009-0009-7655-4652>

Vishal Gupta - <https://orcid.org/0009-0000-7207-1746>

**Source of Support:** Nil, **Conflicts of Interest:** None declared.