

Use of optical coherence tomography retinal thickness deviation map for hydroxychloroquine retinopathy screening



Jitendra Kumar¹, Surabhi Gupta², Rashmi Kumari³

¹Professor and Head, ²Assistant Professor, ³Junior Resident, Department of Ophthalmology, Maharani Laxmi Bai Medical College, Jhansi, Uttar Pradesh, India

Submission: 18-03-2023

Revision: 28-05-2023

Publication: 01-07-2023

ABSTRACT

Background: Hydroxychloroquine (HCQS) is widely used to treat several rheumatic and skin diseases and can cause damage to the outer retina, known as HCQS retinopathy, and is common among long-term users of the drug with higher daily dose by weight. The goal of screening for retinopathy is to recognize signs of toxicity at an early enough stage to prevent the loss of visual acuity. **Aims and Objectives:** This study aimed to evaluate the diagnostic performance of a commercially available retinal thickness deviation map obtained by spectral-domain (SD) optical coherence tomography (OCT) for screening of HCQS retinopathy. **Materials and Methods:** This study was a prospective comparative study between unaffected (patients who did not develop retina toxicity) and affected (who developed toxicity) of 50 patients of the age group of 14–60 years taking HCQS medication for several dermatological and rheumatologic disorders. The patients who fulfilled the inclusion criteria were screened for HCQS retinal toxicity using SD-OCT, standard automated perimetry, fundus autofluorescence, and comprehensive ophthalmic examinations. **Results:** In this study, in group 2 patients, 60% were having parafoveal, 30% having perifoveal, and 10% having a mixed pattern ($P < 0.001$) of HCQS retinopathy, and the mean deviation and pattern standard deviation increase as the severity of disease increases ($P < 0.005$). **Conclusion:** This study concluded that HCQS is a safer drug and can be used safely in these patients with proper HCQS retinal toxicity monitoring with an SD-OCT-generated retinal thickness deviation map and with regular follow-up to monitor reduced thickness in the parafoveal region.

Key words: Hydroxychloroquine; Retinal toxicity; Spectral-domain optical coherence tomography

Access this article online

Website:

<http://nepjol.info/index.php/AJMS>

DOI: 10.3126/ajms.v14i7.53352

E-ISSN: 2091-0576

P-ISSN: 2467-9100

Copyright (c) 2023 Asian Journal of Medical Sciences



This work is licensed under a Creative Commons Attribution-NonCommercial 4.0 International License.

INTRODUCTION

Hydroxychloroquine (HCQS) is widely used to treat several rheumatic and dermatologic diseases.¹

HCQS can cause damage to the outer retina which is irreversible, known as HCQS retinopathy. The goal of screening for retinopathy is to recognize signs of toxicity at an early enough stage to prevent the loss of visual acuity.²

The new study showed that patients taking HCQ using 4.0–5.0 mg/kg real weight had a markedly lower cumulative risk of toxicity than those using higher levels.³

The apparent safety of HCQS needs vision screening every 6 months in patients who were taking the drug. In HCQS-treated patients whose renal function is normal, routine ophthalmic screening is not indicated if the daily dosage is < 6.5 mg/kg. In patients whose daily dose is > 6.5 mg/kg or who have taken HCQ continuously for > 10 years, annual screening may be appropriate.⁴

Etiopathogenesis

HCQS retinopathy causes the destruction of macular rods and cones with the sparing of the foveal cones. This pattern provides the typical bull's-eye appearance [Figure 2]. HCQS binds to melanin, accumulates in the RPE, and remains

Address for Correspondence:

Dr. Rashmi Kumari, Junior Resident, Department of Ophthalmology, Maharani Laxmi Bai Medical College, Jhansi, Uttar Pradesh, India.

Mobile: +91-8299591821. **E-mail:** meenurashmi18@gmail.com

there for a long period. It is directly toxic to the RPE, causing cellular damage and atrophy.^{5,6}

Sign and symptoms of HCQS retinopathy

On examination, a telltale sign of HCQS toxicity is a bilateral change in the retinal pigment epithelium of the macula that gives the commonly described appearance of a bull's-eye maculopathy.⁶ Spectral-domain (SD) optical coherence tomography (OCT) is designated as a key screening test because it is non-invasive and widely available in ophthalmology clinics to support the identification of retinal structural changes.⁷ Latasiewicz *et al.*, studied the role of OCT, autofluorescence, and Humphrey 10–2 visual fields in the early detection of retinal thinning.⁸

Kim *et al.*, studied that the area of abnormal pixels on the retinal thickness deviation on the OCT map correlated significantly with the mean deviation (MD) ($P < 0.001$) and pattern standard deviation (PSD) ($P < 0.0001$) on the Humphrey 30–2 test in eyes with HCQS retinopathy.⁹

Aims and objectives

This study aimed to evaluate the diagnostic performance of a commercially available retinal thickness deviation map obtained by SD-OCT for screening of HCQS retinopathy.

MATERIALS AND METHODS

This study was a prospective comparative study between unaffected (12 patients who did not develop retinal toxicity) in group 1 and affected (33 patients who developed retinal toxicity) in group 2. Patients of the age group of 14–60 years taking HCQS medication for several dermatological disorders (e.g., systemic lupus erythematosus) and for rheumatologic disorders (e.g., rheumatoid arthritis), who were reported to Ophthalmology, Orthopedics, Medicine, Dermatology, and Venereal disease departments of Maharani Laxmi Bai Medical College, Jhansi, from April 2021 to June 2022 (15-month duration), were included in the study. The study was pre-approved by the Institutional Ethics Committee (IEC) for final permission with Certificate No. 39/IEC/I/2022-2023. After obtaining the permission of the IEC, the study was conducted. Out of 50 patients, 5 were dropped out, and a total of 45 patients were included in the study.

Patients were selected based on the following inclusion criteria

- Age group of 14–60 years
- Current or previous history of HCQS treatment
- Patients on HCQS medication with deranged renal function tests
- Patients with diabetes mellitus and hypertension taking

HCQS with normal vision and fundus on clinical examination

- Patients who have given their informed written consent.

Exclusion criteria

- Age group <14 or more than 60 years of age
- Patients with retinal vascular disease
- Patients with glaucomatous and non-glaucomatous RNFL defects
- Patients with other retinal/optic nerve diseases.

The patients who fulfilled the inclusion criteria were screened for HCQS retinal toxicity using SD-OCT, standard automated perimetry Humphrey field analyzer (HFA), fundus autofluorescence (FAF), and comprehensive ophthalmic examinations (Table 1). All patients who were included in this study underwent a comprehensive ophthalmic examination (visual acuity testing, best-corrected visual acuity, color vision, intraocular pressure, anterior segment evaluation for keratopathy, Amsler grid testing, and fundus examination), SD-OCT, HFA 10–2, and or 30–2. In this study, out of 45 patients, 12 who were unaffected (who did not develop toxicity) were kept in Group 1 and the remaining 33 patients who were affected were kept in Group 2.

Along with ophthalmic examination, various blood investigations such as blood glucose level, serum creatinine, rheumatoid arthritis (RA) factor for RA, and antinuclear antibody for autoimmune disorders like SLE were carried out. Furthermore, data from the evaluation of patients based on the disease severity score (DAS) and EULAR Criteria for RA and SLE were obtained, and patients were categorized into affected (i.e., with toxicity) and unaffected groups. We followed up each patient at a 4-month interval. At follow-up visits with baseline ophthalmic examination, SD-OCT and standard automated perimetry have also been performed using the 30–2 or 10–2 strategy, or both (Carl Zeiss Meditec, Inc) with FAF.

Diagnosis of HCQS retinopathy

The eyes with HCQS retinopathy have been classified based on the pattern and severity of retinopathy. They have been classified into parafoveal (photoreceptor RPE disruption in the area from the fovea) and pericentral (photoreceptor RPE disruption outside the parafovea) patterns, and those with both of these patterns were considered to have a mixed pattern. Based on the severity of HCQS retinopathy, the eyes have been classified into early retinopathy (patchy photoreceptor defects only), moderate retinopathy (photoreceptor defects in a partial [>180] or full ring around the fovea), and severe retinopathy (combined RPE involvement).¹⁰

Statistical analysis

All statistical analyses have been performed using SPSS version 21.0 (SPSS Inc). Means for continuous variables have been then compared using independent-group t-test, and data were compared using the χ^2 and Fisher's exact tests as appropriate. $P < 0.05$ was used to reject the null hypothesis (statistically significant).

RESULTS

In this study, out of 45 patients, 70% of patients who were unaffected were kept in Group 1, and 30% of patients who were affected were kept in Group 2. In this study, we found that 42% of patients of Group 1 and 50% of patients of Group 2 were in the 5th decade of life ($P < 0.01$). In group 1, the male-to-female ratio was 1:1, and in group 2, the male-to-female ratio was 1:2 ($P < 0.03$). Maximum patients in both groups were of low socioeconomic status. In group 1, all patients were having fasting blood sugar (FBS) < 100 mg/dL with normal blood serum creatinine level; while in group 2, all patients were having FBS more than 110 mg/dL and creatinine level above 1.3 mg/dL ($P < 0.05$).

In this study, we also found that in group 2 patients, 60% and 50% of patients were positive for RA factor and ANA, respectively, with moderate DAS score and EULAR criteria more than 6 ($P < 0.05$); while in group 1 patients, RA factor and ANA were positive in 30% and 20% of patients with low DAS score and EULAR criteria < 6 . In this study, in Group 1 patients, all 9 quadrants of the retinal thickness deviation map were green with an average thickness of 259 ± 18 μm and central thickness of 272 ± 24 μm , and in Group 2 patients, 60% of patients showing retinal thinning in the parafoveal area with average thickness 222 ± 20 μm and central thickness 246 ± 24 μm ($P < 0.01$) (Table 2).

In this study, in Group 2 patients, 40% were in early, 50% of patients were in moderate, and 10% of patients were in severe retinopathy, and patients with severe retinopathy developed bull's-eye maculopathy on FAF (Table 3 and Figure 1).

In this study, in Group 2 patients, 60% were having parafoveal, 30% having perifoveal, and 10% having a mixed pattern ($P < 0.001$) of HCQS retinopathy (Table 4).

Table 1: Ophthalmic examination was done in patients of both groups

Parameters of ocular examination	Group 1 (who did not develop toxicity)	Group 2 (who developed toxicity)
Visual acuity of both eyes	6/6	6/12–6/9
Visual acuity with pinhole in both eyes	6/6	6/9–6/6
BCVA	6/6	6/9–6/6
Near vision	N/6	N/6
Color vision	Normal	Normal
Anterior segment	Normal	Normal
Keratopathy	Not present	Not present
Amsler grid testing	Normal	Normal
Schirmer's test	10 s	10 s
Intraocular pressure	14 mmHg	14 mmHg
Fundus examination	Normal	Normal
Media	Clear	Clear
Optic disc appearance	Normal	Normal
Cup: Disc ratio	0.3–0.4	0.3–0.4
Macula	Foveal reflex present	Foveolar reflex dull
Perimetry HFA 10–2	Normal	Central/paracentral scotoma present
SD-OCT	HCQS retinopathy not present	HCQS retinopathy present
Bull's-eye maculopathy	Not present	Present

HCQS: Hydroxychloroquine, SD-OCT: Spectral-domain optical coherence tomography, BCVA: Best-corrected visual acuity

Table 2: Mean value of full thickness in all 9 quadrants of macula through the retinal thickness deviation map in the perifoveal and parafoveal regions, respectively, in both groups generated by SD-OCT

Quadrants	Group 1 thickness of macula (micron meter) in BE mean \pm SD		Group 2 thickness of macula (micron meter) in BE mean \pm SD		P-value
	Perifoveal	Parafoveal	Perifoveal	Parafoveal	
Superior	276 \pm 16	294 \pm 24	234 \pm 15	218 \pm 22	< 0.01
Inferior	258 \pm 18	285 \pm 26	226 \pm 17	217 \pm 25	< 0.01
Nasal	275 \pm 14	291 \pm 23	236 \pm 14	253 \pm 24	< 0.01
Temporal	235 \pm 15	278 \pm 25	200 \pm 16	228 \pm 26	< 0.01

SD: Spectral domain, OCT: Optical coherence tomography

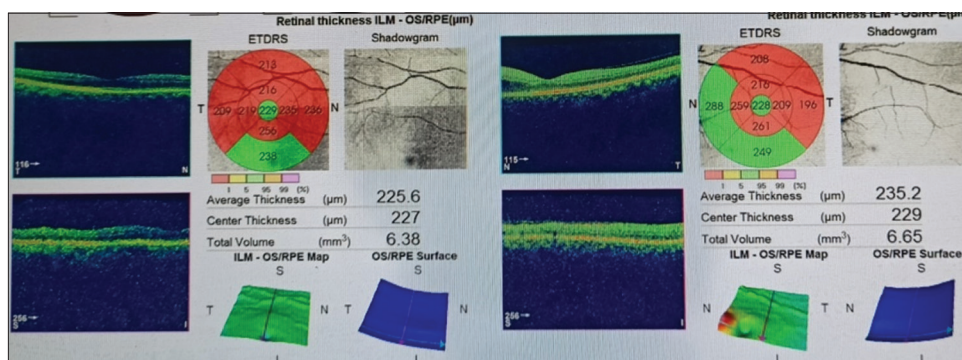


Figure 1: Spectral-domain optical coherence tomography-generated retinal thickness deviation map of a patient of both eyes showing severe retinal thinning due to hydroxychloroquine toxicity

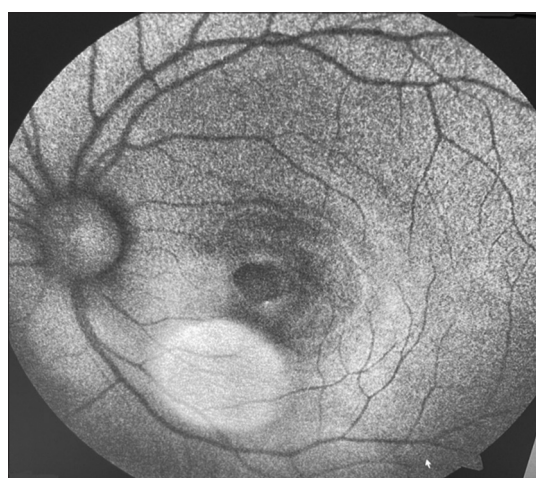


Figure 2: Fundus autofluorescence of the patient's left eye showing typical bull's-eye maculopathy due to hydroxychloroquine toxicity showing RPE degeneration on the macula

In our study, MD and PSD increase as the severity of the disease increases ($P < 0.005$) (Table 5).

DISCUSSION

In our study, the incidence of HCQS retinopathy was higher ($P < 0.01$) in between 50 and 60 years of age group, similar to De Sisternes *et al.*, who found that the mean age of HCQS retinopathy was 56 years ($P > 0.9$).¹¹ Uslu *et al.*, studied that HCQS retinopathy was higher in the 40–45 years of age group ($P = 0.3$).¹² In our study, the male-to-female ratio was 1:2 in group 2 ($P < 0.03$), similar to Melles *et al.*, who found that the retinal toxicity was higher in females ($P = 0.08$);⁷ whereas Abdelbaky *et al.*, observed no relationship between HCQS retinopathy and gender ($P = 0.003$).¹³ In our study of HCQS, retinopathy was slightly higher ($P < 0.01$) in low socioeconomic status group patients, similar to Pinto *et al.*,¹⁴ whereas Yusuf *et al.*, found that higher dose, long duration, and renal impairment as risk factors.¹⁵ In our study, there is a significant relation between diabetes mellitus, renal impairment, RA factor,

Table 3: Severity of HCQS retinopathy in patients of Group 2

Severity	Group 2 (affected) (%)
Early	40
Moderate	50
Severe	10

HCQS: Hydroxychloroquine

Table 4: Pattern of HCQS retinopathy in group 2 patients (affected)

Pattern	Group 2 (affected) (%)	P-value
Parafoveal	60	<0.001
Perifoveal	30	<0.001
Mixed	10	<0.001

HCQS: Hydroxychloroquine

and ANA and HCQS retinopathy ($P < 0.05$), similar to Anderson *et al.*¹⁶ Tangtavoran *et al.*, observed no direct relation between RA factor, ANA, and renal disease with HCQS retinopathy ($P < 0.05$).¹⁷ In our study, we found higher DAS scores and EULAR criteria as risk factors for HCQS retinopathy ($P < 0.05$). Do *et al.*, found no direct relationship between DAS and HCQS retinopathy.¹⁸ In our study, a significant moderate retinal thinning was observed in the parafoveal region ($P < 0.01$) similar to Lally *et al.*, studied the significant thinning in the parafoveal region ($P = 0.002$).¹⁹ Kim *et al.*, found retinal thinning in the pericentral region ($P = 0.05$).²⁰

In our study, thinning on the retinal thickness deviation map correlated significantly with the MD and PSD on HFA 30–2 and 10–2 ($P < 0.005$). Lee studied that HFA 10–2 fields were not revealing (normal results), while HFA 30–2 reveals only central scotoma in moderate-to-severe HCQS retinopathy patients ($P = 0.03$).²¹

Limitations of the study

This screening method mainly depends on patient's history of taking hcqs which is a subjective assesment.

Table 5: Pattern standard deviation and mean deviation on HFA 30–2 and 10–2 examination according to the severity of the HCQS retinopathy

HCQS retinopathy	HFA 30–2		HFA 10–2		P-value
	MD	PSD	MD	PSD	
Early	-1.52 dB	1.81 dB	-2.66dB	4.82 dB	<0.005
Moderate	-1.96 dB	1.76 dB	-2.87dB	5.49 dB	<0.005
Severe	-2.07 dB	2.22 dB	-3.89 dB	7.16 dB	<0.005

PSD: Pattern standard deviation, MD: Mean deviation, HCQS: Hydroxychloroquine

CONCLUSION

This study concluded that HCQS is a safer drug and can be used safely in these patients with proper HCQS retinal toxicity monitoring with an SD-OCT-generated retinal thickness deviation map and with regular follow-up to monitor reduced thickness in the parafoveal region.

ACKNOWLEDGMENT

We would like to acknowledge all participants and all staff of our department who assisted in the study.

REFERENCES

- Willis R, Seif AM, McGwin G Jr., Martinez-Martinez LA, González EB, Dang N, et al. Effect of hydroxychloroquine treatment on pro-inflammatory cytokines and disease activity in SLE patients: Data from LUMINA (LXXV), a multiethnic US cohort. *Lupus*. 2012;21(8):830-835. <https://doi.org/10.1177/0961203312437270>
- Marmor MF, Kellner U, Lai TY, Lyons JS, Mieler WF and American Academy of Ophthalmology. Revised recommendations on screening for chloroquine and hydroxychloroquine retinopathy. *Ophthalmology*. 2011;118(2):415-422. <https://doi.org/10.1016/j.ophtha.2010.11.017>
- Marmor MF, Kellner U, Lai TY, Melles RB, Mieler WF and American Academy of Ophthalmology. Recommendations on screening for chloroquine and hydroxychloroquine retinopathy (2016 revision). *Ophthalmology*. 2016;123(6):1386-1394. <https://doi.org/10.1016/j.ophtha.2016.01.058>
- Levy GD, Munz SJ, Paschal J, Cohen HB, Pince KJ and Peterson T. Incidence of hydroxychloroquine retinopathy in 1,207 patients in a large multicenter outpatient practice. *Arthritis Rheum*. 1997;40(8):1482-1486. <https://doi.org/10.1002/art.1780400817>
- Brewer EJ, Giannini EH, Kuzmina N and Alekseev L. Penicillamine and hydroxychloroquine in the treatment of severe juvenile rheumatoid arthritis. *N Engl J Med*. 1986;314(20):1269-1276. <https://doi.org/10.1056/NEJM198605153142001>
- Yam JC and Kwok AK. Ocular toxicity of hydroxychloroquine. *Hong Kong Med J*. 2006;12(4):294-304.
- Melles RB and Marmor MF. Pericentral retinopathy and racial differences in hydroxychloroquine toxicity. *Ophthalmology*. 2015;122(1):110-116. <https://doi.org/10.1016/j.ophtha.2014.07.018>
- Latasiewicz M, Gourier H, Yusuf HI, Luqmani R, Sharma MS and Downes MS. Hydroxychloroquine retinopathy: An emerging problem. *Eye (Lond)*. 2017;31(6):972-976. <https://doi.org/10.1038/eye.2016.297>
- Kim KE, Ahn SJ, Woo SJ, Park KH, Lee BR, Lee YK, et al. Use of OCT retinal thickness deviation map for hydroxychloroquine retinopathy screening. *Ophthalmology*. 2020;128(1):110-119. <https://doi.org/10.1016/j.ophtha.2020.06.021>
- Huang D, Swanson EA, Lin CP, Schuman JS, Stinson WG, Chang W, et al. Optical coherence tomography. *Science*. 1991;254(5035):1178-1181. <https://doi.org/10.1126/science.1957169>
- De Sisternes L, Hu J, Rubin DL and Marmor MF. Analysis of inner and outer retinal thickness in patients using hydroxychloroquine prior to development of retinopathy. *JAMA Ophthalmol*. 2016;134(5):511519. <https://doi.org/10.1001/2016.0155>
- Uslu H, Gurler B, Yildirim A, Tatar MG, Kantarc FA, Goker H, Pehlevan HS and Colak HN. Effect of hydroxychloroquine on the retinal layers: A quantitative evaluation with spectral domain optical coherence tomography. *J Ophthalmol*. 2016;2016:8643174. <https://doi.org/10.1155/2016/8643174>
- Abdelbaky MS, El Mamoun TA, Mabrouk FI, Hassan RM. Frequency and risk factors for hydroxychloroquine retinopathy among patients with systemic lupus erythematosus. *Egypt J Intern Med*. 2021;33(1):18. <https://doi.org/10.1186/s43162-021-00047-y>
- Pinto CM, Martinez SM, Santillan PS, Herrera JG, Contreras IP, Diaz SM, et al. Socioeconomic status and organ damage in Mexican systemic lupus erythematosus women. *Lupus*. 2015;24(11):1227-1232. <https://doi.org/10.1177/09612033155911621>
- Yusuf IH, Sharma S, Luqmani R and Downes SM. Hydroxychloroquine retinopathy. *Eye (Lond)*. 2017;31(6):828-845. <https://doi.org/10.1038/eye.2016.298>
- Anderson C, Blaha GR and Marx JL. Humphrey visual field findings in hydroxychloroquine toxicity. *Eye (Lond)*. 2011;25(12):1535-1545. <https://doi.org/10.1038/eye.2011.245>
- Tangtavoran N, Yospaiboon Y, Ratanapakorn T, Sinawat S, Sanguansak T, Bhoombunchoo C, et al. Incidence of and risk factors for chloroquine and hydroxychloroquine retinopathy in Thai rheumatologic patients. *Clin Ophthalmol*. 2016;10:2179-2185. <https://doi.org/10.2147/OPHTH.S119872>
- Do S, Du HJ, An XJ, Wang J and Lin A. The prevalence and risk factors of retinal toxicity associated with long-term hydroxychloroquine use. *Ann Rheumatic Dis*. 2021;80(1). <https://doi.org/10.1136/annrheumdis-2021.eular.328>
- Lally DR, Heier JS, Baumaal C, Witkin AJ, Maler S, Shah CP, et al. Expanded spectral domain-OCT findings in the early detection

- of hydroxychloroquine retinopathy and changes following drug cessation. *Int J Retina Vitreous*. 2016;2:18.
<https://doi.org/10.1186/s40942-016-0042-y>
20. Kim JW, Kim YY, Lee H, Park SH, Kim SK and Choe YJ. Risk of retinal toxicity in long term users of hydroxychloroquine. *J Rheumatol*. 2017;44(11):1674-1679.
<https://doi.org/10.3899/jrheum.170158>
21. Leen DH, Melles RB, Joe SG, Lee JY, Kim JG, Lee CK, et al. Pericentral hydroxychloroquine retinopathy in Korean patients. *Ophthalmology*. 2015;122(6):1252-1256.
<https://doi.org/10.1016/j.ophtha.2015.01.014>

Author's Contributions:

JK- Concept and design of the study, prepared the first draft of the manuscript; **SG**- Concept, coordination, statistical analysis and interpretation, and revision of the manuscript; **RK**- Interpreted the result, reviewed the literature and manuscript preparation.

Work Attributed to:

Maharani Laxmi Bai Medical College, Jhansi- 284128, Uttar Pradesh, India.

Orcid ID:

Jitendra Kumar- <https://orcid.org/0009-0009-3232-381X>

Surabhi Gupta- <https://orcid.org/0009-0006-0105-9444>

Rashmi Kumari- <https://orcid.org/0000-0001-9030-4099>

Source of Support: Nil, **Conflicts of Interest:** None declared.