

Correlation between optic nerve sheath diameter and Rotterdam computed tomography scoring in traumatic brain injury



Mahima Kale R¹, Rajeswari G², Anil Kumar Sakalecha³, Varshitha GR⁴, Kalathuru Uhasai⁵, Shantala Sawkar⁶

^{1,5,6}Junior Resident, ²Associate Professor, ³Professor and Head, ⁴Senior Resident, Department of Radio-Diagnosis, Sri Devaraj URS Medical College, Kolar, Karnataka, India

Submission: 24-02-2023

Revision: 04-05-2023

Publication: 01-06-2023

ABSTRACT

Background: In India and other developing nations, traumatic brain injuries (TBIs) are main cause of disability, socioeconomic loss, morbidity, and mortality. In patients with TBI, Rotterdam CT score (RCTS) and diameter of optic nerve sheath (ONSD) have both been reliable independent predictors of prognosis. ONSD measurement has become a substitute non-invasive technique for keeping track of intracranial pressure (ICP). **Aims and Objectives:** The aims of this study were to study correlation between ONSD and RCTS in predicting outcome and prognosis in patients with traumatic brain injury. **Materials and Methods:** Total 90 patients with TBI were included in study. All patients meeting inclusion criteria were included and CT scan was performed. RCTS was done based, on which patients were divided into two groups (mild and severe head injury). According to standard protocol, ONSD was measured. **Results:** Among 90 cases included that most common cause of injury was motor vehicle accident (72.2%). Mean ONSD in the present study was 4.37 ± 0.84 mm. About 57 (63.3%) patients had RCTS score of 1, 2, and 3 (mild head injury) and 33 (36.7%) had RCTS score of 4, 5, and 6 (severe head injury). Cutoff value of ONSD for predicting severity of TBI derived from receiver operating characteristic curve was >4.4 mm. There is a positive correlation between ONSD and RCTS. **Conclusion:** CT ONSD is a useful radiological tool to identify elevated ICP and it should be noted in every CT report in TBI cases.

Key words: Traumatic brain injury; Optic nerve sheath diameter; Rotterdam CT score and intracranial pressure

INTRODUCTION

In India and other developing nations, traumatic brain injuries (TBIs) are main cause of disability, socioeconomic loss, morbidity, and mortality. Because to its excellent sensitivity in identifying fractures and hematomas, computed tomography (CT) scan is gold standard in evaluation of TBI.¹ Both Rotterdam CT Score (RCTS) and optic nerve sheath diameter (ONSD) evaluated with CT imaging are independent predictors of prognosis in TBI patients. An external ventricular device is gold standard for diagnosing raised intracranial pressure (ICP), is extremely invasive, not available during initial evaluation and

contraindicated in individuals with coagulopathies. ONSD has lately become a substitute non-invasive technique for keeping track of ICP.^{2,3} In emergency room, ONSD and RCTS could be used as a preliminary triage tool as well as a way to decide if patients with TBI require a subsequent CT scan and know the prognosis of patient. Description of Rotterdam computed tomography score is shown in Table 1. One of the catastrophic consequences of TBI is elevated ICP. High mortality is associated with late diagnosis and intervention.⁴ Optic nerve is an extension of central nervous system and is covered with dura and arachnoid mater that contains cerebrospinal fluid (CSF).⁵ CSF space surrounding optic nerve is continuous with

Access this article online

Website:

<http://nepjol.info/index.php/AJMS>

DOI: 10.3126/ajms.v14i6.52775

E-ISSN: 2091-0576

P-ISSN: 2467-9100

Copyright (c) 2023 Asian Journal of Medical Sciences



This work is licensed under a Creative Commons Attribution-NonCommercial 4.0 International License.

Address for Correspondence:

Dr. Rajeswari, Associate Professor, Department of Radio-Diagnosis, Sri Devaraj URS Medical College, SDUAHER, Kolar - 563 103, Karnataka, India. **Mobile:** +91-9845174674. **E-mail:** rajeswari1954@yahoo.com

intracranial subarachnoid space. As ICP rises, CSF flow increases around optic nerve, stretching ONSD therefore increasing ONSD. Several studies have identified ONSD as one of the convenient, non-invasive, and indirect methods of determining ICP.² ONSD and RCTS are prognosticators of TBI.

Aims and objectives

The aims of this study were to study correlation between ONSD diameter and RCTS in predicting outcome and prognosis in patients with traumatic brain injury on admission.

MATERIALS AND METHODS

This is a hospital-based prospective study that included 90 subjects. All patients meeting the inclusion criteria with TBI were included and CT was performed in SIEMENS Somatom Emotion 16 slice spiral CT with a slice thickness of 0.75 mm. RTCS was done and based on scores patients were divided into two groups. Those patients with score of 1, 2, and 3 were classified as mild head injury and 4, 5, and 6 were classified as severe head injury. According to standard protocol, ONSD was measured in axial plane 3 mm behind posterior limit of eyeball in soft-tissue window. Figure 1, demonstrates the Standard protocol of measuring ONSD. If measurement in axial plane was not possible, sagittal plane was used. ONSD of both eyes was measured and mean ONSD was calculated.

RESULTS

Demographic data

Out of 90 patients with TBI, 26.7% (n=24) were female and 73.3% (n=66) were male. Mean age was 34.8 ± 13.8 years and ranged between 18 and 75 years. Most common cause of TBI was motor vehicle accident (72.2%), followed by fall injury (20.0%) and physical assault (7.8%) (Table 2).

RCTS

Out of 90 patients with TBI, 16 (17.8%) patients had score of 1, 27 (30.0%) patients had score of 2, 14 (15.6%) patients scored 3, 15 (16.7%) patients scored 4, 13 (14.4%) patients had score of 5, and 5 (5.6%) patients had score of 6 (Table 3). Fifty-seven (63.3%) patients had RCTS score of 1, 2, and 3 and were classified as mild head injury and 33 (36.7%) patients had RCTS of 4, 5, and 6 were classified as severe head injury.

ONSD

Mean ONSD in the present study was 4.37 ± 0.84 mm and measurement ranging between 3.0 and 6.1 mm. Mean ONSD in the right eye was 4.39 mm and in the left eye was 4.35 mm. In terms of ONSD measurement, there

Table 1 : Description of Rotterdam computed tomography score⁶

RCTS	Score
Basal cisterns	
Normal	0
Compressed	1
Absent	2
Midline shift (mm)	
No shift or shift ≤ 5	0
Shift ≥ 5	1
Epidural mass lesion	
Present	0
Absent	1
Intraventricular hemorrhage or traumatic subarachnoid hemorrhage	
Absent	0
Present	1
Sum score	+1

RCTS: Rotterdam CT score, CT: Computed tomography

Table 2: Distribution of mode of injury (n=90)

Mode of injury	Frequency (%)
Motor vehicle accident	65 (72.2)
Fall injury	18 (20.0)
Physical assault	7 (7.8)
Total	90 (100)

Table 3: Distribution of Rotterdam computed tomography score

Score	Frequency (%)
1	16 (17.8)
2	27 (30.0)
3	14 (15.6)
4	15 (16.7)
5	13 (14.4)
6	5 (5.6)
Total	90 (100)

was no statistical difference between the two eyes. ONSD measurement in a severe TBI case is shown in Figure 2.

Correlation between ONSD and severity of brain injury

Mean ONSD in patients with RCTS of 1, 2, and 3 was 3.8 ± 0.54 mm and with RCTS of 4, 5, and 6 was 5.2 ± 0.56 mm. Mean right ONSD was 3.8 mm in mild injury and 5.3 mm in severe injury. Mean left ONSD was 3.8 mm in mild injury and 5.2 mm in severe injury. In Figure 3, the mean ONSD value for RCTS is displayed.

The cutoff value of mean ONSD for prediction of severity of TBI was calculated with receiver operating characteristic (ROC) analysis which showed statistical significance for the area under curve of severe RCTS versus ONSD: AUC of 0.987 ($P < 0.0001$, 95% CI) (Figure 4). Best cutoff value of ONSD was found to be >4.4 mm with sensitivity of 97% and specificity 96.5%.

The cutoff value of the right ONSD for prediction of severity of TBI was calculated with ROC analysis and best

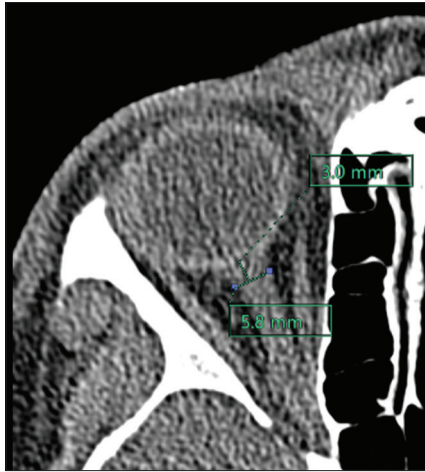

Figure 1: Computed tomography image showing standard protocol of measuring optic nerve sheath diameter in axial plane 3 mm behind posterior limit of eyeball in soft-tissue window

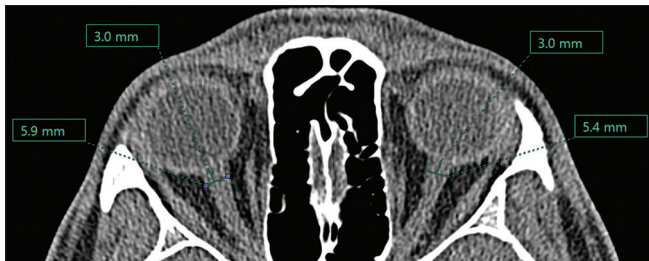

Figure 2: Computed tomography image axial plane showing optic nerve sheath measuring 5.9 mm in the right eye and 5.4 mm in the left eye

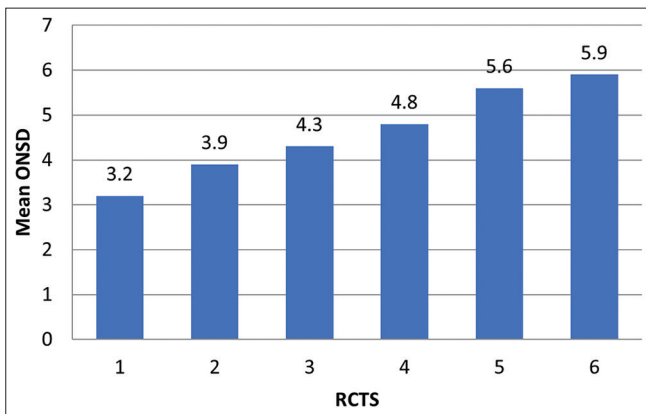


Figure 3: Bar graph depicting mean optic nerve sheath diameter along different Rotterdam CT score

cutoff value was identified to be >4.5 mm with sensitivity of 97% and specificity 100% (Figure 5).

The cutoff value of the left ONSD for prediction of severity of TBI was calculated with ROC analysis and best cutoff value was identified to be >4.6 mm with 90.9% sensitivity and 96.5% (Figure 6).

Correlation between ONSD and RCTS showed $P < 0.0001$ which was statistically significant and showed positive relation among the two parameters.

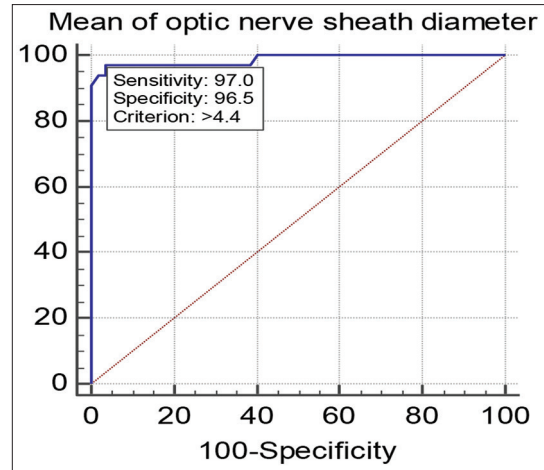


Figure 4: Receiver operating characteristic curve analysis depicting relationship between Rotterdam CT score and mean optic nerve sheath diameter

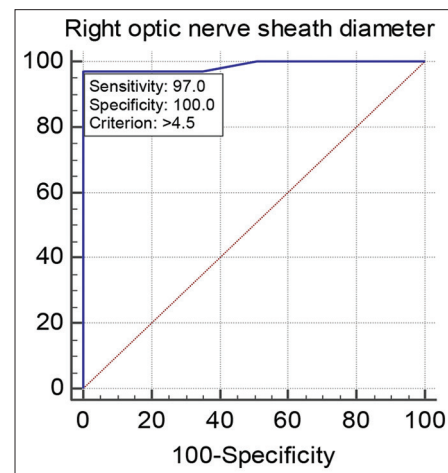


Figure 5: Receiver operating characteristic curve analysis depicting relationship between Rotterdam CT score and right optic nerve sheath diameter

DISCUSSION

There are very few research that compare RCTS and ONSD. Two independent measures RCTS and ONSD are both used to predict outcomes in cases of TBI. Therefore, this study was aimed to evaluate the correlation between the mean ONSD measurements with RCTS in patients with TBI.

In case of TBI, CT is the recommended imaging technique and it is widely accessible in most hospitals. RCTS is used to evaluate the severity of injury and prognosis in severe TBI patients based on imaging data. A higher score on the RCTS scale, which ranges from one to six, indicates a more severe injury. In numerous studies, RCTS was regarded as a stand-alone radiological prognostic tool.^{7,8} An indication of a bad prognosis is a raised ICP in TBI. For effective management, raised ICP must be identified

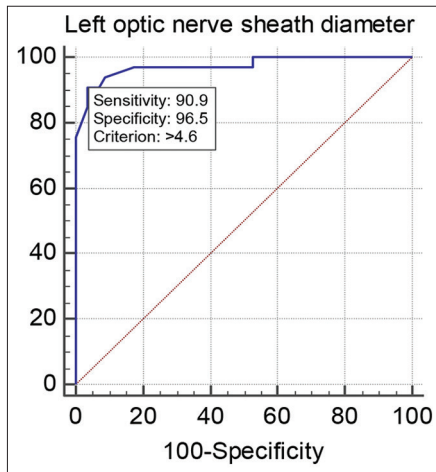


Figure 6: Receiver operating characteristic curve analysis depicting relationship between Rotterdam CT score and left optic nerve sheath diameter

quickly. An alternate indirect method of monitoring ICP is measuring ONSD. Several investigations have established correlation between the CT measurement of ONSD and ICP. In contrast to other CT findings, Sekhon et al., found that ONSD was a better predictor of elevated ICP.⁹

In the present study, RCTS demonstrated a positive correlation with ONSD value. The ONSD values for the RCTS 1, 2, and 3 scores were lower than those for the RCTS 4, 5, and 6, which had higher ONSD values. Similar to this study, Das et al., demonstrated a linear association between RCTS scores and mean ONSD values.¹⁰

Many research revealed various cutoff values for ONSD. ONSD <5.8 mm is regarded as a sign of severe TBI. According to a study by Sekhon et al., a cutoff ONSD value of 6 mm had 97% sensitivity and 42% specificity.⁹ The optimal cutoff value for mean ONSD and RCTS severity in the present investigation was >4.4 mm, with sensitivity being 97% and specificity being 96.5%. According to Soldatos et al., the study ONSD is associated with severe head trauma and elevated ICP. 5.7 mm was shown to be greatest cutoff for ONSD in prediction of elevated ICP, with sensitivity and specificity of 74.1% and 100%, respectively.¹¹ Elevated ICP and the ONSD value on CT images are positively correlated.

Limitations of the study

Our study has certain limitations because there was no link between neurological outcomes and the variables studied. For the estimation of normal ONSD, no comparison to a control group was made. As the same coinvestigator conducted every measurement, it was unable to evaluate the inter- and intra-observer variability. Despite these

drawbacks, ONSD can be utilized as a substitute technique to identify increased ICP.

CONCLUSION

The diagnosis of elevated ICP can be made using the ONSD as a triage tool. CT ONSD may be a useful radiological tool to rule out existence of elevated ICP, it should be noted in every report of CT scan in cases of TBI.

ACKNOWLEDGMENT

Would like to express my deepest gratitude to all faculty, my fellow postgraduates and technicians, Department of Radio-Diagnosis, Sri Devaraj Urs Medical College, Tamaka, Kolar, Karnataka.

REFERENCES

- Alexiou GA, Sfakianos G and Prodromou N. Pediatric head trauma. *J Emerg Trauma Shock*. 2011;4(3):403-408. <https://doi.org/10.4103/0974-2700.83872>
- Tayal VS, Neulander M, Norton HJ, Foster T, Saunders T and Blaivas M. Emergency department sonographic measurement of optic nerve sheath diameter to detect findings of increased intracranial pressure in adult head injury patients. *Ann Emerg Med*. 2007;49(4):508-514. <https://doi.org/10.1016/j.annemergmed.2006.06.040>
- Dubourg J, Javouhey E, Geeraerts T, Messerer M and Kassai B. Ultrasonography of optic nerve sheath diameter for detection of raised intracranial pressure: A systematic review and meta-analysis. *Intensive Care Med*. 2011;37(7):1059-1068. <https://doi.org/10.1007/s00134-011-2224-2>
- Miller MT, Pasquale M, Kurek S, White J, Martin P, Bannon K, et al. Initial head computed tomographic scan characteristics have a linear relationship with initial intracranial pressure after trauma. *J Trauma*. 2004;56(5):967-972; discussion 972-973. <https://doi.org/10.1097/01.ta.0000123699.16465.8b>
- Hansen HC and Helmke K. The subarachnoid space surrounding the optic nerves. An ultrasound study of the optic nerve sheath. *Surg Radiol Anat*. 1996;18(4):323-328. <https://doi.org/10.1007/BF01627611>
- Huang YH, Deng YH, Lee TC and Chen WF. Rotterdam computed tomography score as a prognosticator in head-injured patients undergoing decompressive craniectomy. *Neurosurgery*. 2012;71(1):80-85. <https://doi.org/10.1227/NEU.0b013e3182517aa1>
- Murray GD, Butcher I, McHugh GS, Lu J, Mushkudiani NA, Maas AI, et al. Multivariable prognostic analysis in traumatic brain injury: Results from the IMPACT study. *J Neurotrauma*. 2007;24(2):329-337. <https://doi.org/10.1089/neu.2006.0035>
- Maas AI, Steyerberg EW, Butcher I, Dammers R, Lu J, Marmarou A, et al. Prognostic value of computerized tomography scan characteristics in traumatic brain injury: Results from the IMPACT study. *J Neurotrauma*. 2007;24(2):303-314. <https://doi.org/10.1089/neu.2006.0033>
- Sekhon MS, McBeth P, Zou J, Qiao L, Kolmodin L,

- Henderson WR, et al. Association between optic nerve sheath diameter and mortality in patients with severe traumatic brain injury. *Neurocrit Care*. 2014;21(2):245-252.
<https://doi.org/10.1007/s12028-014-0003-y>
10. Das SK, Shetty SP and Sen KK. A novel triage tool: Optic nerve sheath diameter in traumatic brain injury and its correlation to Rotterdam computed tomography (CT) scoring. *Pol J Radiol*. 2017;82:240-243.
<https://doi.org/10.12659/PJR.900196>
11. Soldatos T, Karakitsos D, Chatzimichail K, Papathanasiou M, Gouliamos A and Karabinis A. Optic nerve sonography in the diagnostic evaluation of adult brain injury. *Crit Care*. 2008;12(3):R67.
<https://doi.org/10.1186/cc6897>

Authors' Contributions:

MKR- Definition of intellectual content, literature survey, prepared first draft of manuscript, implementation of study protocol, data collection, data analysis, manuscript preparation, and submission of article; **R**- Concept, design, clinical protocol, manuscript preparation, editing, and manuscript revision; **AKS**- Design of study, statistical analysis, and interpretation; **VGR**- Review manuscript; **KU**- Coordination and manuscript revision; and **SS**- Coordination and manuscript revision.

Work attributed to:

Sri Devaraj URS Medical College, Tamaka, Kolar, Karnataka, India

Orcid ID:

Dr. Mahima Kale R - <https://orcid.org/0000-0002-2372-6205>
Dr. Rajeswari - <https://orcid.org/0000-0002-3014-2232>
Dr. Anil Kumar Sakalecha - <https://orcid.org/0000-0003-2957-4908>
Dr. Varshitha GR - <https://orcid.org/0000-0003-3511-1328>
Dr. Kalathuru Uhasai - <https://orcid.org/0000-0002-1092-4210>
Dr. Shantala Sawkar - <https://orcid.org/0009-0008-8171-5118>

Source of Support: Nil, **Conflicts of Interest:** None declared.