

Nasal polyps and its histopathological classification: A retrospective study



Jitendra Pratap Singh Chauhan¹, Ritu Gupta², Abhay Kumar³

¹Professor Junior Grade, ²Associate Professor, ³Professor and Head, Department of ENT, Uttar Pradesh University of Medical Sciences, Etawah, Uttar Pradesh, India

Submission: 18-02-2023

Revision: 24-06-2023

Publication: 01-08-2023

ABSTRACT

Background: The diagnosis of nasal polyp is made according to clinical and radiological criteria, while histopathologic examination is important for an accurate diagnosis. Histological classification of nasal polyps and its clinical implications are very rarely reported in the literature. **Aims and Objectives:** The aim of this study was to study clinical presentation and site of occurrence of nasal polyps and histologically classify nasal polyps in relation to studies published in the literature. We classified the histological changes as described by Davidson and Hellquist. **Materials and Methods:** Based on the inclusion and exclusion criteria, the 315 subjects were included in our study, which include eosinophilic polyp, fibro-inflammatory polyp, polyp with sero-mucinous gland hyperplasia, and polyp with stromal atypia. **Results:** Sinonasal polyps can be classified in the following way histologically: edematous or eosinophilic polyp 189 cases (60%); fibro-inflammatory polyp: 66 cases (21%); polyp with seromucinous gland hyperplasia: 35 cases (11%), polyp with stroma atypia: no case (0%), and fibrotic 25 cases (8%). **Conclusion:** We concluded that the nasal polyps mainly present as an edematous or eosinophilic pattern on histopathological examination. Studies on the histopathology of nasal polyps would help us to understand this disease more appropriately for treatment plan. Further differentiation of nasal polyps may help to develop new therapeutic strategies that are tailored according to the respective group.

Key words: Nasal polyps; Histological classification; Biopsy; Chronic rhinosinusitis; Allergy

INTRODUCTION

Nasal polyps were first reported approximately 4,000 years ago. The disease was mentioned in ancient Egyptian and Indian medical literature. The word polyp originates from Latin polypus and Greek polypous where it means many feet. Sino nasal polyps are soft, painless, benign mucosal swellings on the lining of the nose and paranasal sinuses. Nasal polyps can be considered a sign or a physical finding rather than a disease. They are very common lesion encountered in clinical practice.¹ Overall prevalence rate of nasal polyposis ranges from 1% to 4% in general population and 25–30% of patients with chronic rhinosinusitis.^{2,3} It is more common in adults than children. Term chronic rhinosinusitis with nasal polyposis is frequently used when discussing the topic of nasal

polyps because nasal polyps are common manifestation of chronic rhinosinusitis. According to the European academy of allergology and clinical immunology and European rhinology Society, nasal polyps can be counted as a subtype of chronic rhinosinusitis. Many etiologic factors and pathologic process have been proposed to be involved the development of nasal polyps. The underlying mechanisms of nasal polyps are still not clear. Etiology of nasal polyps is multifactorial, associated with chronic infection,¹ allergy,^{4,5} cystic fibrosis, primary ciliary dyskinesia, and certain systemic vasculitis. The association of nasal polyps with asthma and aspirin sensitivity is well recognized. The roles of allergy and infection are more frequently considered. Although some studies suggest little evidence to support the role of IgE-mediated allergy as the direct cause.⁶⁻⁸ Clinical manifestations of nasal polyp are nasal blockage,

Access this article online

Website:

<http://nepjol.info/index.php/AJMS>

DOI: 10.3126/ajms.v14i8.52615

E-ISSN: 2091-0576

P-ISSN: 2467-9100

Copyright (c) 2023 Asian Journal of Medical Sciences



This work is licensed under a Creative Commons Attribution-NonCommercial 4.0 International License.

Address for Correspondence:

Dr. Ritu Gupta, Associate Professor, Department of ENT, Uttar Pradesh University of Medical Sciences, Etawah - 206 130, Uttar Pradesh, India. **Mobile:** +91-7599005252. **E-mail:** rituguptasaraf@gmail.com

congestion, hyposmia, anosmia, nasal discharge, post-nasal drip, rhinorrhea, facial pain, headache, fatigue, general malaise, and sleep disturbances.^{9,10} Most polyps originate from the cleft's mucosa, ostia mucosa, and ostiomeatal complex region.¹¹ Diagnosis of nasal polyps can be made by history, clinical examination, nasal endoscopy, radiography, and additional tests for allergy, aspirin sensitivity, and pulmonary function tests. The common method to diagnose nasal polyp is radiography. CT scan of the nose and paranasal sinuses is required before any surgery of nose and paranasal sinuses and staging of polyps with CT will help to assess the severity of inflammation and damage to the sinuses.¹² The mainstay of treatment of nasal polyposis is intranasal corticosteroid, which can reduce polyp size and increase nasal airway patency. If drug treatment does not reduce or eliminate polyp, the patient may need functional endoscopic sinus surgery to remove them. Surgery can increase osteal patency, reduce inflammatory exudate, and increase drainage. Nasal polyps are most frequent nasal masses which are encountered in various histopathological analysis. The histopathological examination allows the detailed information of epithelial and stromal changes, especially of different populations of inflammatory cells involved in the pathogenesis of this disease.¹³ The most important stromal changes were edema and eosinophilic infiltration. The presence of intraepithelial as well as stromal eosinophils probably plays a role in the process of remodeling the mucosa of chronic rhinosinusitis with nasal polyps. Classification of the sinonasal polyps into various histological types may help us to know the clinical presentation, clinical outcome, treatment, and prognosis of the disease. Nasal polyps have been classified histologically into neutrophilic and eosinophilic types by Mygind.¹⁴ Kakoi and Hiraide proposed a different histological classification of nasal polyps according to types of tissue reaction into edematous type, ductal type (glandular and cystic type), and fibrous type.¹⁵ Hellquist classified the histological patterns of nasal polyps into four types.¹⁶

The overlapping histological features of the nasal polyp makes it difficult for precise classification of the nasal polyps. Many studies classified nasal polyps into different types, but very few studies have been done in this region of Uttar Pradesh. Hence, the present study has been done to know the histological changes in nasal polyps. It is not clear now how different therapies for the clinical treatment of nasal polyps can be determined on the basis of histological classifications.

Aims and objectives

Aims

The aim of the study was to do a retrospective study on nasal polyps in a tertiary care center.

Objectives

1. To study clinical presentation and site of occurrence of nasal polyps.
2. To histologically classify nasal polyps in relation to studies published in the literature.

MATERIALS AND METHODS

This retrospective study from January 2016 to February 2020 comprised 315 cases.

Patients with preoperative and postoperative diagnosis of neoplastic disease were excluded from the study. Patients with a history of prior surgery and congenital nasal polyps were also excluded from the study. Source of data included operative records, histopathologic reports, and preoperative and postoperative notes.

The study included 315 nasal polyps from patients hospitalized and operated in the ENT Department. All the specimens were sent in 10% formalin to the histopathology section of the department of pathology along with the relevant clinical information such as age, sex, chief complaints, and findings of clinical examination. The tissues were processed and histopathologic sections of about 5–6-micron thickness were obtained and stained by hematoxylin and eosin stain. Additional testing in the form of special stains was employed wherever needed. Special stains such as periodic acid-schiff and Masson's Trichrome were used to detect or confirm basement membrane thickening, fungal elements, goblet cell hyperplasia, and fibrosis. All samples of nasal polyps were studied to characterize their gross and morphological features and classified according to the histological patterns published in the literature.

The study protocol was approved by the Institutional Ethics committee (No.146/2019–20). As we are a teaching hospital and university, all patients signed a written and informed consent at the time of admission by which they agree that their medical data can be used in scientific purposes.

Patients of both genders between 9 and 67 years of age with clinical diagnosis of sinonasal polyps who underwent functional endoscopic sinus surgery at the department of otorhinolaryngology, where the final histopathological diagnosis was sinonasal polyp, were included in this retrospective study.

Data were obtained from patients medical records for this study. SPSS statistics 22.0 version was used for data analysis. Data obtained underwent standard statistical

analysis. Data were shown as mean±standard deviation and number of cases.

RESULTS

There were 315 patients with a clinical and a histological diagnosis of sinonasal polyp, of whom 214 were males and 101 were females. Male-to-female ratio was 2.12: 1. Table 1 and Figure 1 show that sinonasal polyps were more common in males than females.

Patients were aged between 9 and 67 years. Patients’ mean age at presentation in the present study was 36.53±12.38 (SD) years. In the present study, it was observed that the maximum number of cases 117 (37.14%) were between 31 and 40 years of age. Next common age group involved was between 41 and 50 years (70 cases 22.22%). Only 11 cases were found to be above 60 years. Figure 2 shows age distribution of patients.

Table 2 gives an overview of various presenting symptoms. Nasal mass being the most common presentation seen in 277 (88%) cases, followed by nasal blockage seen in 240 (76%) cases and hyposmia/anosmia seen in 63 cases (20%) and watery discharge seen in 63 cases (20%).

Table 3 compares the sites involved by nasal polyps. The most common site being ethmoidal sinus and the least common being the frontal sinus with no cases reported.

Table 1: Sex distribution of patients	
Sex	Number of cases (%)
Males	214 (67.94)
Females	101 (32.06)
Male:female	2.12:1

Table 2: Various clinical presenting symptoms noted in patients	
Presenting symptoms	Number of cases (%)
Nasal blockage	240 (76)
Nasal mass	277 (88)
Hyposmia/anosmia	63 (20)
Watery nasal discharge (rhinorrhoea and sneezing)	63 (20)

Table 3: Sites involved by nasal polyps	
Site	Cases, n (%)
Ethmoid sinus	132 (42)
Maxillary sinus	123 (29)
Turbinate (superior, middle)	60 (19)
Posterior nasal cavity	31 (10)
Frontal sinus	0

We examined 315 nasal polyps sample. Grossly, polyps were lobular, mobile swelling with soft consistency often shiny with a translucent pink appearance. Cut surface was pale to red and moist. The size of a polyp varied from 1 to 4 cm. We classified the histological changes as described by Davidson and Hellquist. Edematous or eosinophilic polyps (Figure 3), 189 cases (60%), fibroinflammatory polyps (Figure 4), 66 cases (21%), polyps with hyperplasia of seromucinous glands (Figure 5), 35 cases (11%), and polyp with fibrotic features (Figure 6), 25 cases (8%). Table 4 shows comparison of various studies with our study.

DISCUSSION

Nasal polyp is a widespread health problem worldwide. Nasal polyps are commonly encountered in clinical practice and important from both clinical and pathological perspectives as they can give rise to varieties of histological patterns.

Out of the 315 cases studied, 214 cases were males and 101 cases females with male-to-female ratio of 2.12: 1. We observed that the males are more often affected than females.

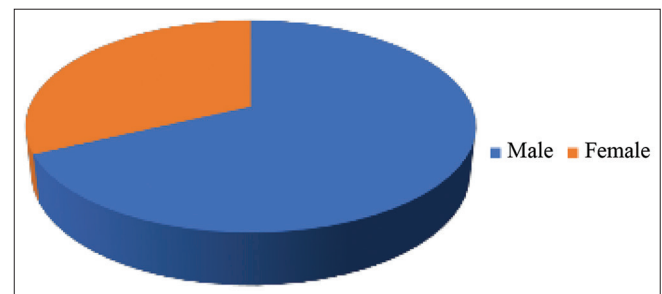


Figure 1: Gender profile

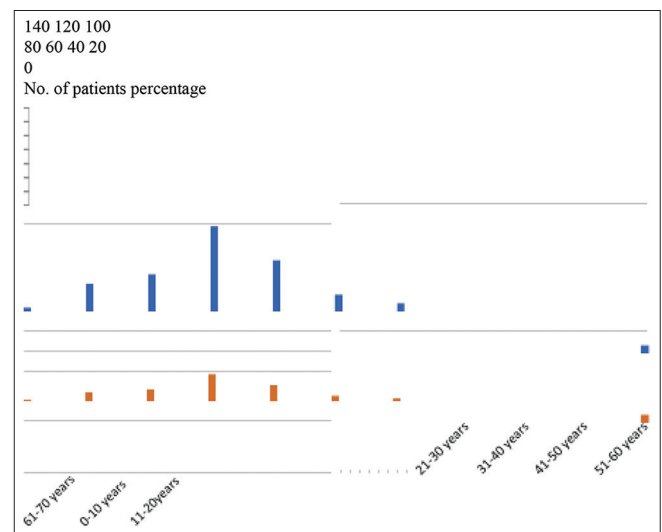
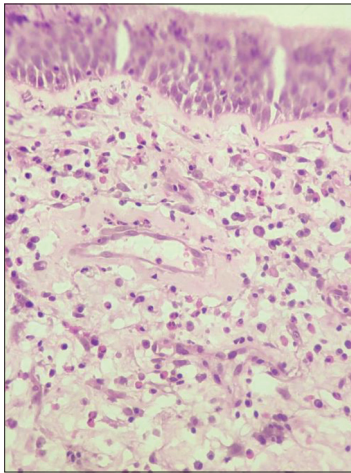
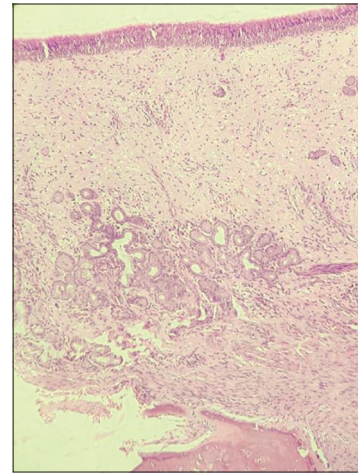
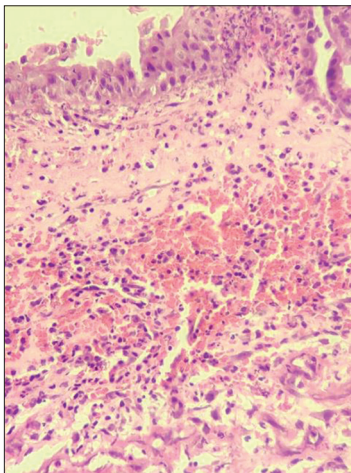
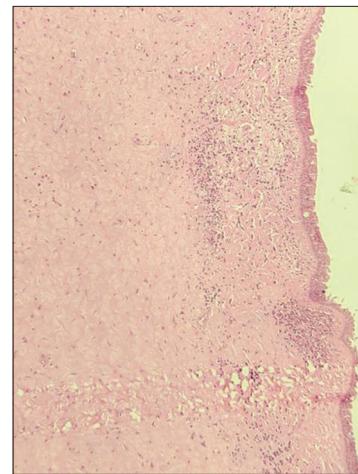


Figure 2: Age distribution of patients

Table 4: Comparison of various studies with our study

Histological classification	Kakoi and Hiraide, 1987	Davidsson and Hellquist, 1993	Couto et al., 2006	Present study
Edematous/eosinophilic, n (%)	105 (60)	82 (86.3)	65 (73)	189 (60)
Fibro-inflammatory, n (%)	23 (13)	7 (7.3)	16 (18)	66 (21)
Hyperplasia of seromucous gland, n (%)	47 (27)	5 (5.3)	6 (6.7)	35 (11)
Stromal atypia, n (%)	0	1 (1.1)	2 (2.3)	0
Fibrotic, n (%)	0	0	0	25 (8)
Total	175	95	89	315

**Figure 3:** Features of eosinophilic polyps (HE x400)**Figure 5:** Polyp with hyperplasia of seromucinous glands (HE x40)**Figure 4:** Polyp with fibro-inflammation (HE x400)**Figure 6:** Polyp with fibrotic features (HE x40)

In a study by Vento et al.,¹⁷ male-to-female ratio was 2.4:1, and in the study by Diamantopoulos et al.,¹⁸ it was 3.3:1.

Patients were aged between 9 and 67 years. Patients' mean age at presentation in the present study was 36.53 ± 12.38 (SD) years. In the present study, it was observed that a maximum number of cases 117 (37.14%) were between 31 and 40 years of age. Next common age group involved was between 41 and 50 years (70 cases 22.22%). Although adolescence or early childhood is stated to be the most common age of occurrence, there are reports of this disease

occurring in all age groups.¹⁹ The present observations also correlate with the study of Jareoncharsri et al.²⁰

Kakoi and Hiraide studied a series of 175 patients, subdivided polyps into edematous polyps comprising 60% of the total cases observed, whereas cystic or glandular polyps were second most common type comprising 27% and least number of cases were found of fibrous polyps 13%.¹⁵ Davidson and Hellquist analyzed 95 patients and classified sinonasal polyps histologically into four categories: edematous or eosinophilic polyps

(86.3%), fibroinflammatory polyps (7.3%), polyps with seromucinous gland hyperplasia (5.3%), and polyps with stromal atypia (1.1%).¹⁶ Hellquist examined in detail the histological differences between the polyps in his study. Hellquist classified the histological patterns of nasal polyps into four types.¹⁶

1. Edematous or eosinophilic polyps shows stromal edema containing numerous eosinophils and mast cells, goblet cell hyperplasia in the respiratory epithelium, and basal membrane thickening separating the epithelium from the edematous stroma
2. Fibroinflammatory polyps (Chronic inflammatory polyp) show features that include a lack of stromal edema and goblet cell hyperplasia. Metaplastic changes in squamous and cuboidal epithelium are usually present. Basement membrane thickening may also be present which is milder than the previous type. Intense lymphocyte-predominant inflammatory infiltrate is present. Many fibroblasts with fibrosis are found in the stroma. Seromucinous glands hyperplasia and dilated vessels are also found²¹
3. Polyps with seromucinous gland hyperplasia show numerous seromucinous glands and ductal structures in an edematous stroma. This type can have features that are similar to the first most common type. The main difference between the two is the presence of more glands along with ductal structure in this type. Histological examination typically finds many cylindrical glands with eccentrically placed nuclei. These glands are usually connected to the epithelium and does not show any atypia²²
4. Polyps with stromal atypia: This is a very rare type that can be hardly distinguished from neoplasms microscopically. Grossly, it looks similar to other types of polyps. However, the histological findings include bizarre atypical cells, which is hyperchromatic and stellate. Sometimes, these cells can be irregular with the presence of vesicular cytoplasm. These atypical cells are only present in few areas of the polyp that reflect reactive fibroblasts. Only a few cases show the presence of atypical cells in the whole polyp. The most distinguishing feature of this type from a neoplasm is the lack of mitoses. The absence of cytoplasmic cross-striation and glycogen content are characteristic. Malignancies (such as malignant melanoma and neurogenic sarcoma) can be ruled out by immunostaining.²³

In our study, we classified the polyps into histological patterns similar to those described by Davidson and Hellquist. Edematous or eosinophilic polyps (Figure 3), 189 cases (60%), fibroinflammatory polyps (Figure 4), 66 cases (21%), polyps with hyperplasia of seromucinous glands (Figure 5), 35 cases (11%), and polyp with fibrotic

features (Figure 6), 25 cases (8%). Table 4 shows comparison of various studies with our study. In our study, we found a maximum number of cases of edematous or eosinophilic polyp. Fibroinflammatory polyps were the second most common followed by polyps with seromucinous gland hyperplasia and polyps with fibrosis. All the other studies including our study showed a maximum number of edematous or eosinophilic polyp. Findings of study done by Couto et al., were also consistent with our study.²⁴ Table 4 shows a comparison between various studies.

The treatment aim for nasal polyps is to reduce their size or eliminate them. Medications are the first approach, surgery may sometimes be required, but it may not provide a permanent solution because polyps tend to recur. Nasal polyps treatment starts with drugs which can make large polyps shrink or disappear. Drug treatments include nasal corticosteroids which include budesonide, fluticasone, mometasone, triamcinolone, and beclomethasone. If a nasal corticosteroid is not working, oral corticosteroids can be prescribed. If drug treatment is not working, the patient may need functional endoscopic sinus surgery to remove them.

However, our study has some limitations. First, this was a retrospective study, so data were collected in as much detail as possible. In addition, CT scan and endoscopy were not available for all patients. Second, this was a single-center study, and the results were only applicable to patients from this region of Uttar Pradesh. Preoperative data on the use of corticosteroids and antibiotic could not be gathered completely.

We recommend multicenter national and international studies to fully understand the clinical and pathological features of nasal polyps and to find out novel therapeutic options.

Limitations of the study

This study has mainly subjects from nearby hospital region who presented to the OPD. If we include larger area with more number of subjects then we can get better representation of nasal polyps

CONCLUSION

The nasal polyps significantly impair the quality of life and have the tendency to recur despite various medical and surgical interventions. It usually presents with nasal mass, nasal obstruction, watery nasal discharge, hyposmia, and anosmia. It usually originates from the ethmoid sinus and the middle meatus. In this study, we did a careful and detailed examination of the histological features of nasal polyps. Findings of this study demonstrated a higher prevalence of edematous/eosinophilic polyps, followed

by fibroinflammatory polyps. Our study recommends, all polyps need histopathological examination. Further studies are needed to understand the correlation between histopathological features and the nasal polyps. Clearly, the histology of nasal polyps requires a deeper understanding to develop novel diagnostic and therapeutic tools or strategies.

ACKNOWLEDGMENTS

We would like to express our gratitude to the entire department of pathology UPUMS Saifai for their support and contribution in this study.

REFERENCES

- Allen JS, Eisma R, Leonard G, LaFreniere D and Kreutzer D. Characterization of the eosinophil chemokine RANTES in nasal polyps. *Ann Otol Rhinol Laryngol*. 1998;107(5 Pt 1):416-420. <https://doi.org/10.1177/000348949810700510>
- Stevens WW, Schleimer RP and Kern RC. Chronic rhinosinusitis with nasal polyps. *J Allergy Clin Immunol Pract*. 2016;4(4):565-572. <https://doi.org/10.1016/j.jaip.2016.04.012>
- Fokkens WJ, Lund VJ, Hopkins C, Hellings PW, Kern R, Reitsma S, et al. European position paper on chronic rhinosinusitis and nasal polyps 2020. *Rhinology*. 2020;58(Suppl S29):1-464. <https://doi.org/10.4193/Rhin20.600>
- Settipane GA, Lund VJ, Bernstein JM and Tos M, editors. *Nasal Polyps: Epidemiology, Pathogenesis and Treatment*. In: Providence, Rhode Island: The New England and Regional Allergy Proceedings; 1997.
- Mygind N and Lildholdt T, editors. *Nasal Polyposis: An Inflammatory Disease and its Treatment*. Copenhagen: Munksgaard; 1997.
- Sanchez SA, Brieva JA and Rodriguez C. Regulation of immunoglobulin secretion by plasma cells infiltrating nasal polyps. *Laryngoscope*. 2000;110(7):1183-1188. <https://doi.org/10.1097/00005537-200007000-00022>
- Voegels RL, Santoro P, Butugan O and Formigoni LG. Nasal polyposis and allergy: Is there a correlation? *Am J Rhinol*. 2001;15(1):9-14. <https://doi.org/10.2500/105065801781329365>
- Bachert C, Gevaert P, Holtappels G, Johansson SG and Van Cauwenberge P. Total and specific IgE in nasal polyps is related to local eosinophilic inflammation. *J Allergy Clin Immunol*. 2001;107(4):607-614. <https://doi.org/10.1067/mai.2001.112374>
- Bachert C, Gevaert P, Holtappels G, Cuvelier C and van Cauwenberge P. Nasal polyposis: From cytokines to growth. *Am J Rhinol*. 2000;14(5):279-290. <https://doi.org/10.2500/105065800781329573>
- Valera FC and Anselmo-Lima WT. Evaluation of efficacy of topical corticosteroid for the clinical treatment of nasal polyposis: Searching for clinical events that may predict response to treatment. *Rhinology*. 2007;45(1):59-62.
- Dasgupta A, Ghosh RN and Mukherjee C. Nasal polyps - histopathologic spectrum. *Indian J Otolaryngol Head Neck Surg*. 1997;49(1):32-37. <https://doi.org/10.1007/BF02991708>
- Lund VJ. Diagnosis and treatment of nasal polyps. *BMJ*. 1995;311(7017):1411-1414. <https://doi.org/10.1136/bmj.311.7017.1411>
- Enache I, Ioniță E, Mitroi M, Anghelina F, Mogoantă C, Ciolofan S, et al. Histopathological features of chronic rhinosinusitis with nasal allergic polyps. *Curr Health Sci J*. 2020;46(1):66-71. <https://doi.org/10.12865/CHSJ.46.01.09>
- Mygind N. *Nasal Polyps*. In: *Nasal Allergy*. London: Black well Scientific Publication; 1978. p. 233-238.
- Kakoi H and Hiraide F. A histological study of formation and growth of nasal polyps. *Acta Otolaryngol*. 1987;103(1-2):137-144. <https://doi.org/10.3109/00016488709134709>
- Hellquist HB. Nasal polyps update. *Histopathology*. Allergy Asthma Proc. 1996;17(5):237-242.
- Vento SI, Wolff CH, Salven PJ, Hytönen ML, Ertama LO and Malmberg CH. Vascular permeability factor/vascular endothelial growth factor in nasal polyps. *Acta Otolaryngol Suppl*. 2000;543:170-174. <https://doi.org/10.1080/000164800454314>
- Diamantopoulos II, Jones NS and Lowe J. All nasal polyps need histological examination: An audit-based appraisal of clinical practice. *J Laryngol Otol*. 2000;114(10):755-759. <https://doi.org/10.1258/0022215001904086>
- Khan N, Zafar U, Afroz N, Ahmad SS and Hasan A. Masses of nasal cavity, paranasal sinuses and nasopharynx: A clinicopathological study. *Indian J Otolaryngol Head Neck Surg*. 2006;58(3):259-263. <https://doi.org/10.1007/BF03050834>
- Jareoncharsri P, Bunang C, Muangsomboon S, Tunsuriyawong P and Assanasane P. Clinical and histopathological classification of nasal polyps in Thais. *Siriraj Hosp Gaz*. 2002;54(11):689-697.
- Salaria N, Sharma N, Garg U, Saluja SK and Agarwal R. Inflammatory septal nasal polyp. *Iran J Otorhinolaryngol*. 2015;27(81):319-323.
- Khan RA, Chernock RD and Lewis JS Jr. Seromucinous hamartoma of the nasal cavity: A report of two cases and review of the literature. *Head Neck Pathol*. 2011;5(3):241-247.
- Tuziak T, Kram A and Woyke S. Edematous nasal polyp with atypical stromal cells misdiagnosed cytologically as rhabdomyosarcoma. A case reports. *Acta Cytol*. 1995;39(3):521-524.
- Couto LG, Fernandes AM, Brandão DF, de Santi Neto D, Valera FC and Anselmo-Lima WT. Histological aspects of rhinosinusitis polyps. *Braz J Otorhinolaryngol*. 2008;74(2):207-212. [https://doi.org/10.1016/s1808-8694\(15\)31090-9](https://doi.org/10.1016/s1808-8694(15)31090-9)

Authors Contribution:

JPSC- Manuscript writing; RG- Manuscript writing; VM- Guiding and proofreading manuscript.

Work attributed to:

Uttar Pradesh University of Medical Sciences, Saifai, Etawah 206130.

Orcid ID:

Jitendra Pratap Singh Chauhan - <https://orcid.org/0000-0003-0162-5320>

Ritu Gupta - <https://orcid.org/0000-0003-1287-578X>

Source of Funding: None, Conflicts of Interest: None.