

MUCINOUS CARCINOMA OF BREAST: FNAC AS EFFECTIVE DIAGNOSTIC MODALITY

CASE REPORT, Vol-3 No.3

Asian Journal of Medical Science, Volume-3(2012)

<http://nepjol.info/index.php/AJMS>

Ruchita Tyagi¹, Mahendra Kumar¹, Pranay Tanwar² Pranab Dey³ 1. Senior Resident, 3. Professor, Department of Cytology and Gynecological Pathology, Postgraduate Institute of Medical Education and Research (PGIMER), Chandigarh- 160012.

2. Assistant Professor, Laboratory Oncology Unit Dr B.R.A.I.R.C.H All India Institute of Medical Sciences, New Delhi 110029

ABSTRACT

CORRESPONDENCE:

Dr Pranay Tanwar
Assistant Professor, Laboratory
Oncology Unit
Room No 425, 4th Floor,
Dr. B.R.A. Institute Rotary
Cancer Hospital
All India Institute of Medical
Sciences, New Delhi-29
Phone: 011-29575408,
919968722016
E-mail:
pranaytanwar@gmail.com

Mucinous carcinoma of the breast in pure form comprises only 2% of all breast cancers. Pure mucinous carcinoma of the breast have better prognosis. They are usually having higher incidence in peri-menopausal and post-menopausal age group. We report a 32-year-old female, clinically suspected to have benign breast disease, diagnosed as mucinous carcinoma of the breast on FNAC. In such cases, there is always a high probability of missing the diagnosis at imaging because of the absence of established radiological signs of malignancy such as calcification and spiculation. In this case imaging was not helpful and diagnosis was ascertained by FNAC. This case further strongly substantiates, Fine needle aspiration cytology as rapid , highly sensitive and highly specific diagnostic investigation of choice for management of breast lumps .

Key words: FNAC, Mucinous carcinoma

*“Benign history may not
always yield benign
lumps”*

INTRODUCTION

Breast cancer is a cause of increasing concern for the health professionals. There are recent studies from developed nations, which have shown improvement in the mortality trends as a consequence of optimal execution of screening programs.⁽¹⁾ In developing nations like India, any improvement in mortality or morbidity indicators reflects more contribution of rapid and correct diagnosis with standard clinical management. FNAC has always been a very effective, rapid, highly sensitive and specific diagnostic modality for the diagnosis breast lump.

Mucinous carcinoma of breast is also called as "Colloid carcinoma" which is relatively rare neoplasm compared to usual ductal carcinoma of breast. Mucinous carcinoma accounts for only 2% of all breast cancers.^(2, 3) The age related incidence in women's less than 35 years age is only 1%.⁽⁴⁾ These carcinomas have relatively better prognosis.^(3, 5) There is paucity of published literature due to its rare incidence in younger age group of less than 35 years. Here, we are reporting a case of mucinous carcinoma of breast which is rare in young females. The case is interesting in a way that because in this age group, it is usually benign breast diseases which presents commonly as discrete mobile lump in breast. The final FNAC diagnosis of mucinous carcinoma sensitizes us to keep other relatively rare differential diagnosis also under consideration.

CASE REPORT

A 32-year-old female presented with a firm lump in upper outer quadrant of right breast for 2 months, which was gradually increasing in size and was associated with pain. The lump measured 3.5X2.5 cm and was freely mobile and not fixed to the underlying structures. The overlying skin was normal and nipple was not retracted. No axillary lymph node were palpable. The clinical diagnosis of

fibroadenoma right breast was proposed. Mammography was equivocal. FNAC of mass was advised.

Fine needle aspiration was done from right breast mass. Smears showed abundant pink mucoid material (Fig. 1). There were numerous minimally pleomorphic epithelial cells with bland chromatin (Fig. 2) lying either discretely forming loose clusters or entrapped within mucin. At places, the cells were forming ill-defined gland like structures. Mitotic figures were also seen occasionally. The cytological findings were suggestive of mucinous carcinoma. The patient also underwent core biopsy and diagnosis was subsequently confirmed on histopathology. Later patient was counselled to further surgical management.

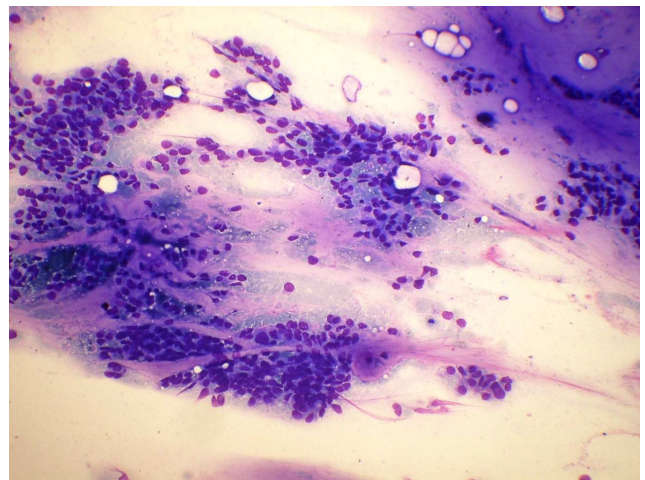


Fig. 1: FNA smear showing extracellular mucin along with entrapped malignant ductal cells (Giemsa, 400)

DISCUSSIONS

Mucinous carcinoma of breast has been reported in all age groups. Earlier studies have reported the incidence more in perimenopausal and postmenopausal age group^{2,3}. However, we are reporting a case of mucinous carcinoma in a young

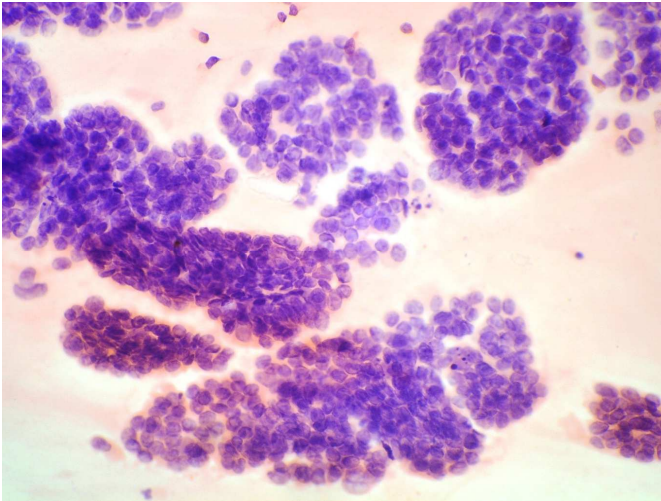


Fig.2: FNA Smears showing minimally pleomorphic cells with bland chromatin (H&E, 400)

female aged 32 years which is rare. One case study was published recently with similar profile from India⁶.

Mucinous carcinoma present as palpable discrete lump in breast clinically mimicking fibroadenoma. Pure mucinous carcinoma usually show ill-defined lobulated mammographic and sonographic margins⁷. Mammographic calcifications are absent in the majority (82%)⁷. Infiltrative ductal carcinomas usually have the mucin component in varying percentages of total tumor mass. Pure mucinous carcinomas of breast are categorically those breast tumors having >90% mucin component⁸ while mixed mucinous tumor can have mucin <90% of the total tumor mass⁸. These are divided in pure and mixed variants of mucinous carcinoma^{3,5}. These tumor are considered to have low growth rate and has less probability of metastasis into local draining lymph nodes,⁹ when compared to usual infiltrating ductal carcinoma(IDC). They are considered as good prognostic tumor with 90% cases with 10 years survival⁵.

Mucinous carcinoma are further categorised as cellular and hypocellular variant. The mucinous carcinoma is usually seen as component of

carcinoma is usually seen as component of infiltrating ductal carcinoma. Most mucinous carcinomas of the breast are oestrogen receptor positive, irrespective of whether they are pure or mixed type¹⁰. One of the study found mucinous carcinomas as ER/PR positive and having low S phase fraction of cell cycle when compared with age matched cases of IDC not otherwise specified(NOS)¹¹. In our case both ER and PR were positive.

Only 3-15% of pure variety shows axillary node metastasis compared to 33-46% of the mixed type^{5,12}. In the present case, there was no lymph node metastasis. Late distant metastases has also been reported in medical literature^{3,9}. The present case underwent surgical intervention and did not have any sign of recurrence till 3 months after the surgery. Now the index case is lost to follow up. Mucin secreted by such tumor is O-acylated forms of sialomucin¹³. The mucin secreted has been found to be positive for MUC 2 and low level of MUC 1¹⁴. A very small proportion (<5%) of Mucinous carcinoma has been showing positivity for MUC 5¹⁵. There is one study which has described endocrine differentiation of mucinous carcinoma of breast¹⁶. One of the study has reported mucinous cystadenocarcinoma which has atypical MUC positivity profile¹⁷.

CONCLUSION

In these circumstances, where there was no clue to diagnosis with help of clinical and radiologic imaging, FNAC was again proved as diagnostic modality of choice. The virtue of being rapid, sensitive and highly specific technique establishes this modality as investigation of choice for the management of breast lumps.

REFERENCES

1. Howlader N, Noone AM, Krapcho M et al (2012) SEER Cancer Statistics Review, 1975– 2009. National Cancer Institute, Bethesda.
2. Scoopsi L, Andreola S, Pillotti S, et al. Mucinous carcinoma of the breast. A clinicopathologic, histochemical, and immunocytochemical study with special reference to neuroendocrine differentiation. *Am J Surg Pathol* 1994;18:702-711.
3. Toikkanen S, Kujari H., Pure and mixed mucinous carcinoma of the breast: a clinicopathologic analysis of 61 cases with long-term follow-up. *Hum Pathol* 1989;20:758-64.
4. Cardenosa G, Doudna C, Eklund GW. Mucinous (colloid) breast cancer: clinical and mammographic findings in 10 patients. *AJR* 1994; 162: 1077–1079.
5. Komaki K, Sakamoto G, Sugano H, et al. Mucinous carcinoma of the breast in Japan. A prognostic analysis based on morphologic features. *Cancer* 1988;61:989-996.
6. Sharma S, Bansal R, Khare A, et al. Mucinous carcinoma of breast: Cytodiagnosis of a case. *J Cytol* 2011;28:42-44.
7. Tan JZ, Waugh J, Kumar B et al, Mucinous carcinomas of the breast: Imaging features and potential of misdiagnosis. *J Med Imaging Radiat Oncol*. 2013 Feb;57(1):25-31.
8. Ranade A, Batra R, Sandhu G, et al. Clinicopathological evaluation of 100 cases of mucinous carcinoma of breast with emphasis on axillary staging and special reference to a micropapillary pattern. *J Clin Pathol* 2010; 63: 1043–1047.
9. Clayton F. Pure mucinous carcinomas of breast: morphologic features and prognostic correlates. *Hum Pathol* 1986; 17:34-38.
10. Shousha S, Coady AT, Stamp T, et al. Oestrogen receptors in mucinous carcinoma of the breast: an immunohistological study using paraffin wax sections. *J Clin Pathol* 1989;42:902-905.
11. Diab SG, Clark GM, Osborne CK, et al. Tumor characteristics and clinical outcome of tubular and mucinous breast carcinomas. *J Clin Oncol* 1999;17:1442-1448.
12. Anan K, Mitsuyama S, Tamae K, et al. Pathological features of mucinous carcinoma of the breast are favorable for breast-conserving therapy. *Eur J Surg Oncol* 2001;27:459-463.
13. Saez C, Japon MA, Poveda MA, et al. Mucinous (colloid) adenocarcinomas secrete distinct O-acylated forms of sialomucins: a histochemical study of gastric, colorectal and breast adenocarcinomas. *Histopathology* 2001;39:554-560.
14. Hanski C, Hofmeier M, Schmitt-Gräff A, et al. Overexpression or ectopic expression of MUC2 is the common property of mucinous carcinomas of the colon, pancreas, breast, and ovary. *J Pathol*.1997; 182:385–391.
15. Matsukita S, Nomoto M, Kitajima S, et al. Expression of mucins (MUC1, MUC2, MUC5AC and MUC6) in mucinous carcinoma of the breast: comparison with invasive ductal carcinoma. *Histopathology*. 2003; 42:26–36.
16. Fisher ER, Palekar AS. Solid and mucinous varieties of so-called mammary carcinoid tumors. *Am J Clin Pathol* 1979; 72:909-916.
17. Sung EK, Ji HP, SnowWon H et al. Primary Mucinous Cystadenocarcinoma of the Breast: Cytologic Finding and Expression of MUC5 Are Different from Mucinous Carcinoma. *Korean J Pathol*. 2012 December; 46(6): 611–616.