

# Peritoneal rent: No hindrance to completing eTEP



Srishti Swarupa<sup>1</sup>, Vikeerna Bharti<sup>2</sup>, Leesa Misra<sup>3</sup>, Nivedita Sahoo<sup>4</sup>, Manash Ranjan Sahoo<sup>5</sup>, Sreeparna Ghosh<sup>6</sup>

<sup>1,6</sup>Intern, Department of Prosthodontics, Kalinga Institute of Dental Sciences, KIIT, <sup>2</sup>Senior Resident, <sup>5</sup>Professor and Head, Department of General Surgery, AIIMS, Bhubaneswar, <sup>3</sup>Professor and Head, Department of Obstetrics and Gynaecology, J K Medical College, Jajpur, <sup>4</sup>Professor, Department of Orthodontics and Dentofacial Orthopedics, Kalinga Institute of Dental Sciences, KIIT, Bhubaneswar, Odisha, India

Submission: 15-01-2023

Revision: 24-12-2023

Publication: 01-02-2024

## ABSTRACT

**Background:** Extended view total extraperitoneal (eTEP) has rapidly gained popularity over the last decade. Peritoneal rent during surgery is another complication that makes surgery difficult and forces surgeons to convert to either transabdominal pre-peritoneal or open hernioplasty. With our approach despite peritoneal rent developed intraoperatively, surgery can be completed in the same extraperitoneal plane during eTEP. **Aims and Objectives:** The primary objective of this study was to investigate the feasibility of completing eTEP surgery despite the occurrence of peritoneal rent during the procedure. **Materials and Methods:** It is a retrospective case series conducted at high volume center, All India Institute of Medical Science, Bhubaneswar, where eTEP is performed on regular basis for patients with inguinal hernia. While performing eTEP, we came across 10 cases where peritoneal rent developed intraoperatively and was repaired using 2–0 vicryl following which eTEP was successfully completed. **Results:** Six patients out of 10 underwent peritoneal rent repair through the extraperitoneal approach, with an average operative time of 97.5 min. The repair process added an average of 12.5 min to the standard eTEP operative time of 85 min. Four patients underwent peritoneal rent repair through the intraperitoneal approach, with a mean operative time of 120 min. This approach added approximately 35 min to the surgery, reflecting the additional time required for the intraperitoneal repair. **Conclusion:** Our findings suggest that peritoneal rent developed during eTEP surgery can be effectively managed without compromising the integrity of the procedure. Repairing the peritoneal rent extraperitoneally takes advantage of the wide extraperitoneal space provided by the eTEP approach, offering flexibility in port placement and enhanced ergonomics. Alternatively, intraperitoneal repair with additional ports is a viable option. Peritoneal rent should not be perceived as a hindrance to the successful completion of eTEP surgery. This innovative approach expands the scope of eTEP by providing solutions for unforeseen complications, ensuring its continued efficacy in inguinal hernia repair.

**Key words:** Extended view total extraperitoneal; Peritoneal rent; Inguinal hernia

## INTRODUCTION

Extended view total extraperitoneal (eTEP) is a modification of TEP proposed by Dr. Jorge Daes in 2012, and the procedure has rapidly gained popularity making it a new era in hernia surgery.<sup>1</sup> eTEP offers large extraperitoneal space with an extended operative field and flexibility in port positioning. Due to these advantages, more

and more surgeons are opting for the technique and it has become the first choice of trainee surgeons to enter the field of endoscopic hernia surgery. However, misinterpreting myofascial anatomy during dissection often leads to peritoneal injury and pneumoperitoneum making surgery cumbersome.<sup>2</sup> Following peritoneal rent, pneumoperitoneum develops leading to a decreased operative field, and surgeons are left with either converting

### Access this article online

**Website:**

<http://nepjol.info/index.php/AJMS>

**DOI:** 10.3126/ajms.v15i2.51501

**E-ISSN:** 2091-0576

**P-ISSN:** 2467-9100

Copyright (c) 2024 Asian Journal of Medical Sciences



This work is licensed under a Creative Commons Attribution-NonCommercial 4.0 International License.

### Address for Correspondence:

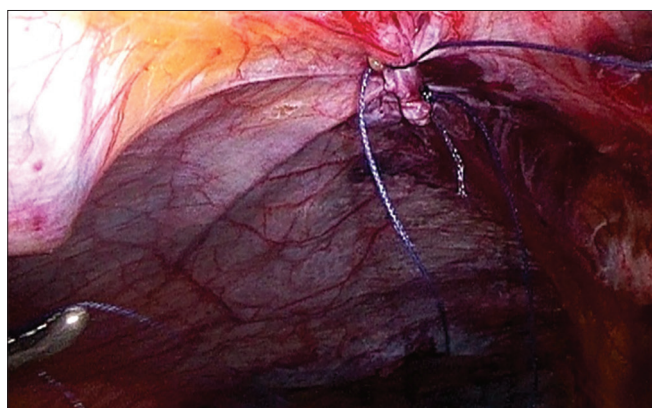Dr. Manash Ranjan Sahoo, Professor and Head, Department of General Surgery, AIIMS, Bhubaneswar, Odisha, India.

**Mobile:** +91-9937025779. **E-mail:** manash67@gmail.com

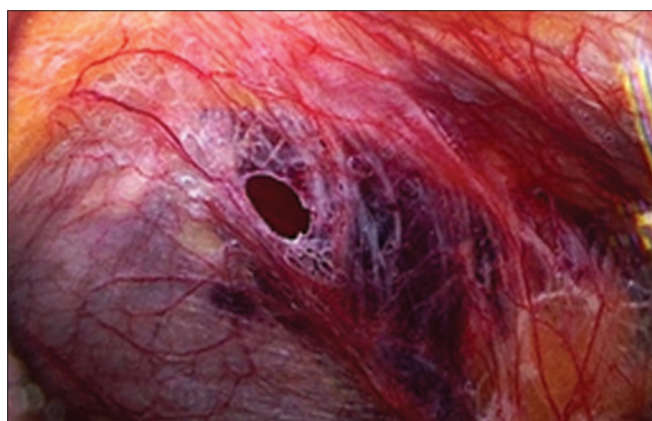
to transabdominal pre-peritoneal (TAPP) or open surgery. Our center All India Institute of Medical Science, Bhubaneswar, being a high-volume center and training center for minimal invasive surgery peritoneal rent during eTEP is no exception. Based on our experience, we offer two novel approaches following which peritoneal rent would not be a hindrance in completing eTEP.

### Aims and objectives

This study aims to investigate and optimize the management of peritoneal rent encountered during the extended view total extraperitoneal (eTEP) approach for inguinal hernia repair. The primary objective is to assess the feasibility and efficacy of intraoperative repair of peritoneal rent within the extraperitoneal space. Secondary objectives include determining the incidence and risk factors associated with peritoneal rent, comparing outcomes between extraperitoneal and intraperitoneal repair approaches, evaluating the impact on operative time and additional resources, assessing postoperative complications, and conducting a comparative analysis with standard eTEP procedures. The study seeks to provide evidence-based insights to enhance the safety and efficacy of eTEP surgery and contribute to the ongoing evolution of minimally invasive hernia repair techniques.



**Figure 1:** Intraoperative peritoneal rent



**Figure 2:** Repaired peritoneal rent

## MATERIALS AND METHODS

We present a case series of 10 patients of age group 26 years–62 years with inguinal hernia. All patients with unilateral and bilateral hernias while undergoing eTEP developed peritoneal rent during dissection. Intraoperatively, peritoneal rent was repaired and surgery proceeded in the same plane, i.e., extraperitoneal space. We used two approaches to peritoneal rent repair (Figures 1 and 2).

### Extraperitoneal approach

- When a peritoneal rent occurred, an additional 5-mm trocar was inserted into the lateral flank within the peritoneal cavity to facilitate desufflation, accompanied by an increased flow rate of CO<sub>2</sub>.
- If the peritoneal rent was situated away from the working port, allowing for triangulation, repair was conducted with 2–0 vicryl within the extraperitoneal space.
- Six patients underwent peritoneal rent repair through the extraperitoneal approach, with an average operative time of 97.5 min.
- The repair process added an average of 12.5 min to the standard eTEP operative time of 85 min.

### Intraperitoneal approach

- In cases where extraperitoneal closure was technically challenging, the intraperitoneal approach was implemented.
- An additional supraumbilical camera port was placed, along with an extra working port inserted intraperitoneally to achieve triangulation for repair.
- Peritoneal rent closure with 2–0 vicryl was successfully performed intraperitoneally.
- Four patients underwent peritoneal rent repair through the intraperitoneal approach, with a mean operative time of 120 min.
- This approach added approximately 35 min to the surgery, reflecting the additional time required for the intraperitoneal repair.
- Notably, in all cases adopting the intraperitoneal approach, initial attempts were made to repair the peritoneal rent extraperitoneally. The decision to proceed with the intraperitoneal approach was made only if the extraperitoneal repair was deemed unfeasible, explaining the additional 35 min in intraoperative time.

## RESULTS

A total of 10 patients with inguinal hernias, aged between 26 and 62 years, were included in this case series (Table 1). All patients underwent the eTEP procedure and experienced peritoneal rent during dissection. Peritoneal rent repair was successfully performed intraoperatively, allowing for the

**Table 1: Details of patients with operative time and approach by which rent was repaired**

Age	Sex	BMI	Inguinal hernia side	Rent repaired	Operative time
26	M	18	Right	Intraperitoneal	130 min
28	F	24	Right	Extraperitoneal	85 min
30	F	23	Left	Extraperitoneal	100 min
33	M	24	Left	Intraperitoneal	125 min
36	M	28	Left	Extraperitoneal	80 min
43	M	29	Right	Intraperitoneal	110 min
51	M	32	B/L	Extraperitoneal	120 min
54	F	29	Right	Extraperitoneal	90 min
60	F	23	Right	Intraperitoneal	115 min
62	M	24	B/L	Extraperitoneal	110 min

BMI: Body mass index

continuation of surgery within the extraperitoneal space. Two distinct approaches, namely the extraperitoneal and intraperitoneal approaches, were employed for peritoneal rent repair.

### Extraperitoneal approach

- Patients: Six patients underwent peritoneal rent repair through the extraperitoneal approach.
- Operative time: The average operative time for these cases was 97.5 min.
- Time added: The repair process using the extraperitoneal approach added an average of 12.5 min to the standard eTEP operative time of 85 min.

### Intraperitoneal approach

- Patients: Four patients underwent peritoneal rent repair through the intraperitoneal approach.
- Operative time: The mean operative time for cases utilizing the intraperitoneal approach was 120 min.
- Time added: The intraperitoneal approach added approximately 35 min to the surgery, representing the extra time required for intraperitoneal repair. It is noteworthy that this additional time was attributed to the attempt of extraperitoneal repair before deciding to proceed with the intraperitoneal approach.

In all cases, regardless of the approach, peritoneal rent repair allowed for the successful completion of the eTEP procedure. The choice between the extraperitoneal and intraperitoneal approaches depended on the location and technical feasibility of the repair. Notably, the majority of cases were resolved extraperitoneally, underscoring the advantages of the eTEP technique in managing peritoneal rent during inguinal hernia surgery.

## DISCUSSION

Following the pioneering work by Dr. Jorge Daes and the standardization of eTEP in an inguinal hernia, a new era of endoscopic hernia surgery has started.<sup>1</sup> eTEP offers a panoramic view of the operative field with flexibility in port positioning such that large, irreducible, and bilateral

inguinal hernia can also be dealt with ease.<sup>1</sup> TEP approach avoids entry into the abdominal cavity, lessening the risk of visceral injuries and trocar site hernias and the need for opening and closing the peritoneum.<sup>3</sup> For these reasons, TEP is clearly superior to TAPP. Following the modification of TEP and standardization of eTEP, more and more surgeons started opting for eTEP. Peritoneal rent is no exception during endoscopic hernia surgery. Since eTEP offers extensive extraperitoneal space for dissection along with flexibility in port position and greater ergonomics, the advantage can also be utilized for peritoneal rent repair.<sup>4</sup> Most cases peritoneal rent can be repaired in the same extraperitoneal space. During eTEP during ongoing dissection and development of peritoneal rent, conversion to TAPP or open surgery can be cumbersome as one has to change the plane of dissection by converting one procedure to another. If the extraperitoneal repair seems to be technically challenging, intraperitoneal repair can be tried by adding an additional port in the peritoneal cavity. Following repair surgery can be continued in the same extraperitoneal plane. For these procedures, we believe that surgeons should be proficient in laparoscopic suturing.

### Limitations of the study

This study has limitations, including a small sample size of 10 patients from a single center, limiting generalizability. The retrospective design introduces potential biases, and long-term follow-up data are insufficient for a comprehensive assessment of postoperative outcomes. Despite these constraints, the study provides initial insights, calling for larger, prospective investigations in the future.

## CONCLUSION

In most cases, peritoneal rent during eTEP can be repaired in the same extraperitoneal space during surgery. If not feasible, intraperitoneal repair can be done by placing an additional port in the peritoneal cavity. By doing this, eTEP can proceed successfully, so we believe that peritoneal rent is no longer a hindrance to completing eTEP.

## ACKNOWLEDGMENT

This study has limitations, including a small sample size of 10 patients from a single center, limiting generalizability. The retrospective design introduces potential biases, and long-term follow-up data are insufficient for a comprehensive assessment of postoperative outcomes. Despite these constraints, the study provides initial insights, calling for larger, prospective investigations in the future.

## REFERENCES

1. Daes J. The enhanced view-totally extraperitoneal technique for repair of inguinal hernia. *Surg Endosc.* 2012;26(4):1187-1189.
2. Mahadar R and Arora E. Trocar insertion in enhanced-view totally extra-peritoneal (eTEP) repair of inguinal hernias. *J Minimal Access Surg.* 2021;17(4):580-583. [https://doi.org/10.4103/jmas.JMAS\\_312\\_20](https://doi.org/10.4103/jmas.JMAS_312_20)
3. Wake BL, McCormack K, Fraser C, Vale LD, Perez J and Grant AM. Transabdominal pre-peritoneal (TAPP) vs totally extraperitoneal (TEP) laparoscopic techniques for inguinal hernia repair. *Cochrane Database Syst Rev.* 2005;25(1): CD004703. <https://doi.org/10.1002/14651858.CD004703.pub2>
4. Daes J. Minimally invasive surgical techniques for inguinal hernia repair: The extended-view totally extraperitoneal approach (eTEP). In: Davis S Jr., Dakin G, Bates A, editors. *The SAGES Manual of Hernia Surgery.* Cham: Springer; 2019. [https://doi.org/10.1007/978-3-319-78411-3\\_33](https://doi.org/10.1007/978-3-319-78411-3_33)

### Authors Contribution:

**LM-** Concept, design, clinical protocol, design of study, statistical analysis and interpretation; **VB-** Definition of intellectual content, literature survey, prepared first draft of manuscript, implementation of study protocol, data collection, data analysis, manuscript preparation and submission of article, manuscript preparation, editing, and manuscript revision; **MRS-** Concept, design, clinical protocol, design of study, statistical analysis and Interpretation, coordination and manuscript revision; **SS-** Data collection, data analysis, manuscript preparation; **NS-** Data collection, data analysis, manuscript preparation; **SG-** Data collection, data analysis, manuscript preparation.

### Work attributed to:

All India Institute of Medical Science, Bhubaneswar, India.

### Orcid ID:

Dr. Leesa Misra - <https://orcid.org/0000-0002-7133-9250>  
Dr. Vikeerna Bharti - <https://orcid.org/0000-0002-0344-1229>  
Dr. Manash Ranjan Sahoo - <https://orcid.org/0000-0001-7275-0116>  
Dr. Srishti Swarupa - <https://orcid.org/0009-0009-6289-6432>  
Dr. Nivedita Sahoo - <https://orcid.org/0000-0003-1125-2863>  
Dr. Sreeparna Ghosh - <https://orcid.org/0009-0005-1108-5067>

**Source of Support:** Nil, **Conflicts of Interest:** None declared.