

# Concomitant chemoradiotherapy, brachytherapy, and parametrial boost versus concomitant chemoradiation and brachytherapy alone in locally advanced cervical carcinoma: A prospective and comparative study



Saptarshi Banerjee<sup>1</sup>, Chandrima Banerjee<sup>2</sup>, Sharmistha Daripa<sup>3</sup>, Swaralipi Misra<sup>4</sup>, Srikrishna Mandal<sup>5</sup>, Paramita Chatterjee<sup>6</sup>, Anjan Bera<sup>7</sup>

<sup>1</sup>Assistant Professor, Department of Radiotherapy, Medical College and Hospital, <sup>2</sup>Assistant Professor, Department of Radiotherapy, IPGMER and SSKM Hospital, Kolkata, <sup>3</sup>RMO Cum Clinical Tutor, Department of Radiotherapy, College of Medicine and Sagore Dutta Hospital, Kolkata, <sup>4</sup>RMO Cum Clinical Tutor, Department of Gynecology and Obstetrics, College of Medicine and JNM Hospital, Kalyani, <sup>5</sup>Professor, <sup>7</sup>Associate Professor, Department of Radiotherapy, NRS Medical College and Hospital, <sup>6</sup>Lecturer, Department of Botany, Bangabasi Morning College, Kolkata, West Bengal, India

Submission: 28-11-2022

Revision: 28-02-2023

Publication: 01-04-2023

## ABSTRACT

**Background:** The inherent property of brachytherapy is its steep dose gradient and parametrium, near the pelvic wall, which gets little contribution in dose from brachytherapy. As parametria are the common sites for treatment failure, parametrial boost (PMB) may increase the disease control in case of locally advanced cervical carcinomas after 45–50 Gy of external-beam radiotherapy (EBRT) to the whole pelvis. **Aims and Objectives:** This study aimed to find whether a satisfactory control of the parametrial disease can be achieved with acceptable toxicity. **Materials and Methods:** Between December 2014 and December 2017, 92 patients were treated by concomitant chemoradiation with whole pelvic EBRT of 50 Gy in 25 fractions and weekly Cisplatin (40 mg/m<sup>2</sup>) followed by brachytherapy. Out of 89 patients, 46 patients were given an additional PMB of 10 Gy in five fractions and 46 were given no boost. **Results:** The local control of the disease in terms of CR or PR was comparable in the two arms (i.e., with or without PMB), with  $P=0.542$ . The central recurrences between the two arms were also comparable, 13.9% without PMB, and 9.76% with PMB,  $P=0.726$ . When parametrial recurrence is concerned, there were four parametrial recurrences (11.11%) in the arm without boost, in comparison to no parametrial recurrence (0%) in the boost arm, and this was statistically significant ( $P=0.044$ ). **Conclusion:** In locally advanced carcinoma cervix patients, in terms of parametrial recurrence, this study showed a significant clinical benefit of an additional external beam PMB.

**Key words:** Concomitant chemoradiation; Brachytherapy; Parametrial boost

## INTRODUCTION

Squamous cell carcinoma cervix is one of the leading causes of death among women, worldwide, especially in developing countries. According to GLOBOCAN 2020, the total number

of cases of cervical cancer worldwide was 6,04,127, among which India contributed 1,23,907 cases.<sup>1,2</sup> The treatment of carcinoma cervix mainly depends on its stage. Treatment of locally advanced carcinoma cervix is mainly dependent on radiation therapy, in the form of the external beam external

### Access this article online

#### Website:

<http://nepjol.info/index.php/AJMS>

DOI: 10.3126/ajms.v14i4.49872

E-ISSN: 2091-0576

P-ISSN: 2467-9100

Copyright (c) 2023 Asian Journal of Medical Sciences



This work is licensed under a Creative Commons Attribution-NonCommercial 4.0 International License.

### Address for Correspondence:

Dr. Anjan Bera, Associate Professor, Department of Radiotherapy, NRS Medical College and Hospital, Kolkata-14, West Bengal, India.  
Mobile: +91-8336855482. E-mail: [anjanbera78@gmail.com](mailto:anjanbera78@gmail.com)

beam radiotherapy (EBRT), and brachytherapy. External irradiation is used to treat the whole pelvis and the parametria including the common iliac and para-aortic lymph nodes, whereas central disease (cervix, vagina, and medial parametria) is primarily irradiated with intra-cavitary brachytherapy sources. Treatment of locally advanced cervical cancer implies dealing with a large tumor burden distributed not only centrally but also laterally up to or near the lateral pelvic wall. Hence, successful tumor control requires the delivery of adequate doses to central as well as parametrial disease. This can be achieved by pelvic external beam radiation with concurrent chemotherapy and additionally intracavitary brachytherapy to boost the central disease.

However, the inherent property of brachytherapy is its steep dose gradient. Hence, parametrium, near the pelvic wall gets little contribution in dose from brachytherapy. Here lies the question of delivering an additional dose to the parametria (parametrial boost [PMB]). When gross parametrial tumor persists after 45–50 Gy of EBRT to the whole pelvis, an additional dose of 10 Gy may be delivered by PMB.<sup>3</sup> PMB is one of the under-explored areas of radiation therapy. There are not many studies on the PMB to date. As parametria are the common sites for treatment failure,<sup>4</sup> PMB may increase the disease control in case of locally advanced cervical carcinomas. In addition, this PMB may have a satisfactory result in controlling the parametrial disease but may also increase toxicity.

### Aims and objectives

This study aimed to find whether a satisfactory control of the parametrial disease can be achieved with acceptable toxicity.

## MATERIALS AND METHODS

After obtaining clearance from the Institutional Ethical Committee (MEMO NO. Inst-IEC/1395, dated January 07, 2013) previously untreated, histologically proven locally advanced squamous cell carcinoma of the cervix patients, attending the outpatient department of our radiotherapy department were screened by inclusion and exclusion criteria and randomized into two arms on a 1:1 ratio. The study period of this prospective and comparative study was between January 2013 and December 2016.

### Inclusion criteria

The following criteria were included in the study:

1. Age: Above 20 years. and not more than 70 years
2. Performance status: up to ECOG-3
3. Histologically proved squamous cell carcinoma of the cervix
4. Stage: Locally advanced-FIGO stage IIB-IVA with bilateral parametrial involvement

5. Without any severe systemic comorbidity or uncontrolled severe hematological abnormality.

### Exclusion criteria

The following criteria were excluded from the study:

1. Age: Above 70 years and below 20 years
2. Performance status: poorer than ECOG-3
3. Stage: Early-stage disease (FIGO- IA -IIA) and metastatic disease
4. Unilateral parametrial involvement
5. Histologically any other than squamous cell carcinoma
6. Previously treated with any type of radiation or chemotherapy
7. Any severe systemic comorbidity or severe uncontrolled hematological abnormality.

Arm 1 (without PMB) – Patients were treated by EBRT (Cobalt<sup>60</sup>) to the whole pelvis up to a dose of 50 Gy in 25 fractions over 5 weeks, along with weekly concomitant Cisplatin (40 mg/m<sup>2</sup>), and HDR Intra-Cavitary Brachytherapy (by Iridium<sup>192</sup>) to deliver 21 Gy to point A in three fractions (7 Gy/fraction). Arm 2 (with PMB) – In addition to the above-mentioned treatment, a PMB of 10 Gy in five fractions had been given. To keep the total treatment time within 8 weeks (as recommended by the American Brachytherapy Society), brachytherapy was interdigitated with a PMB.

### External beam planning

Beam used: Co<sup>60</sup>.

Patient position: Supine.

Radiation portals: (4-field techniques).

AP-PA portals:

- Superior border: L4-L5 interspace. (L3-L4 if common iliac nodes were taken)
- Inferior border: Below the Obturator foramina or 2 cm below the lower disease extension in the vagina
- Lateral border: 1.5–2 cm lateral to the pelvic brim

Lateral Portals:

- Superior/Inferior borders: same as AP-PA portals
- Anterior border: Anterior to Pubis Symphysis
- Posterior border: S2-S3 intervertebral space.

Dose: 50 Gy to the whole pelvis in 25 fractions (2 Gy/fraction) in 5 weeks.

### Brachytherapy planning

For all applications, individualized and computerized planning was performed with the help of our physicists by image-guided brachytherapy planning software. Before accepting a plan for the execution of treatment, the

following parameters were checked and recorded: (1) Isodose distribution, (2) width of reference isodose, and (3) ICRU point A, point B, rectal point, and bladder point doses. The dose of HDR-brachytherapy was 7 Gy/fraction for three fractions to a total of 21 Gy to point A. As mentioned previously, to keep the total treatment time within 8 weeks (as recommended by the American Brachytherapy Society), brachytherapy was interdigitated with PMB in the boost arm.

### PMB planning

All patients of ARM B received a PMB, which was delivered by EBRT. The parametrium so far received 50 Gy from whole pelvic RT and an additional dose of ~ 10 Gy/5 #/1 week, to make up the total dose to at least 60 Gy.

The prescribed dose was 10 Gy in 5 fractions over 1 week.

### Radiotherapy portals

A PMB was delivered with reduced AP-PA portals.

- Superior border: L5-S1 junction
- Inferior border: Lower margin of the obturator foramen
- Lateral border: As whole pelvic RT field.

### Midline shield

The measurement of the shield was customized according to the need of the particular case. The height of the shield was the same as the boost field height. The width of the shield depended on the width of the brachytherapy reference isodose.

### Data collection and analysis

From January 2013 to December 2016, according to inclusion and exclusions criteria, as mentioned earlier, a total of 92 histologically proven cervical cancer patients were included in this prospective and comparative study. The response, toxicities, and pattern of recurrence were studied and compared between the two arms. The data were analyzed with appropriate statistical tests, such as Chi-square Test/Fisher's test, and Student-t-test.

## ETHICAL APPROVAL AND CONSENT TO PARTICIPATE

Before starting this prospective study clearance from the institutional ethical committee (IEC, Memo no-Inst/IEC-1395, dated-07/01/2013) and all the patients have given consent to participate in this study.

## RESULTS

Ninety-two cervical cancer patients with FIGO Stages IIB to IVA were eligible for inclusion in the study. They were

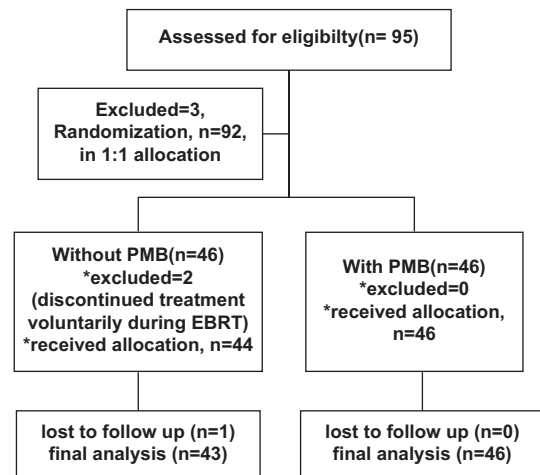


Figure 1: Consort flow chart showing the study protocol

randomized into two arms containing an equal number of patients in both arms, n=46. The CONSORT flow chart describes the study design (Figure 1). However, 89 patients were eligible for the final analysis. Arm 1 contained 43 patients and Arm 2 contained 46 patients.

The mean age of patients was  $56.07 \pm 6.76$  years and  $55.43 \pm 6.78$  years was 1 and Arm 2 respectively, the  $P=0.659$ . Among 89 total patients, 36 (40.4) and 46 (51.7%) were of FIGO Stage IIB, IIIA, and IIIB, respectively. There was no Stage IVA patient. Stage-wise distribution was also comparable among the two arms ( $P=0.499$ ). The grade or differentiation of disease [well-differentiated, moderately differentiated, or poorly differentiated (PD)] was comparable in the two arms ( $P=0.717$ ). The mean months of follow-up were  $9.12 \pm 2.3$  months and  $8.63 \pm 2.1$  months in arm 1 and arm 2, respectively ( $P=0.309$ ) (Table 1). The baseline profiles including time follow-up were comparable in both the arms and details depicted in Table 1.

### Response assessment

Responses of the two arms were evaluated according to RECIST criteria. There was a total of 177 CRs and 12 PRs, with no SD or PD.  $P=0.542$  suggests that there was no significant difference in the responses of the two arms (Table 2).

### Central recurrence

Among 77 patients with CR, central recurrence occurred in 10 patients. Among those 10 patients, six were from arm 1 and four were from arm 2 ( $P=0.726$ ).

### Parametrial recurrence

During the follow-up of patients with CR, parametrial recurrences were observed in only four patients. All four patients were from arm 1, that is, arm without PMB. No parametrial recurrence was observed in arm 2 (with PMB).

**Table 1: Comparison of baseline characteristics, WD, MD, and PD**

Parameter	Arm 1				Arm 2				P-value
Age (Mean±SD)	56.07±6.76				55.43±6.78				0.659
FIGO stage	IIB	IIIA	IIIB	Total	IIB	IIIA	IIIB	Total	0.499
	15	3	25	43	21	4	21	46	
Differentiation	WD	MD	PD	Total	WD	MD	PD	Total	0.717
	6	34	3	43	4	38	4	46	
Months of follow-up (Mean±SD)	9.12±2.3				8.63±2.1				0.309

WD: Well differentiated, MD: Moderately differentiated, PD: Poorly differentiated

**Table 2: Comparison of responses; CR, PR**

Arm	Tumor response		Total	P-value
	CR (%)	PR (%)		
1	36 (83.7)	7 (16.3)	43	0.542
2	41 (89.1)	5 (10.9)	46	
Total	77 (86.5)	12 (13.5)	89	

CR: Complete response, PR: Partial response

**Table 3: Comparison of central and parametrial recurrences**

Central recurrence				
Arm	Yes (%)	No (%)	Total	P-value
1	5 (13.9)	31 (86.1)	36	0.726
2	4 (9.76)	37 (90.24)	41	
Parametrial recurrence				
Arm	Yes (%)	No (%)	Total	P-value
1	4 (11.11)	32 (88.89)	36	0.044
2	0 (0)	41 (100)	41	

The percentage of parametrial recurrence was higher in the arm without PMB, and the difference was statistically significant, (P=0.044) (Table 3).

### Toxicity analysis

Toxicity analysis had been done using RTOG/EORTC radiation toxicity criteria. Both acute and late toxicities were studied. It was observed that acute skin toxicities and hematological toxicities were comparable in the two arms. Acute bladder toxicities were slightly higher in the arm with PMB, but the difference was not statistically significant. Although the acute lower GI toxicities were higher in the PMB arm, it was not statistically significant (P=0.199) (Table 4). The late toxicity of skin was comparable between the arms. G1 skin toxicities were present in 20.9% of cases without PMB and 23.9% of cases with PMB. Late lower GI toxicity was a bit higher in the PMB arm. G1 lower GI toxicity was present in 10.9% and 7% of cases with and without PMB, respectively. Late G1 bladder toxicity was present in 2.3% of cases without PMB, and in 6.5% of cases with PMB. The differences in late lower GI and bladder toxicities were not statistically significant (Table 5).

**Table 4: Comparison of acute toxicities**

Acute Toxicities	Arm 1 (n=43) (%)		Arm 2 (n=46)		P-value
Skin toxicities					
G-0	10	23.26	10	21.7	0.747
G-1	31	72.09	32	69.6	
G-2	2	4.65	4	8.7	
Lower GI toxicities					
G-0	33	76.7	26	56.5	0.199
G-1	7	16.3	12	26.1	
G-2	3	7	7	15.2	
G-3	0	0	1	2.2	
Bladder toxicities					
G-0	40	93	40	86.96	0.496
G-1	3	7	5	10.87	
G-2	0	0	1	2.17	
Hematological					
G-0	30	69.77	32	69.6	0.995
G-1	8	18.61	8	17.4	
G-2	4	9.30	5	11	
G-3	1	2.32	1	2	

GI: Gastrointestinal, G: Grade

**Table 5: Comparison of late toxicities**

Late toxicities	Arm 1		Arm 2		P-value
Skin					
G-0	34	79.1%	35	76.1%	0.803
G-1	9	20.9%	11	23.9%	
Lower GI					
G-0	39	90.7%	39	84.8%	0.693
G-1	3	7%	5	10.9%	
G-2	1	2.3%	2	4.3%	
Bladder					
G-0	42	97.7%	43	93.5%	0.617
G-1	1	2.3%	3	6.5%	

GI: Gastrointestinal, G: Grade

## DISCUSSION

In the case of locally advanced carcinoma cervix with parametrial involvement, delivering adequate tumoricidal dose to parametrium is a problem, as intracavitary brachytherapy obtains a steep dose fall-off in inverse square law. When parametrial tumor persists even after 50–60 Gy is delivered to the parametria, an additional 10 Gy in five or six fractions may be delivered with a reduced anteroposterior and



posteroanterior portal (8 by 12 cm for unilateral and 12 by 12 cm portals for bilateral parametrial coverage).<sup>3-5</sup> The central shield should be in place to protect the bladder and rectum.

In 2000, Chen et al., published results of definitive radiotherapy for cervix cancer in 128 patients. After EBRT with 40–44 Gy/20–22 fractions in 4–5 weeks to the whole pelvis, the dose was boosted up to 54–58 Gy with central shielding for patients with bilateral parametria of stage IIB or greater.<sup>6</sup> Gangopadhyay and Saha used a PMB of a dose of 9 Gy in 5 fractions after 50 Gy WPRT and CT-based HDR interstitial brachytherapy (18 Gy in 2 fractions), in IIB and IIIB patients with good tumor control and acceptable toxicity.<sup>7</sup> World literature contains an almost equal distribution of “PMB” and “no boost” for advanced cervix cancer. A list of even very recent publications where PMB was not given is not too short. Torres et al., from M D Anderson Cancer Center in their work on BEV-based 3 D treatment planning for locally advanced cervix cancer, where none of 20 patients (16 with IIB and four with even IIIB disease) received a PMB.<sup>8</sup> Viswanathan et al., and others from the Vienna group in their comparison of CT versus MRI-based contouring and DVH analysis (of both cervix and OARs), published in 2007, did not consider PMB for the enrolled patients with IIA and IIB cervix cancer.<sup>9</sup> The treatment protocol followed at the University of Vienna does not include a PMB for even IIIB patients.

In our study, all patients were treated by concomitant chemoradiation with whole pelvic EBRT of 50 Gy in 25 fractions and weekly Cisplatin (40 mg/m<sup>2</sup>) followed by brachytherapy. Forty-six patients were given an additional PMB of 10 Gy in five fractions and 43 were given no boost. The confounding factors, such as age distribution, stage distribution, grade-wise distribution, and mean time of follow-up, were comparable between the boost and no boost arm. The local control of the disease in terms of CR or PR was comparable in the two arms (i.e., with or without PMB), with a P = 0.542. The recurrences (central and parametrial) were studied in the two arms, though the median follow-up time for the study was only 8 months, which was not enough to assess the actual recurrence pattern. The central recurrences between the two arms were also comparable, 13.9% without PMB, and 9.76% with PMB, P=0.726. When parametrial recurrence is concerned, there were four parametrial recurrences (11.11%) in the arm without boost, in comparison to no parametrial recurrence (0%) in the boost arm, and this was statistically significant (P=0.044). Hence, in this study, the benefit was observed in the PMB arm, in terms of preventing parametrial recurrence.

In the question of acute toxicity, acute skin, bladder, and hematological toxicities were comparable between the two arms (statistically no significant difference). In the case of

acute lower GI toxicity, patients in the boost arm got more acute lower GI (mainly rectal) toxicity than the patients in the no-boost arm, but the apparent difference was not statistically significant (P=0.199). Regarding late toxicity assessment, the median follow-up time for the study (8 months) was also very short to assess late toxicities. In this short period of follow-up, the late lower GI, bladder, and skin toxicities were comparable in the two arms (P-values not significant). Interestingly, some studies in the literature where external beam PMB was employed showed significantly increased toxicity among treated patients. For example, the study by Huang et al., from Taiwan raised caution about more radiation proctitis in patients treated by external beam PMB.<sup>10</sup> On the contrary, the recent study by Khalid et al., showed good locoregional control in locally advanced carcinoma cervix with concurrent PMB along with chemoradiation with acceptable and comparable toxicity.<sup>11</sup> In our study, however, statistically equivalent toxicity was noted in both arms, whether treated with or without a PMB. It may be due to the matching of the medial border of the boost field with the brachytherapy reference isodose. The short follow-up period in this study (median 8 months) was probably one of the main reasons for not getting much more toxicities in the boost arm, as the literature shows that most post-radiotherapy toxicity in cervix cancer patients develop between 1.5 and 2.5 years.

This study also has some limitations. The median follow-up time of the study was not enough to study the late toxicity and also late recurrences properly. The sample size was not large enough to study the actual response, recurrence pattern, and pattern of toxicity. The patients of locally advanced cervix cancer with bilateral parametrial involvement were taken in this study, and patients with unilateral parametrial involvement were excluded from the study. Some contributing factors such as nutritional status and a fall in the quality of life are not adjusted for assessing the response rate and disease-free survival. Hence, the results may not represent the actual outcomes in the population at large.

#### Limitations of the study

Our study was single institutional and carried out in small number of patients. Hence may be not representative of whole population.

## CONCLUSION

This study intended to explore the outcome of an external beam PMB in addition to standard treatment in locally advanced cervix cancer. The tumor response in the form of complete or partial responses was equivalent in the two arms. When the recurrence pattern was studied, the arms were comparable for central recurrences. A statistically

significant benefit was observed in terms of parametrial recurrences in the PMB arm ( $P=0.044$ ) with comparable acute and late toxicity.

## ACKNOWLEDGMENT

We likewise acknowledge the contributions of Govt. West Bengal for supplying all treatment including chemotherapeutics free of cost and to their work by all junior residents, medical physicists, and all radiation technologists of our radiotherapy department.

## REFERENCES

1. Sung H, Ferlay J, Siegel RL, Laversanne M, Soerjomataram I, Jemal A, et al. Global cancer statistics 2020: GLOBOCAN estimates of incidence and mortality worldwide for 36 cancers in 185 countries. *CA Cancer J Clin.* 2021;71(3):209-249. <https://doi.org/10.3322/caac.21660>
2. Available from: <https://www.gco.iarc.fr/today/data/factsheets/populations/356-india-fact-sheets> [Last accessed on 2022 Jun 26].
3. Perez CA and Kavanagh BD. Uterine cervix. In: Perez CA, Brady LW, Halperin EC and Schmidt-Ulrich RK, editors. Principles and Practice of Radiation Oncology. Philadelphia, PA: Lippincott Williams & Wilkins; 2004. p. 1800-1915.
4. Wolfson AH, Abdel-Wahab M, Markoe AM, Raub WJ Jr., Diaz D, Desmond JJ, et al. A quantitative assessment of standard vs. Customized midline shield construction for invasive cervical carcinoma. *Int J Radiat Oncol Biol Phys.* 1997;37(1):237-242. [https://doi.org/10.1016/s0360-3016\(96\)00469-5](https://doi.org/10.1016/s0360-3016(96)00469-5)
5. Fenkell L, Assenholt M, Nielsen SK, Haie-Meder C, Pötter R, Lindegaard J, et al. Parametrial boost using midline shielding results in an unpredictable dose to tumor and organs at risk in combined external beam radiotherapy and brachytherapy for locally advanced cervical cancer. *Int J Radiat Oncol Biol Phys.* 2011;79(5):1572-1579. <https://doi.org/10.1016/j.ijrobp.2010.05.031>
6. Chen SW, Liang JA, Yang SN, Liu RT and Lin FJ. The prediction of late rectal complications following the treatment of uterine cervical cancer by high-dose-rate brachytherapy. *Int J Radiat Oncol Biol Phys.* 2000;47(4):955-961. [https://doi.org/10.1016/s0360-3016\(00\)00559-9](https://doi.org/10.1016/s0360-3016(00)00559-9)
7. Gangopadhyay A and Saha S. Individually customized parametrial boost for locally advanced cervical cancer: Is 2D planned external beam radiotherapy useful? *J Radiother Pract.* 2020;19(3):248-253. <https://doi.org/10.1017/S146039691900058X>
8. Torres MA, Jhingran A, Thames HD Jr., Levenback CF, Bodurka DC, Ramondetta LM, et al. Comparison of treatment tolerance and outcomes in patients with cervical cancer treated with concurrent chemoradiotherapy in a prospective randomized trial or with standard treatment. *Int J Radiat Oncol Biol Phys.* 2008;70(1):118-125. <https://doi.org/10.1016/j.ijrobp.2007.05.028>
9. Viswanathan AN, Dimopoulos J, Kiritsis C, Berger D and Pötter R. Computed tomography versus magnetic resonance imaging-based contouring in cervical cancer brachytherapy: Results of a prospective trial and preliminary guidelines for standardized contours. *Int J Radiat Oncol Biol Phys.* 2007;68(2):491-498. <https://doi.org/10.1016/j.ijrobp.2006.12.021>
10. Huang EY, Lin H, Hsu HC, Wang CJ, Chen HC, Sun LM, et al. High external parametrial dose can increase the probability of radiation proctitis in patients with uterine cervix cancer. *Gynecol Oncol.* 2000;79(3):406-410. <https://doi.org/10.1006/gyno.2000.5997>
11. Khalid M, Shah SI, Kanwal T and Nadeem K. Toxicity profile in cervical cancer patients receiving chemoradiation with concurrent parametrial boost. *Ann Punjab Med Coll.* 2012;6(1):9-12.

### Authors' Contributions:

**SB, CB, SWM, and SD**- Conceptualization, methodology, data collection, data interpretation, statistical analysis, writing, and reviewing of the final manuscript; **SRM and PC**- Conceptualization, methodology, statistical analysis, and reviewing the final manuscript; and **AB**- Conceptualization, methodology, data interpretation, writing of the manuscript, and reviewing of the final manuscript.

### Work attributed to:

Department of Radiotherapy, NRS Medical College and Hospital, Kolkata-14, West Bengal, India.

### Orcid ID:

Dr. Saptarshi Banerjee - <https://orcid.org/0000-0002-5784-6918>  
Dr. Chandrima Banerjee - <https://orcid.org/0000-0001-6262-2153>  
Dr. Sharmistha Dariipa - <https://orcid.org/0000-0002-1277-2679>  
Dr. Swaralipi Misra - <https://orcid.org/0000-0002-5775-3682>  
Prof. Srikrishna Mandal - <https://orcid.org/0000-0003-4403-2277>  
Dr. Paramita Chatterjee - <https://orcid.org/0000-0002-7346-6341>  
Dr. Anjan Bera - <https://orcid.org/0000-0003-1571-1449>

**Source of Support:** Nil, **Conflicts of Interest:** None declared.