

Brunner's Gland Lesions: An uncommon entity mimicking malignancy



Sarika More¹, Madhubala Swarnakar², Rajendra Kumar Chandrakar³, Manjula Lader⁴

¹Professor, Department of Pathology, RKDF Medical College, Hospital and Research Centre, Bhopal, Madhya Pradesh, India, ^{2,4}Assistant Professor, ³Professor, Department of Pathology, Shri Shankaracharya Institute of Medical Sciences, Bilhail, Chhattisgarh, India

Submission: 08-07-2022

Revision: 03-09-2022

Publication: 01-10-2022

ABSTRACT

Brunner's gland hyperplasia (BGH) or adenoma is an uncommon benign lesion which mimics malignancy in the duodenum. In the present study, five cases of BGH were reported, out of which one case was presented with large size measuring 5.54 × 4.05 cm, which has not been yet reported. Computed tomography demonstrated a large obstructing polypoidal mass, on esophagogastroduodenoscopy demonstrated polypoidal growth, and histologic examination revealed brunner's gland adenoma. Most of the cases presented with gastric outlet obstruction and upper gastrointestinal bleeding with other non-specific symptoms. BGH is an uncommon benign condition of the duodenum, patients were usually asymptomatic or may present with non-specific symptoms or present as an incidental finding on endoscopy. Endoscopic and/or surgical resection represents the ideal approach. Brunner's gland described by the Swiss anatomist Johann Conrad Brunner in 1688, predominantly present within the submucosa, begin just distal to the gastroduodenal junction, and gradually decrease in size and number distally and are often used as a histological marker of the duodenum. A Brunner's gland adenoma (BGA), also known as BGH or hamartoma, is an uncommon benign lesion in the duodenum.

Key words: Adenoma; Kocher maneuver; Whipple operation; Hamartoma

Access this article online

Website:

<http://nepjol.info/index.php/AJMS>

DOI: 10.3126/ajms.v13i10.46544

E-ISSN: 2091-0576

P-ISSN: 2467-9100

Copyright (c) 2022 Asian Journal of Medical Sciences



This work is licensed under a Creative Commons Attribution-NonCommercial 4.0 International License.

INTRODUCTION

Brunner's gland hyperplasia (BGH) or adenoma is an uncommon benign lesion which mimics malignancy in the duodenum. In the present study, five cases of BGH were reported, out of which one case was presented with large size measuring 5.54 × 4.05 cm, which has not been yet reported. Computed tomography (CT) demonstrated a large obstructing polypoidal mass, on esophagogastroduodenoscopy (EGD) demonstrated polypoidal growth, and histologic examination revealed brunner's gland adenoma.

CASE PRESENTATION

Case 1

A 55-year-old male patient presented and admitted with complaints of nausea and vomiting for several days, his

medical history was dyspepsia and had an episode of upper gastrointestinal bleeding. EGD was performed, it demonstrated polypoidal growth which involving distal pylorus and the first part of the duodenum (Figures 1 and 2).

CT confirmed a large 5.54 × 4.05 cm obstructing polypoidal lesion which was present along the posterior wall of the distal pyloric region of the stomach and first part of the duodenum. Intraoperatively, the surgeon found an ulceroinfiltrative growth in the second part of the duodenum which was infiltrating the medial wall of the duodenum and pancreatic head, Kocher maneuver was done, and a perforation was noted at the same site, so the surgeon performed a Whipple operation; portal vein was secured, then specimen was sent for the HPE. On gross examination, cut section of the duodenum showed a polypoidal mass measured 5.54 × 4.05 × 2.5 cm at the second

Address for Correspondence:

Dr. Madhubala Swarnakar, Assistant Professor, Department of Pathology, Shri Shankaracharya Institute of Medical Sciences, Bilhail - 490020, Chhattisgarh, India. **Mobile:** +91-9229456892. **E-mail:** mulkalwarmadhu@gmail.com

part of the duodenum and overlying mucosa of the polyp is effaced (Figure 3).

On microscopy, duodenum was lined by a hyperplastic columnar epithelium, lamina propria and submucosa showed a sheet of brunner's gland, and lobules of gland were separated by septae of proliferative smooth muscles. Some of nests of brunner's gland were cystically dilated with scant mitotic activity and extended up to the base of the duodenal villi admixed with chronic inflammatory infiltrate. The overall growth pattern of the gland was expansile rather than infiltrative due to which overlying mucosal epithelium was appear to be effaced and showed decreased number of crypts and villi; pancreas was appear to be pushed outwards. No infiltration was noted in circumferential margins or adjacent structures.

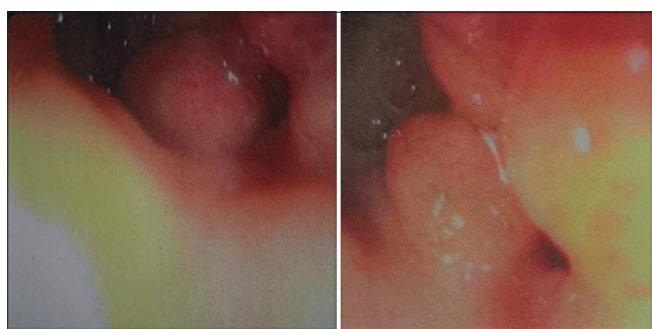

Figure 1: Endoscopic view of the duodenal mass being biopsied

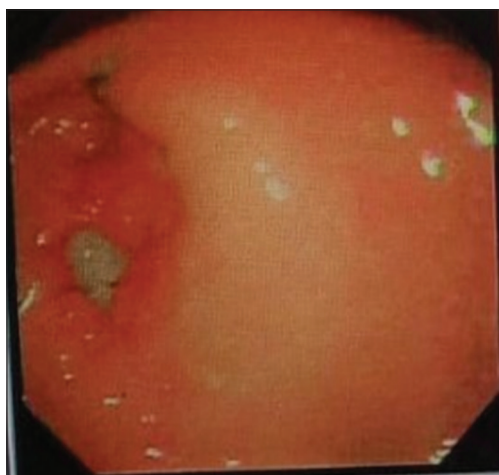

Figure 2: Endoscopic view of chronic deep ulcers in indurated margins

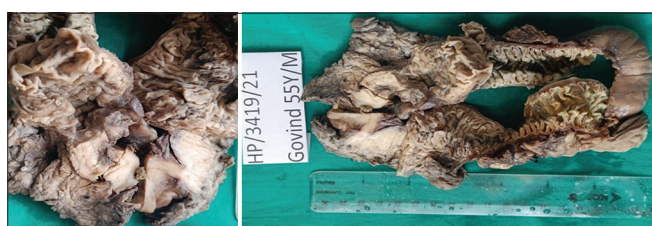

Figure 3: Gross finding shows a polypoidal growth with normal mucosa

Muscularis propria showed hypertrophy and serosa was unremarkable (Figures 4 and 5).

Both surgical cut margins, common bile duct, pancreatic parenchyma, and duct showed normal morphology. Five lymph nodes were retrieved that showed lymphoid hyperplasia. There was no evidence of *Helicobacter pylori* infection. The final diagnosis of Brunner's gland adenoma (BGA) with chronic duodenitis was made. Postoperatively, the patient recovered and during 6-month follow-up the patient remained symptoms free, and repeated EGD showed no any residual lesion.

Cases 2 and 3

Two of the cases were – 32-year-old and 22-year-old male patients presented with epigastric pain and vomiting, endoscopy showed multiple ulceration and polypoidal growth, biopsy taken and histopathological examination (HPE) performed, and cases were reported as BGH.

Case 4

A 45-year-old female patient presented with similar complaints, endoscopy showed chronic deep ulcers in prepyloric region with indurated margins and antral gastritis, biopsy was taken from indurated margins, HPE was performed, and case was reported as same.

Case 5

One of the case was 60-year-old male patient presented with perforation peritonitis, endoscopy showed margin of prepyloric perforation and gastrointestinal obstruction,

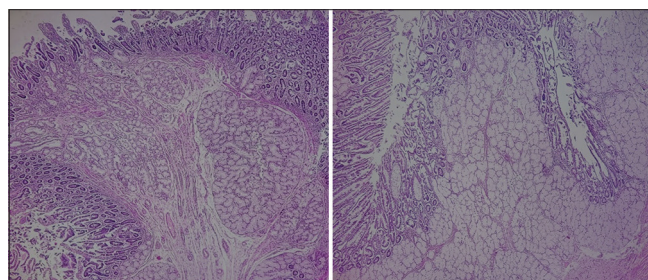


Figure 4: Microscopic examination showing Brunner's gland hyperplasia reaching up to duodenal villi (H and E stain, x400)

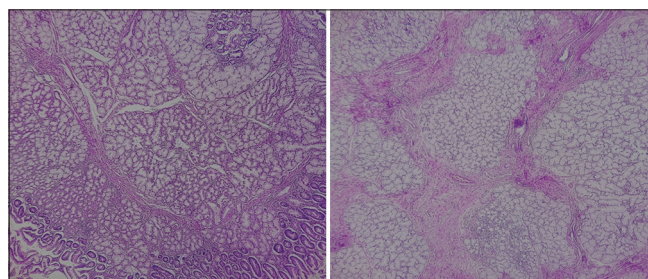


Figure 5: Microscopic examination showing BGH, Brunner's glands, separated by septa of proliferative smooth muscle, lying deep to the muscularis mucosae (H and E stain, x400)

biopsy was taken and HPE performed, and case was reported as BGH.

The details of the patient presentation, evaluation, surgical procedure, and outcomes are described in Table 1.

DISCUSSION

A BGA or BGH is a rare tumor-like lesion of the duodenum. Bojanapu et al., reported that BGH has mostly been seen in the fifth and sixth decades without any sex predilection, with unknown etiology.¹ McCafferty et al., reported that most of the lesions are located at the first part of the duodenum (70%), with decreasing incidence distally.² The present study showing coherence with this study (Table 1).

Most patients with BGH were asymptomatic or present with non-specific symptoms,³ the most common symptoms being gastrointestinal bleeding (37%) and obstructive symptoms (37%).⁴ Gastrointestinal obstruction occurs when the nodules of BGH are diffuse or the size of a single hamartoma is large enough (the average diameter should be >2.1 cm) EGD that is helpful for direct visualization and location of the BGH, but when the lesion is located at the posterior wall of the duodenal bulb, transitional part, and the beginning of the descending part, the chances of missed diagnosis are more.⁵ CT of BGH is helpful to demonstrate the extraluminal extent, its relationship to the pancreas, common bile duct, and vasculature.

In first case, the size of growth was more than 5 cm which was infiltrating the medial wall of the duodenum

Table 1: Clinical features and investigation findings of patients of Brunner's Gland Hyperplasia

S. No.	Age (year)/ Sex	Symptoms	Symptom Duration	Endoscopic Findings	<i>Helicobacter pylori</i> infection (+/-)	Pre-operative CT scan	Operative procedure	Tumour location	Diagnosis
Case 1	55 /M	Nausea, vomiting, dyspepsia, UGI bleeding	Several days	Polypoidal growth at distal pylorus and D1	n/a	A large 5.54×4.05 cm obstructing polypoidal mass lesion along the posterior wall of the distal pyloric region of the stomach and D1	Whipple's Procedure (Pancreatico-duodenectomy)	D2	Brunner's Gland Adenoma
Case 2	32/M	Epigastric pain, dyspepsia, vomiting and constipation	10 days	Esophagitis with multiple ulcers at the distal portion of the esophagus, antral gastritis, severe duodenitis and D2 narrowing with polypoidal growth.	+	n/a	Trans-duodenal Polyp excision	D1	Brunner's Gland Hyperplasia
Case 3	22/M	Dyspepsia, nausea, abdominal pain	1 month	Antral gastritis, D1, D2 junction circumferential thickening and narrowing chronic deep ulcers in prepyloric region with indurated margins and antral gastritis	+	n/a	Excision biopsy from D1, D2 junction	D1, D2 junction	Brunner's Gland Hyperplasia
Case 4	45/F	Abdominal, nausea, vomiting	10 days	n/a	n/a	n/a	Excision biopsy from indurated margins (Fig-2)	D1	Brunner's Gland Hyperplasia
Case 5	60/M	Abdominal pain, vomiting	15 days	n/a	n/a	n/a	Excision from D1 thickening	D1	Brunner's Gland Hyperplasia

M: Male; n/a: Not available; D1: First part of duodenum; D2: Second part of duodenum; (+): Positive; (-): Negative

and pancreatic head, the lesion was surgically resected by performing Whipple operation. Whipple's procedure may only be a choice when BGH is indistinguishable from malignancy.⁶

In one case of the present study, the size of the obstructing polypoidal growth was 5.54 cm, the diagnosis was BGA, this is the first case with more than 5 cm size, till now, only one study has reported giant BGA with few centimeters in size.⁷⁻¹¹ Remaining all cases, the size was <1 cm, were reported as BGH, similar finding has also reported by some authors.¹²

CONCLUSION

BGH is an uncommon benign condition of the duodenum, the patients were usually asymptomatic or may present with non-specific symptoms. Sometime, it is incidental finding. Endoscopic and/or surgical resection represents the ideal approach. Usually, endoscopic biopsies were mostly negative due to the normal mucosa covering the Brunner's gland proliferation. Hence, a deeper endoscopic or surgical biopsy provides adequate tissue for a definite diagnosis and to know the exact pathological nature of the duodenal mass.

ACKNOWLEDGMENT

The authors take this opportunity to thank SSIMS for their whole hearted support for this study.

REFERENCES

- Bojanapu S, Mangla V, Mehrotra S, Lalwani S, Mehta N and Nundy SI. Brunner's gland hyperplasia: An unusual duodenal submucosal lesion seen in four patients. *J Surg Case Rep.* 2018;2018(11):rjy305. <https://doi.org/10.1093/jscr/rjy305>
- McCafferty J, Tokhi A, Krishnamoorthy S and Pande G. Case report of Brunner's gland hyperplasia: A rare "mimic" of malignant pathology. *Int J Surg Case Rep.* 2021;81:105827. <https://doi.org/10.1016/j.ijscr.2021.105827>
- Singla R, Bharti P, Jain R, Kumar S, Ganguly KK and Kar P. Giant Brunner's gland adenoma manifesting as iron deficiency anemia and intussusceptions. *Natl Med J India.* 2010;23(6):376-377.
- Rocco A, Borriello P, Compare D, Colibud DB, Pica L, Iacono A, et al. Large Brunner's gland adenoma: Case report and literature review. *World J Gastroenterol.* 2006 March 28;12(12):1966-1968. <https://doi.org/10.3748/wjg.v12.i12.1966>
- Zhu M, Li H, Wu Y, An Y, Wang Y, Ye C, et al. Brunner's gland hamartoma of the duodenum: A literature review. *Adv Ther.* 2021;38(6):2779-2794. <https://doi.org/10.1007/s12325-021-01750-6>
- Nara BK and Chowdary V. Brunner's Gland Hyperplasia. A Case Series. *International Digestive Disease Forum (IDDF);* 2019.
- Tan YM and Wong WK. Giant Brunneroma as an unusual cause of upper gastrointestinal hemorrhage: Report of a case. *Surg Today.* 2002;32(10):910-912. <https://doi.org/10.1007/s005950200179>
- Rhiner R, Meyenberg A, Aeberhard P and Moschopoulos M. Large Brunner's adenoma of the duodenal bulb a case report. *Swiss Surg.* 1997;3(1):13-16. <https://doi.org/10.3748/wjg.v12.i12.1966>
- Smirnov OA, Serezhin BS and Nikonova OA. Brunner's gland adenoma of the duodenal bulb. *Arkh Pathol.* 1995;57(6):71-73.
- De Silva S and Chandrasoma P. Giant duodenal hamartoma consisting mainly of Brunner's gland. *Am J Surg.* 1977;133(2):240-243. [https://doi.org/10.1016/0002-9610\(77\)90090-3](https://doi.org/10.1016/0002-9610(77)90090-3)
- Bastlein C, Decking R, Voeth C and Ottenjann R. Giant brunneroma of the duodenum. *Endoscopy.* 1988;20(4):154-155. <https://doi.org/10.1055/s-2007-1018163>
- Maglinte DD, Mayes SL, Ng AC and Pickett RD. Brunner's gland adenoma diagnostic considerations. *J Clin Gastroenterol.* 1982;4(2):127-131. <https://doi.org/10.1097/00004836-198204000-00006>

Authors Contribution:

SM- Concept and design of the study; interpreted the results; reviewed the literature; and manuscript preparation; **MS**- Concept and design of the study; interpreted the results; reviewed the literature; and manuscript preparation and revision of the manuscript; **RKC**-Interpreted the results; reviewed the literature; statically analyzed and interpreted; and preparation of manuscript; **ML**- Interpreted the results; concept, coordination, review of literature, and manuscript preparation.

Work attributed to:

Shri Shankaracharya institute of medical sciences, Junwani, Bhilai, Chattisgarh, India.

Orcid ID:

Dr. Sarika More - <https://orcid.org/0000-0002-4937-5941>
 Dr. MadhubalaSwarnakar - <https://orcid.org/0000-0002-3477-6689>
 Dr. Rajendra Kumar Chandrakar - <https://orcid.org/0000-0003-0696-3492>
 Dr. ManjulaLader - <https://orcid.org/0000-0003-0971-0554>

Source of Support: Nil, **Conflict of Interest:** None declared.