


# ASIAN JOURNAL OF MEDICAL SCIENCES



## Tinea Pedis- an Update

Vikas Kumar<sup>1\*</sup>, Ragini Tilak<sup>1</sup>, Pradyot Prakash<sup>1</sup>, Chaitanya Nigam<sup>1</sup>, Richa Gupta<sup>2</sup>

<sup>1</sup>Department of Microbiology, <sup>2</sup>Department of Forensic Medicine, Institute of Medical Sciences, Banaras Hindu University, Varanasi-221005, India.

### Abstract

Cutaneous fungal infections are a widespread public health concern affecting millions of people all across the world. Nearly half of those affected will experience multiple episodes of infection requiring numerous rounds of treatment. Tinea pedis is a common superficial fungal skin infection of the feet. It is emerging as an important and a significantly prevalent infection in an increasingly aging population and immunocompromised patients. This mycotic infection is contagious, frequently misdiagnosed and often inadequately treated. Considering the uprising prevalence of tinea pedis, in this review article predisposing factors, etiologic agents involved in pathogenesis, clinical presentation of the disease, proper diagnostic tests and the treatment options commercially available are reviewed.

**Key Words:** *Tinea pedis; Dermatophytes; KOH Mount; PAS Reaction*

### 1. Introduction

**T**inea pedis (athlete's foot) is one of the most common superficial fungal infection of the skin in all regions of the world. Mycotic infections of the foot are common in adult males and uncommon in women and children. It is more common in close communities such as army barracks, boarding schools and among those frequenting swimming pools, when the feet are occluded with nonporous shoes. The incidence of this infection is higher in warm humid climates which are known to promote the growth of fungi, but has been found to occur less frequently in areas of the world where shoes are not commonly worn.<sup>1</sup> Tinea pedis infects through direct contact with arthroconidia (produced by dermatophytic filaments), although wearing tight-fitting shoes promotes infection and its spread.<sup>2</sup> Tinea pedis may be accompanied by dermatophyte infection of other parts of the body including groin, hands or nail. Approximately 15% of the population has a podiatric fungal infection at any given time and over 70% of individuals will experience foot based fungal infection, most likely tinea pedis, over the course of their lifetime.<sup>3</sup> Once infected, the organism is

long lasting in the host and the individual acts as a carrier.<sup>4</sup>

Patient with severe symptoms may seek for medical help and often they have concomitant fungal infection of toenail.<sup>5, 6</sup> There are many undiagnosed cases which may be asymptomatic and unsuspected of tinea pedis but a possible source of infection for others.

### 2. Predisposing Factors

Individuals with impaired immune defences are highly susceptible to the infection. HIV/AIDS, organ transplantation, chemotherapy, steroids and parenteral nutrition etc. are commonly recognized as factors that decreases a patient resistance to dermatophyte infection.<sup>7, 8</sup> Conditions like advanced age, obesity, diabetes mellitus also have a negative impact on a patient overall health and there by decreases immunity and increases the risk of tinea pedis. Diabetes mellitus alone accounts for a significant portion of infection, as patients with this condition are 50% more prone to have fungal infection.<sup>9</sup>

### 3. Etiological Agents

Most cases of tinea pedis are caused by dermatophytes, fungi that cause superficial infection of the skin and nail by infecting the keratin of the top layer of the epidermis.<sup>10</sup> Tinea pedis is most commonly caused by anthropophilic species like *Trichophyton rubrum* (60%),

#### \*Correspondence:

Dr Vikash Kumar Gupta, Department of Microbiology, Institute of Medical Sciences, Banaras Hindu University, Varanasi-221005, India. E-mail: drg.vikas@gmail.com

*T. mentagrophytes* (20%), *Epidermophyton floccosum* (10%) and more rarely by *M. canis* and *T. tonsurans*. However, the true etiology in any given patient may be complicated by the presence of saprophyte fungi, yeast and /or bacteria. It has been observed that 9% of the cases of tinea pedis are caused by infecting agents other than dermatophyte. Nondermatophyte fungi *Malassezia furfur*, bacterium *Corynebacterium minutissimum* and yeast such as *Candida species* were also found to be responsible for tinea pedis.<sup>11,12</sup>

#### 4. Clinical Presentation

There are four distinct clinical types of tinea pedis - interdigital, hyperkeratotic, ulcerative and vesicular, each with a characteristic pattern of skin manifestations. (Fig. 1)

**4.1. Interdigital Tinea pedis:** It occurs in two forms, most common form of this infection usually arise in the interspaces between 4<sup>th</sup> and 5<sup>th</sup> toes, occasionally spreading to the underside of the foot. First type of interdigital tinea pedis, known as **Dermatophytosis simplex**, is largely asymptomatic and presents as dry, scaly, minimally peeling interspaces with occasional pruritus. The second form **Dermatophytosis complex** is symptomatic and usually presents with wet, macerated interdigital spaces along with fissuring of the interspace, hyperkeratosis, leukokeratosis and erosions.

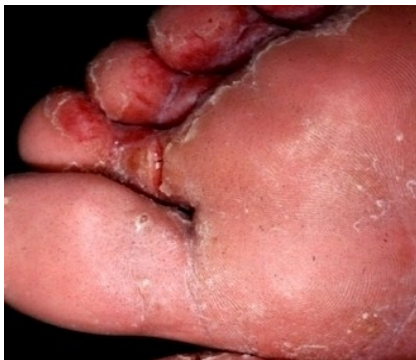

Figure-1: *Tinea pedis* - On the sole of the foot

**4.2. Hyperkeratotic or Moccasin type Tinea pedis:** This consists of scaling and hyperkeratosis involving the plantar and lateral aspect of the foot, resembling a slipper. Infection with moccasin type tinea pedis is generally bilateral and is often accompanied by subungual onychomycosis. This type of infection is thought to be due to *Trichophyton rubrum*, usually in patient with an atopic background or a hereditary predisposition to infection.<sup>1, 13</sup>

**4.3. Ulcerative Tinea pedis:** There is an acute ulcerative process usually affecting the soles and associated

with maceration, denudation of the skin and oozing.

**4.4. Vesicobullous Tinea pedis:** It is the least common form of this infection. Patients with this type of tinea pedis experience small vesicles and blisters on erythematous base, usually near the instep and adjacent plantar surface of the feet sometimes pustules are also found in this type but characteristically they are small and associated with clear vesicles. Vesicles filled with pus rather than clear fluid are indicative of secondary bacteraemia usually *Staphylococcus aureus*.<sup>10</sup>

Other variants include interdigital infections in which dermatophyte damages the stratum corneum and causes subsequent maceration and leukokeratosis resulting from overgrowth of bacteria such as *Micrococcus*, *Sedantarius*, *Brevibacterium epidermidis*, *C. minutissimum*.<sup>13, 14</sup>

#### 5. Differential Diagnosis

In clinical practise, diagnosis of tinea pedis is often based on clinical presentation, direct microscopic examination of skin scrapings and mycology culture.<sup>15</sup> Dermatophytosis of the foot may be symptom of a number of conditions similar in appearance to tinea pedis, reinforcing the need to positively identify infection through testing. The clinical differential diagnosis of cutaneous eruptions of the foot includes many look-alike conditions, such as contact dermatitis, psoriasis, dyshidrosis, eczema, atopic dermatitis, keratoderma, lichen planus and some bacterial infections like *C. minutissimum*, Streptococcal cellulitis etc. are also commonly confused with tinea pedis.

#### 6. Laboratory Diagnosis

An accurate diagnosis of tinea pedis should include proper diagnostic tests in addition to clinical diagnosis. Appropriate identification and treatment of tinea pedis upon a patient initial presentation has the potential to significantly reduce patient discomfort, risk of transmission and morbidity associated with the infection.<sup>17</sup> Diagnostic accuracy of the tests, fungal culture on SDA and KOH preparation of skin scrapings varies from 50-70%.<sup>13</sup>

##### 6.1. KOH Mount

Direct microscopic examination for fungal elements is considered to be rather insensitive method, with approximately 15% false negative, depending on the inappropriate testing material, insufficient scraping amount, outdated or defective KOH solution and the experience of the observer.<sup>18</sup> Upon microscopic examination finding septate or branched hyphae,

arthrospore, or in some cases, budding cells provides evidence of fungal infection.

## 6. 2. Culture

Culture of suspected tinea pedis lesions are performed on Sabouraud's dextrose agar (SDA). The acidic pH of 5.6 for this medium inhibits many species of bacteria and can be made more selective with an addition of a chloramphenicol supplement. The culture can take 2-4 weeks to complete.<sup>19</sup> Dermatophyte test medium (DTM) is used for selective isolation and recognition of dermatophytic fungi is another diagnostic option, which relies on colour indication that changes from orange to red to signify the presence of dermatophytes. Results of DTM have been shown to be only about 60% accurate.<sup>20</sup>

## 6.3. Periodic Acid Schiff Stain/ PAS Reaction Test

It is the preferred test for the diagnosis of tinea pedis infection. The PAS stain reliably demonstrates the polysaccharides- laden wall of the fungal organism associated with this condition and is one of the most widely used technique for detecting protein bound carbohydrate (glycoprotein). This test is performed by exposing tissue of various substrates to a series of oxidation- reduction reactions, as an end result, positive elements such as carbohydrates, basement membrane material become candy apple red. These PAS positive components contrast sharply against a pink blue background. Unlike SDA or DTM cultures, PAS results are available in approximately 15 minutes. PAS has also been found to be the most reliable diagnostic test for tinea pedis, with 98.8% efficacy and least cost effective.<sup>21</sup>

## 6. 4. Confocal Microscopy

New and more sensitive techniques are being investigated, such as confocal microscopy, but these techniques may not be ready for widespread use for some time.<sup>22</sup> Confocal microscopy is a non-invasive technique that provides high resolution images of intact skin comparable to routine histology, without requiring specimen preparation.

## 6. 5. Molecular Methods

Recently, molecular biology-based techniques, such as PCR followed by restriction fragment length polymorphism (RFLP), Real time PCR and multiplex PCR assay have been adapted for detection of dermatophytes from clinical specimen.<sup>23, 24, 25</sup> These molecular methods have a good potential to directly detect dermatophytes in clinical specimens, however these methods are yet to

be standardized for routine clinical laboratories. PCR - RFLP is a technique with poor discriminative power to make an easy and specific diagnosis. Real time PCR appears to be promising but is not practical enough for a large number of laboratories that are either small scale or very tightly budgeted. Nested PCR for skin dermatophytoses was observed to be more sensitive for the detection of dermatophytes than culture isolation, KOH microscopy, and single-round PCR. Further nested PCR is helpful for the diagnosis of cases with dermatophytoses which were recently treated with antifungal agents and showed uncultivable filaments and also grew as spurious moulds which were difficult to identify.<sup>26</sup> It may therefore be concluded that nested PCR targeting the CHS1 gene may be considered the gold standard for detection of dermatophytes in patients with dermatophytoses.<sup>27</sup>

## 6. 6. Mass Spectrometry

Matrix assisted laser desorption/ ionization time of flight (MALDI -TOF) technique has been applied for the rapid and reliable identification of microorganism including dermatophytes belonging to the taxa *Trichophyton rubrum*, *T. tonsurans* and *Microsporum canis*. This approach detects highly abundant proteins in a mass range between 2 and 20 kDa, serving as taxon specific biomarkers. The striking advantage of mass spectral approaches over genetical or morphological procedures is the very simple and straight forward sample preparation procedure and the short time required for analysis. The complete analysis including sample preparation and data evaluation is completed within minutes.<sup>28</sup>

## 7. Prevention

Tinea pedis or Athlete's foot is one of the most common of all foot ailments. Good patient education, with simple instructions as to the importance of foot hygiene, can help prevent and minimize the progression of tinea pedis. Good education consists of proper hygiene instructions, emphasizing the importance of drying the feet, practicing good nail care, and wearing properly fitting shoes with clean dry socks. It is important to promote preventive measures, thereby avoiding possible infections through interpersonal contact as well as using common sport spaces.<sup>29</sup> The use of antifungal foot powders is controversial but may be helpful for persons susceptible to tinea pedis who have frequent exposures to areas where the fungus is suspected. Proper diagnosis and treatment of persons having underlying conditions

like diabetes mellitus, HIV, organ transplantation, peripheral vascular disease, alcoholism etc. is an essential part of prevention of tinea pedis infection.

## 8. Treatment

Before starting the treatment for tinea pedis, it is essential to establish the diagnosis of the disease so that the specific therapeutic modalities can be adopted and monitored during course of the treatment.

Topical antifungal agents: Topical antifungal agents are generally adequate in tinea pedis infection. Fungicidal drugs (as terbinafine, butenafine and naftifine) are often preferred over fungistatic drugs for the treatment of tinea pedis infection because its course can be as simple as one application daily for one week treating with high cure rate (Table-1).<sup>11</sup>

Table-1: Topical therapies for the treatment of Tinea Pedis

AGENT	FORMULATION	FUNGICIDAL OR FUNGISTATIC	FREQUENCY OF APPLICATION
Allylamines	1 % cream, gel	Fungicidal	Once or twice daily
Naftifine			
Terbinafine			
Benzylamines	1% cream	Fungicidal	Once or twice daily
Butenafine			
Imidazoles	1% cream	Fungistatic	Once or twice daily
Econazole			
Ketoconazole			
Miconazole			
Sertaconazole			
Miscellaneous	1% cream	Fungistatic	Twice daily
Ciclopirox			
Tolnaftate			

In severe cases, oral antifungal drugs may be preferred for the treatment of tinea pedis infection. Newer agents the triazoles, fluconazoles, itraconazole and allylamine have broad spectrum activity against tinea pedis.<sup>20, 22</sup>

## 8. Conclusion

Tinea pedis is commonly called "athlete's foot". It is caused by a fungus that grows predominantly in warm moist environments and causes this infection that usually involves feet and toes. Tinea pedis affects a large number of people, and its prevalence is steadily increasing. Mainstay of treatment includes antifungal creams, solutions, sprays, powders, and in severe cases, oral antifungal drugs. Maintaining good foot hygiene, recognizing potential infection reservoirs, and vigilance in keeping the feet dry, including management of foot perspiration and judicious selection of socks and shoes, and other measures may prove beneficial in management and prevention.

## 9. References

- Masri-fridling GD. Dermatophytosis of the feet. *Dermatologic Clinics*.1996; 14:33-40 [http://dx.doi.org/10.1016/S0733-8635\(05\)70322-3](http://dx.doi.org/10.1016/S0733-8635(05)70322-3)
- Odom RB.Pathophysiology of dermatophyte infections. *Journal of the American Academy of Dermatology*; 1993; 28 Supplement: S2-S7 [http://dx.doi.org/10.1016/S0190-9622\(09\)80300-9](http://dx.doi.org/10.1016/S0190-9622(09)80300-9)
- Bell-Syer SE, Hart R et al. Oral treatments for fungal infections of the skin of the foot. *Cochrane Database Systematic Reviews* 2002; 8(2):CD003584
- Leyden J L. Tinea pedis: Pathophysiology and treatment. *Journal of the American Academy of Dermatology* 1994; 31 (3 Pt 2): S31-S3 [http://dx.doi.org/10.1016/S0190-9622\(08\)81264-9](http://dx.doi.org/10.1016/S0190-9622(08)81264-9)
- Maruyama R, Hiruma M., Yamauchi K et al. An epidemiological and clinical study of untreated patients with tinea pedis within a company of Japan. *Mycoses* 2003; 46:208-12.<http://dx.doi.org/10.1046/j.1439-0507.2003.00864.x> PMID:12801364
- Ogasawara Y, Hiruma M et al. Clinical and mycological study of occult tinea pedis and Tinea unguium in dermatological patients from Tokyo. *Mycoses* 2003; 46:114-9 <http://dx.doi.org/10.1046/j.1439-0507.2003.00855.x> PMID:12870199
- Loo D S. Cutaneous fungal infections in the elderly. *Dermatologic Clinics* 2004; 22:33-50. [http://dx.doi.org/10.1016/S0733-8635\(03\)00109-8](http://dx.doi.org/10.1016/S0733-8635(03)00109-8)
- Rinaldi M G. Dermatophytosis: Epidemiological and Microbiological update. *Journal of the American Academy of Dermatology* 2000; 43: S120-S24. <http://dx.doi.org/10.1067/mjd.2000.110378>
- Carlo CJ, Mac Williams P. Tinea pedis (athlete's foot) 2007. Available at: <http://www.bhchp.org>.
- Al Hasan M, Fitzgerald SM et al. Dermatology for the practicing allergist: tinea pedis and its complications, *Clinical and Molecular Allergy* 2004; 2:5 <http://dx.doi.org/10.1186/1476-7961-2-5> PMID:15050029 PMCid:419368
- Hainer B L., Dermatophyte infection. *American Family Physician* 2003; 67:101-8. PMID:12537173
- Rich P, Harkless LB et al. Dermatophyte test medium culture for evaluating toe nail infections in patients with diabetes. *Diabetes care* 2003; 26(5):1480-4. <http://dx.doi.org/10.2337/diacare.26.5.1480> PMID:12716808

13. Leyden I J, Aly R. Tinea pedis. *Seminars in Dermatology* 1993; 12(4): 280-284 PMID:8312143
14. The Merck Manual. Fungal skin infection 2007.
15. Lousbergh D, Buntinx F et al. Diagnosing dermatomycosis in general practice. *Family Practice* 1999; 16: 611-5 <http://dx.doi.org/10.1093/fampra/16.6.611> PMID:10625138
16. Sweeney SM, Wiss K, Mallory SB. Inflammatory tinea pedis/manuum masquerading as bacterial cellulitis. *Arch Pediatrics Adolescent Medicine* 2002; 156 (11):1149-52. PMID:12413346
17. Noble SL, Forbes RC et al. Diagnosis and management of common Tinea infection. *American Family Physician* 1998; 58: 177-8. PMID:9672436
18. Liu D, Coloe S et al. Application of PCR to the identification of dermatophyte fungi. *Journal of Medical Microbiology* 2000; 49: 493-497. PMID:10847201
19. FDA Advisory committee. Topical therapies efficacy and labelling issues for athletes foot drug products 2004.
20. Rich P, Harkless LB et al. Dermatophyte test medium culture for evaluating toenail infections in patients with diabetes. *Diabetes Care* 2003; 26; 1480-4. <http://dx.doi.org/10.2337/diacare.26.5.1480> PMID:12716808
21. Lilly K K, Koshnik RL et al. Cost effectiveness of diagnostic tests for toenail onychomycosis: A repeated measure single blinded cross sectional evaluation of 7 diagnostic tests. *Journal of the American Academy of Dermatology* 2006; 55(4): 620-26. <http://dx.doi.org/10.1016/j.jaad.2006.03.033> PMID:17010741
22. Markus R, Huzaira M et al. A Better Potassium Hydroxide Preparation? In vivo diagnosis of Tinea with confocal microscopy. *Arch. Dermatology* 2001; 137 (8):1076-8.
23. Yang G, Zhang M et al. Direct species identification of common pathogenic dermatophytes fungi in clinical specimens by Semi-nested PCR and Restriction Fragment Length Polymorphism. *Mycopathologia* 2008, 166 (4):203-8. <http://dx.doi.org/10.1007/s11046-008-9130-3> PMID:18523862
24. Arabatzis M, Bruijnesteijn LE et al. Diagnosis of common dermatophyte infections by a novel multiplex real-time polymerase chain reaction detection/identification scheme. *British Journal of Dermatology* 2007;157: 681-9. <http://dx.doi.org/10.1111/j.1365-2133.2007.08100.x> PMID:17672875
25. Brillowska DA, Saunte DM et al. Five-hour Diagnosis of Dermatophyte Nail Infections with Specific Detection of *Trichophyton rubrum*. *Journal of Clinical Microbiology* 2007; 45:1200-1204. <http://dx.doi.org/10.1128/JCM.02072-06> PMID:17267633 PMCID:1865842
26. Weitzman I, Summerbell RC: The Dermatophytes. *Clinical Microbiology Reviews* 1995; 240-59 PMID:7621400 PMCID:172857
27. Garg J, Tilak R et al, Rapid detection of dermatophytes from skin and hair. *BMC Research Notes* 2009.
28. Erhard M, Hipler U C et al. Identification of dermatophyte species causing onychomycosis and tinea pedis by MALDI-TOF mass spectrometry. *Experimental dermatology* 2008; (4):356-61 <http://dx.doi.org/10.1111/j.1600-0625.2007.00649.x> PMID:17979969
29. Meritxell P A, Josep Mar?a T A et al. Prevalence of Tinea pedis, tinea unguium of toe nails and tinea capitis in school children from Barcelona. *Revista Iberoamericana de Micolog? a* 2009; 26(4):228-32.