

Recurrent granular myringitis: Medical management revisited



Surbhi¹, Shaheen Zafar², Rohit Kumar³

^{1,2}Senior Resident, ³Post Graduate Resident, Department of ENT, Patna Medical College and Hospital, Patna, Bihar, India

Submission: 11-02-2021

Revision: 28-04-2022

Publication: 01-06-2022

ABSTRACT

Background: Granular myringitis (GM) is one of the rarer conditions reported in Indian literature. It is defined as a chronic inflammation limited to squamous layer of tympanic membrane. Several names have been given to it such as myringitis granulosa, acute granulomatous myringitis, and chronic myringitis. **Aims and Objectives:** The objective of our study is to evaluate the results of topical antibiotic with steroids and topical antibiotic alone on disease pathology of GM and its outcome. **Materials and Methods:** This study was conducted in the department of otorhinolaryngology on 80 patients from the period of September 2020–December 2021 on patients of GM after complete clinical evaluation. This is a prospective study made on two groups of patients. The results were analyzed by visual analog scale. **Results:** Both the groups after a period of 6 months showed improved results. The outcome with antibiotic with steroid was comparatively faster and superior than antibiotic only ear drops. **Conclusion:** The result of antibiotic with steroid ear drops is superior to antibiotic only ear drops in the treatment of recurrent GM.

Key words: Antibiotic; Steroids; Tympanic membrane

Access this article online

Website:

<http://nepjol.info/index.php/AJMS>

DOI: 10.3126/ajms.v13i6.43105

E-ISSN: 2091-0576

P-ISSN: 2467-9100

Copyright (c) 2022 Asian Journal of Medical Sciences



This work is licensed under a Creative Commons Attribution-NonCommercial 4.0 International License.

INTRODUCTION

Granular myringitis (GM) is a chronic condition which usually presents with otorrhea. In GM, de-epithelialization occurs on the outer layer of the TM and replacement with granulation tissue occurs in the absence of middle ear disease. Etiology of the disease is unidentified but it has been recommended that non-specific injury to the lamina propria, such as trauma or infection, may impair epithelialization and promote granulation tissue formation. Treatment of GM typically involves topical antimicrobial or antiseptics often for prolonged periods. More aggressive physical debulking or surgical excision and grafting are usually reserved for refractory cases of GM.

Aims and objectives

The objective of our study is to evaluate the results of topical antibiotic with steroids and topical antibiotic alone on disease pathology of GM and its outcome.

MATERIALS AND METHODS

This prospective study was conducted in the Department of Otorhinolaryngology at Patna Medical College and Hospital on 80 patients between the time duration of September 2020 and December 2021. Patient with GM was confirmed after apt clinical history, otoscopic examination followed by microsuctioning of the ear. It was confirmed that all the patients had been treated previously and having varying degrees of recurrence. The patients following all the inclusion and exclusion criteria were selected. Consent was taken from all the patients for participation in the study. The study was pre-approved by the Institutional Ethics Committee for the final permission.

Inclusion criteria

The following criteria were included in the study:

1. Patients between the ages of 8 years and 50 years
2. Proven case of recurrent GM

Address for Correspondence:

Dr. Shaheen Zafar, Senior Resident, Department of ENT, Patna Medical College and Hospital, Patna - 800 004, Bihar, India.

Mobile: +91-9955901433. **E-mail:** zafaronline1@yahoo.co.in

3. No other ear disease
4. Localized and unilateral GM.

Exclusion criteria

The following criteria were excluded from the study:

1. Chronic otitis media
2. Perforated tympanic membrane
3. Comorbid condition
4. Diffuse and bilateral GM.

Random number table was used to allot patients between Groups 1 and 2. Groups were those treated with acetic acid with steroids ear drops (acetic acid 2% and dexamethasone 0.1%w/v) (dose—four drops 4 times daily for 2 weeks)—Group 1 and antibiotic ear drops (ciprofloxacin 0.3%w/v) (dose—four drops 4 times daily for 2 weeks) – Group 2. Visual analog scale (VAS) was based on otorrhea and granulation tissue appearance; accordingly, patients were graded between 1 and 10 in decreasing order of severity. Average VAS score calculated before starting trial. After trial, subjects were evaluated again on VAS on the 3rd, 7th and 14th day of treatment. Patients were followed up for 6 months. Response to treatment in two groups is tabulated as follows:

Good response –8–10 with markedly improved and resolved granulation

Moderate response –4–7 with moderate improvement in granulation tissue

Mild response –1–3 with no response or mild improvement in granulations

After all enrolled patients finished 6 months follow-up, results were analyzed. Groups were decoded and intervention used on them was deeply studied. Due to the number of groups and multiplicity of comparisons, Bonferroni correction was done to adjust P value.

RESULTS

The study was performed precisely on all the patients. Of all the patients recruited, 80 met the inclusion and exclusion criteria. It was 80 patients who accepted to participate in the study. At the end of the period, 80 patients finished the study, 40 in each group. Group 1 was acetic acid ear drop with steroids and Group 2 was antibiotic ear drop only. Chi-square test did not show difference between groups with gender distribution, P =0.876. Out of 80 patients, 30 were male and 50 were female (Figure 1). Average age of the participants was 38 years. Repeated measure analysis of variance test did not show any significant difference in the age of patients in our study groups (P=0.623). The average VAS score of subjects before drug trials was 5.9(2SD.92). Before and after test, VAS score comparison came out with better results during different follow-up intervals.

Mean differences of each group outcome were compared in different stages to understand better which treatment was better, Table 1 and Figure 5. The most common site of granulation tissue was posterior superior quadrant in our study (P< 0.001). Mean VAS score differences were calculated at different stages of trial and then compared. Our study at the end of the 3rd day (Figure 2) showed that acetic acid solution with steroids had huge improvement of VAS scores compared to antibiotic only drops treatment (P< 0.001). At the 7th day follow-up (Figure 3), the groups with acetic acid ear drops with steroids were significantly better than antibiotics alone(P ≤ 0.001). By the 14th day, both the groups showed improved result. However, the VAS score was much better in the group with acetic acid ear drops with steroids (P= 0.034) (Figure 4). Four of the patients retreated or sought further treatment in the 6-month period of follow-up in Group 2 and rest all the patients showed acceptable degree of improvement from baseline regardless of intervention used (Figure 5).

DISCUSSION

GM is defined as a chronic inflammatory disorder characterized by de-epithelialization of the outer squamous layer of the tympanic membrane and replacement with granulation tissue occurring in absence of middle ear disease.^{1,2}

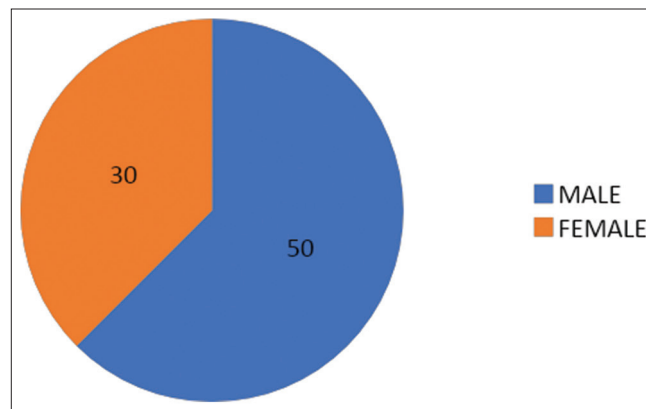


Figure 1: Gender distribution

Table 1: Treatment response in 2 weeks (VAS scoring) (% percentage of patients)			
	Mild	Moderate	Good
	%	%	%
3 rd day			
Group 1	15	30	55
Group 2	30	30	40
7 th day			
Group 1	10	25	65
Group 2	25	25	50
14 th day			
Group 1	5	20	75
Group 2	15	25	60

Etiology is not known but it has been suggested that non-specific injury to the lamina propria, such as trauma or infection, promotes granulation tissue formation.³ This theory may be supported by the high incidence of myringitis following myringoplasty (5.5%) and the fact that in some series of GM, Nearly all patients had prior otological surgery (93%).⁴ Positive cultures from affected ears *Pseudomonas aeruginosa*, *Staphylococcus aureus*, *Corynebacterium*, *Proteus mirabilis*, and fungal species implicate the contribution of infection to the etiology.^{5,6}

Clinically, this disease is known to last for 12 weeks.⁴ Presenting symptoms for most of the patient are persistent or recurrent painless otorrhea. In one study, 70% of these patients had symptoms for more than 1 year. Other symptoms are intrameatal itching or fullness, mild conductive hearing loss, and seldom otalgia. Some patients may be asymptomatic. Examination of the ear after cleaning and microsuction reveals granulation tissue overlying thickened tympanic membrane. It can be focal or diffuse.^{1,2} The segmental type is more common, with the posterosuperior segment of the eardrum most frequently affected. It may also involve the skin of the adjacent medial ear canal, perforation, or cholesteatoma excludes the diagnosis of GM.

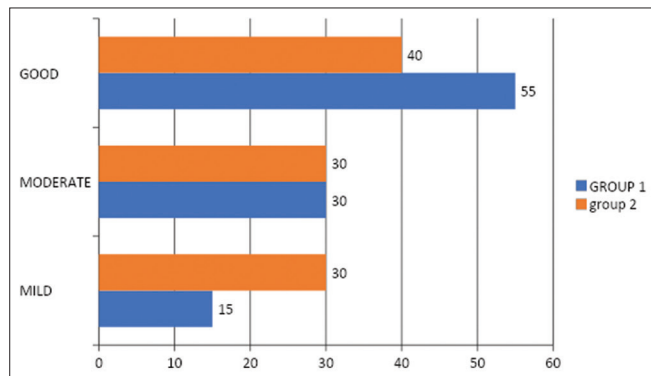


Figure 2: Percentage of patients in different groups based on average visual analog scale scores on the 3rd day

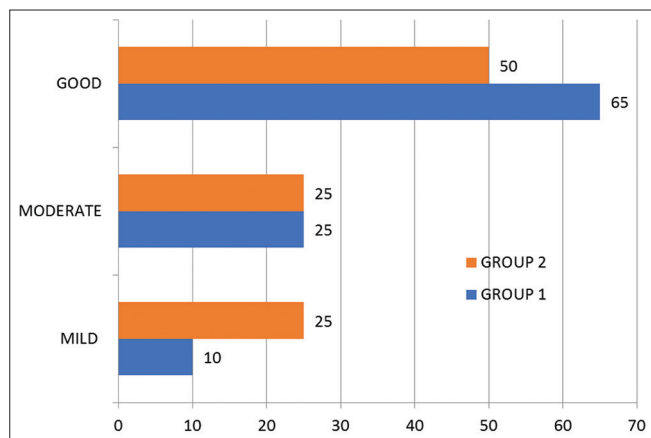


Figure 3: Percentage of patients in different groups based on average visual analog scale scores on the 7th day

A swab can be taken which aids in antimicrobial treatment. Associated hearing loss may be identified by pure tone audiometry or tympanometry. Infrequently, CT temporal bone may help exclude underlying middle ear/mastoid disease. Cases of significant otalgia or non-resolution despite treatment call for biopsy to exclude malignancy.

It is complex to know the natural history of disease as patients may be asymptomatic regardless of continued myringitis. However, we know that many patients have symptoms persisting for years.¹ This long-standing chronic inflammation of the tympanic membrane and medial ear canal wall skin, in association with proliferating granulation tissue, can lead to fibrosis, scarring, and stenosis of the medial ear canal with lateralization of the eardrum.

Most would agree that meticulous microscopic cleaning/debridement in combination with topical antibiotic or antiseptic agents forms the mainstay of initial management. A plethora of published treatment strategies exist.

These can largely be grouped into topical antibiotic and antifungals, often with a steroid/anti-inflammatory agent. Topical antiseptic agents: acetic acid, aluminum acetate, phenol and hydrogen peroxide are used. Vinegar has been found to be effective. It is a resultant of ethyl alcohol

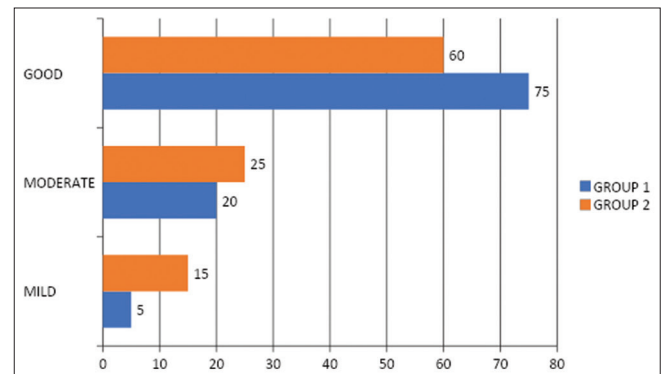


Figure 4: Percentage of patients in different groups based on average visual analog scale scores on the 14th day

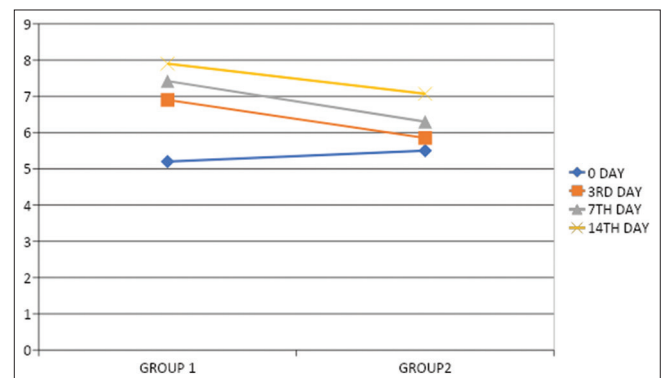


Figure 5: Mean visual analog scale trend in 2 weeks

when converted to acetic acid by *Acetobacter*. It can be produced by different methods and wide variety of raw material such as wine and fruits cider. It has antimicrobial properties on different microbial species affecting microbial growth, suppresses mononuclear cytokines, and phagocytic responses. Debulking of granulations with cold steel (curettage/cupped forceps), silver nitrate cautery is done. Laser evaporation of granulation tissue has been tried and results are successful. Granulation is removed and raw area is covered with skin or perichondrium.

Limitations of the study

Our study doesnot cover diffuse GM.

CONCLUSION

GM is a chronic condition usually presenting with otorrhea. Etiology is mostly unknown, though seen largely in patient with ear trauma and previous ear surgery. Topical treatment modalities have been found to be effective. Many options are available and results are as good as any other available choices. Many clinicians may use more than 1strategy. The result of antibiotic with steroid ear drops is superior to antibiotic only ear drops. The reports of antibiotic only ear drops are substandard to the former treatments. Surgery is reserved for those cases not responding to medical treatments.

ACKNOWLEDGMENT

We are grateful to our department seniors for guiding in this studyand also the patients who participated.

REFERENCES

1. Blevins N and Karmody C. Chronic myringitis: Prevalence, presentation, and natural history. *Otol Neurotol*. 2001;22(1):3-10. <https://doi.org/10.1097/00129492-200101000-00002>
2. Neilson LJ and Hussain SS. Management of granular myringitis: A systematic review. *J Laryngol Otol*. 2008;122(1):3-10. <https://doi.org/10.1017/S0022215107008924>
3. Makino K, Amatsu M, Kinishi M and Mohri M. The clinical features and pathogenesis of myringitis granulosa. *Arch Otorhinolaryngol*. 1988;245(4):224-229. <https://doi.org/10.1007/BF00463932>
4. Levi JR, Ames JA, Gitman L, Morlet T, O'Reilly RC. Clinical characteristics of pediatric granular myringitis. *Otolaryngol Head Neck Surg*. 2013;148(2):291-296. <https://doi.org/10.1177/0194599812470433>
5. Kim YH. Clinical characteristics of granular myringitis treated with castellani solution. *Eur Arch Otorhinolaryngol*. 2011;268(8):1139-1146. <https://doi.org/10.1007/s00405-011-1500-7>
6. Jung HH, Cho SD, Yoo CK, Lim HH and Chae SW. Vinegar treatment in the management of granular myringitis. *J Laryngol Otol*. 2002;116(3):176-180. <https://doi.org/10.1258/0022215021910474>

Authors Contribution:

S- Concept and design of the study, prepared first draft of manuscript, and interpreted the results; **SZ-** Reviewed the literature and interpreted the results; **RK-** Reviewed the literature and manuscript preparation, statistical analysis, and interpretation

Work attributed to:

Patna Medical College and Hospital, Patna - 800 004, Bihar, India

Orcid ID:

Dr. Surbhi - <https://orcid.org/0000-0002-3373-6917>

Dr. Shaheen Zafar - <https://orcid.org/0000-0002-3732-4610>

Dr. Rohit Kumar - <https://orcid.org/0000-0003-4952-7682>

Source of Support: Nil, **Conflict of Interest:** None declared.