

# Diaphragmatic eventration with impending gangrenous organoaxial volvulus of the stomach: Role of timely intervention



Ravindran Chirukandath<sup>1</sup>, Sharath Kesavan Krishnan<sup>2</sup>, Nimisha Chemmangattuvalappil Ramachandran<sup>3</sup>, Safna Kunhikandilakath<sup>4</sup>, Babu Pulluvileyil John<sup>5</sup>, Nayanathara Parayarakottayil<sup>6</sup>

<sup>1</sup>Additional Professor, <sup>2</sup>Associate Professor, <sup>3</sup>Assistant Professor, <sup>4</sup>Senior Resident, <sup>5</sup>Professor and Head, <sup>6</sup>Resident Intern, Department of General Surgery, Government Medical College, Thrissur, Kerala, India

Submission: 15-05-2022

Revision: 28-08-2022

Publication: 01-10-2022

## ABSTRACT

Eventration of diaphragm is a rare entity and often is characterized by a developmental abnormality of the diaphragm musculature. The acute presentation of organoaxial volvulus with impending gangrene of stomach is a life-threatening event and requires emergency diagnosis and surgical intervention. A 45-year-old man visited our hospital for evaluation of upper abdominal discomfort. He had a feeling of fullness and discomfort in the upper abdomen for 3 years. These attacks lasted about 2 hours and were not usually severe but eventually presented with severe abdominal pain. The patient was explored as general condition was deteriorating. On exploration, it was found that there was huge organoaxial stomach volvulus with impending stomach gangrene. Emergency exploration, gastropexy, and plication of diaphragm was done. Early diagnosis and prompt intervention may avoid consequent gastric volvulus and complications, improving the overall outcome and mortality.

**Key words:** Eventration; Organo axial volvulus; Gastropexy

### Access this article online

**Website:**

<http://nepjol.info/index.php/AJMS>

**DOI:** 10.3126/ajms.v13i10.39651

**E-ISSN:** 2091-0576

**P-ISSN:** 2467-9100

Copyright (c) 2022 Asian Journal of Medical Sciences



This work is licensed under a Creative Commons Attribution-NonCommercial 4.0 International License.

## INTRODUCTION

It usually remains asymptomatic in the early life and presents later with respiratory and occasionally gastrointestinal complications.<sup>1</sup> This abnormally wide space in the left subdiaphragmatic area leads to gastric volvulus. Acute gastric volvulus in pediatric and adult patients has been reported, but chronic organoaxial gastric volvulus with diaphragmatic eventration was rarely reported.<sup>2,3</sup>

This article presents a case of 45-year-old male with eventration of the left hemidiaphragm with chronic intermittent organoaxial gastric volvulus presented with

semi gangrenous stomach which needed emergency intervention.

## CASE REPORT

A 45-year-old man visited our hospital for evaluation of the upper abdominal discomfort. He had a feeling of fullness and discomfort in the upper abdomen for 3 years. These attacks lasted about 2 hours and were not usually severe. He was investigated and was diagnosed to have left eventration diaphragm and was advised elective repair. He was lost in follow-up and then landed up in emergency department with severe abdominal pain and upper GI obstruction.

### Address for Correspondence:

Dr. Ravindran Chirukandath, Additional Professor, Department of General Surgery, Government Medical College, Thrissur, Kerala, India.

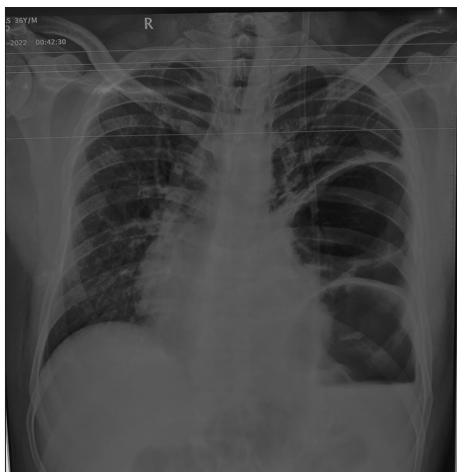**Mobile:** +91-9447040431. **E-mail:** ravimen@gmail.com

On clinical examination, he appeared acutely ill looking and his body temperature was 36°C, blood pressure 120/70 mmHg, and respiratory rate 24/min. Auscultation of the chest showed diminished breathing sound at the left lung base and heart sound was normal. The abdomen showed guarding and rebound tenderness. No gross abnormalities were observed in laboratory investigations.

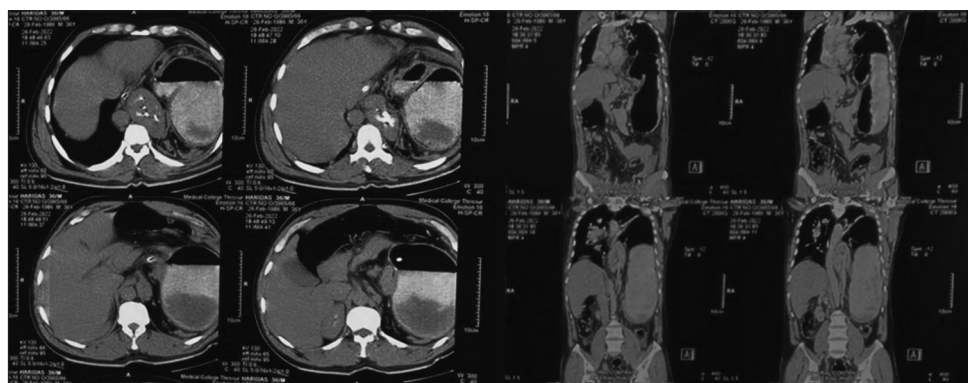
On imaging, chest X-ray revealed the left hemidiaphragm to be located at an unusually high intercostal space with large air-fluid level (Figure 1).

Emergency CT scan was taken, and it showed an eventration of diaphragm or diaphragmatic hernia with herniation of stomach with small bowel, transverse colon, and left Kidney in the left hemithorax and gross mediastinal shift to left (Figure 2).

The patient was explored as general condition was deteriorating. On exploration, it was found that there was huge organoaxial stomach volvulus with impending stomach gangrene. Whole transverse colon was shifted and adherent to the left hemidiaphragm inferiorly.



**Figure 1:** Plain X-ray Chest PA: Elevated left hemidiaphragm with dilated gastric air bubble



**Figure 2:** CT scan showing whole Left diaphragm elevated and thinned out with Spleen, transverse colon, stomach and small bowel loops in left thorax

The diaphragm was elevated up to the level of second intercostal space. Kidney and spleen also remained in subdiaphragmatic location (Figure 3).

Greater omentum was detached, and transverse colon was brought down. Stomach was de rotated and fixed. After reducing all contents into the abdomen, plication of diaphragm was done with prolene circumferentially (Figure 4).

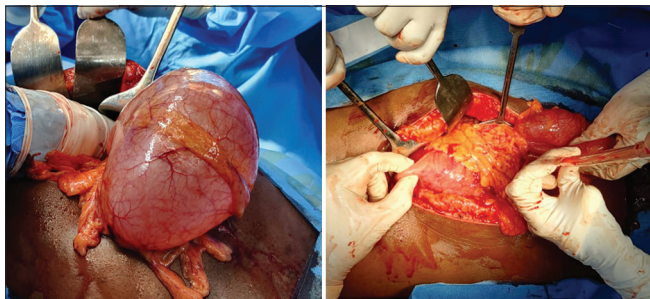
The patient was managed on CMV for 2 days and then weaned off to give rigorous lung physiotherapy and respiratory exercise. The patient improved and the lung on the left was completely expanded on day 10 and was discharged without any major complication in immediate post operative period (Figure 5).

## DISCUSSION

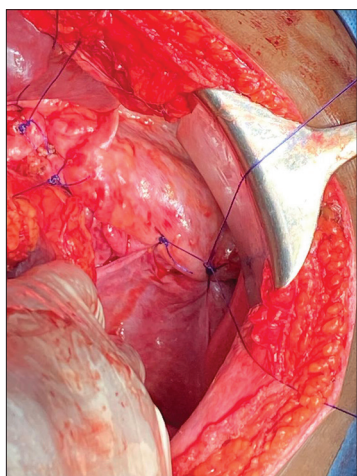
Eventration is a congenital anomaly of the diaphragm characterized by muscular aplasia and subsequent abnormal elevation of an intact hemidiaphragm. Pathologically, a total eventration hemidiaphragm consists of a thin membranous sheath attached peripherally to normal muscle at points of origin from the rib cage. It occurs almost exclusively on the left side.<sup>4</sup>

The stomach is relatively fixed at the esophageal hiatus and the pylorus by the four gastric ligaments (The gastrophrenic ligament, gastrohepatic, gastrocolic ligament, and gastrosplenic ligament). The absence or stretching of these ligaments can cause a volvulus.<sup>5</sup> There are two types of gastric volvulus which are organoaxial and mesenteric axial based on the axis of rotation.

The clinical symptoms depend on the extent or degree of rotation, obstruction, and associated defect. Borchardt's triad of pain, violent retching, and inability to pass a nasogastric tube<sup>6</sup> should lead to a strong clinical suspicion of acute gastric volvulus. An acute volvulus is an emergency, with either obstruction or strangulation of the stomach and requires emergency exploration. In



**Figure 3:** Intra operative picture showing organo axial volvulus stomach with dilatation and the transverse colon and omentum in the left hemithorax



**Figure 4:** Intra operative picture with reduced contents and diaphragmatic plication with prolene

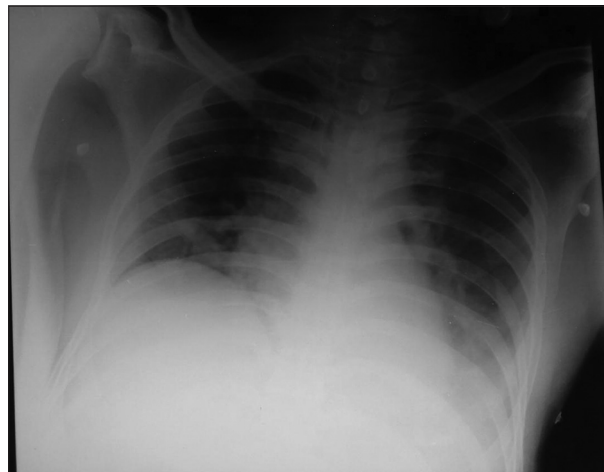
comparison, the clinical features of chronic volvulus are mainly due to complications of gastro-oesophageal reflux and gastric ulceration.

Mortality from acute gastric volvulus is now about 15–20%.<sup>5</sup> If the stomach is strangulated, the mortality rate of emergency surgery is 40–60%.<sup>6</sup> In recognized cases of chronic gastric volvulus, the mortality rate has been reported to vary from 0% to 13%.<sup>7</sup>

Early diagnosis is evidently the best way for better outcome and the diagnosis is confirmed by the presence of a large, unusual gas-filled viscus in the chest or abdomen on plain radiographs.

Barium swallow study shows (1) esophagogastric junction lying lower than normal, (2) reversal of the greater and lesser curvatures, (3) pylorus pointing downward, (4) greater curvature crossing the esophagus, and (5) two air-fluid levels and lowering of the gastric fundus.<sup>8</sup>

Contrast-enhanced CT Scan now can clearly identify the most common association is with congenital or acquired



**Figure 5:** Plain x-ray chest PA: post operative X-ray showing expanded left lung and reduced contents

defects of the diaphragm such as paraoesophageal hernia, traumatic rupture of the diaphragm, eventration of the diaphragm, and phrenic nerve injury.<sup>9</sup>

Diaphragmatic eventration is suggested when a part or all of the hemidiaphragm is located at an unusually high level in the thorax and it may be congenital or acquired. Acquired lesions are usually related to phrenic nerve injury, which may be diverse in origin. Radiological investigation combined with fluoroscopy of the diaphragm should be diagnostic.

Acute gastric volvulus and symptomatic chronic gastric volvulus require operative treatment. The most widely accepted approach is repair through an abdominal (subcostal) incision, because this allows ready access to both diaphragms for plication, permits anterior gastric fixation through gastropexy or gastrostomy, and allows abdominal exploration for associated gastrointestinal anomalies.<sup>2</sup> It will require mobilization and dropping down the transverse colon from subdiaphragmatic location by dividing greater omentum (Tanner's operation), de-rotation of stomach and Gastropexy.

Acute and chronic cases can be treated with endoscopic reduction, and is done by advancing the endoscope just past the point of torsion, turning and locking the tip of the instrument, and rotating it 180°<sup>10</sup> percutaneous endoscopic gastropexy and laparoscopic gastropexy<sup>11,12</sup> for gastric volvulus, which are coming to practice in centers of expertise.

## CONCLUSION

Early diagnosis and prompt intervention may avoid consequent gastric volvulus and complication improving the overall outcome.

## REFERENCES

1. Wayne ER, Campbell JB, Barrington JD and Davis WS. Eventration of the diaphragm. *J Pediatr Surg.* 1974;9(5):643-651. [https://doi.org/10.1016/0022-3468\(74\)90101-8](https://doi.org/10.1016/0022-3468(74)90101-8)
2. Park WH, Choi SO and Suh SJ. Paediatric gastric volvulus--experience with 7 cases. *J Korean Med Sci.* 1992;7(3):258-263. <https://doi.org/10.3346/jkms.1992.7.3.258>
3. Um JC, Choi DH, Lee YB and Kim SC. Acute gastric volvulus due to diaphragmatic hernia: A report of one case. *J Korean Surg Soc.* 1993;44:911-915.
4. Hamby W. *The Case Reports and Autopsy Records of Ambrose Pare.* Springfield IL: Charles C Thomas; 1960.
5. Rat P, Haas O, Christophe M, Friedman S and Favre JP. Surgical results of intrathoracic gastric volvulus complicating hiatal hernia. *Br J Surg.* 1990;77(12):1379-1381. <https://doi.org/10.1002/bjs.1800771219>
6. Carter R, Brewer LA, 3<sup>rd</sup> and Linshaw DB. Acute gastric volvulus: A study of 25 cases. *Am J Surg.* 1980;140(1):99-106. [https://doi.org/10.1016/0002-9610\(80\)90424-9](https://doi.org/10.1016/0002-9610(80)90424-9)
7. Thorpe JA. Chronic gastric volvulus: Aetiology and treatment. *Br J Clin Pract.* 1981;35:61-62.
8. Honna T, Kamii Y and Tsuchida Y. Idiopathic gastric volvulus in infancy and childhood. *J Paediatric Surg.* 1990;25(7):707-710. [https://doi.org/10.1016/s0022-3468\(05\)80001-6](https://doi.org/10.1016/s0022-3468(05)80001-6)
9. Davis R. Organo-axial volvulus of the stomach with eventration of the diaphragm. *S Afr Med J.* 1973;47:2342-2346.
10. Tsang TK, Walker R and Yu DJ. Endoscopic reduction of gastric volvulus: The alpha-loop manoeuvre. *Gastrointest Endosc.* 1995;42(3):244-248. [https://doi.org/10.1016/s0016-5107\(95\)70099-4](https://doi.org/10.1016/s0016-5107(95)70099-4)
11. Baudet JS, Armengol-Mio JR, Medina C, Accarino AM, Vilaseca J, Malagelada JR. Percutaneous endoscopic gastrostomy as a treatment for chronic gastric volvulus. *Endoscopy.* 1997;29(2):147-148. <https://doi.org/10.1055/s-2007-1004106>
12. Beqiri A, Vanderkolk WE and Scheeres D. Combined endoscopic and laparoscopic management of chronic gastric volvulus. *Gastrointest Endosc.* 1997;46(5):450-452. [https://doi.org/10.1016/s0016-5107\(97\)70040-3](https://doi.org/10.1016/s0016-5107(97)70040-3)

### Authors Contribution:

**RC-** Review of manuscript design and treating Surgeon; **SK-** Treating surgeon; **NCR-** Manuscript support. **SAF-** Resident in-charge; **BPJ-** Treating surgeon; **NPK-** Resident in-charge.

### Work attributed to:

Government Medical College, Thrissur, Kerala, India.

### Orcid ID:

Dr. Ravindran Chirukandath - <https://orcid.org/0000-0002-0562-1952>  
Dr. Sharath Kesavan Krishnan - <https://orcid.org/0000-0003-0477-9659>  
Dr. Nimisha CR - <https://orcid.org/0000-0002-8530-4059>  
Dr. Safna Kunhikandilakath - <https://orcid.org/0000-0001-8973-1691>  
Dr. Babu Pulluvileyil John - <https://orcid.org/0000-0003-1650-3609>  
Dr. Nayanathara Parayarukottayil - <https://orcid.org/0000-0002-8710-7091>

**Source of Funding:** Nil, **Conflicts of Interest:** None declared.