

# Percutaneous management of Stuck Rotational Atherectomy Burr: Experience at a tertiary care centre



Ajay Raj<sup>1</sup>, Ranjit Kumar Nath<sup>2</sup>, Ashok Kumar Thakur<sup>3</sup>, Ajay Pratap Singh<sup>3</sup>,  
Neeraj Pandit<sup>1</sup>, Sripad Vasant Khairnar<sup>3</sup>

<sup>1</sup>Professor, <sup>2</sup>Professor and Head, <sup>3</sup>Senior Resident, Department of Cardiology, Atal Bihari Vajpayee Institute of Medical Sciences and Dr. Ram Manohar Lohia Hospital, New Delhi, India

Submission: 15-10-2020

Revision: 23-12-2020

Publication: 01-02-2021

## ABSTRACT

**Background:** The incidence of stuck rotational atherectomy (RA) burr is extremely low, and its description has been sporadic in the literature about the systemic management of this complication. **Aims and Objective:** The current study was designed to present the experience of our center and propose an algorithm for the retrieval of stuck RA burr. **Materials and Methods:** We retrospectively evaluated cases of RA between August 2018 to August 2020 at our center. An entrapped RA burr was defined as an inability to move the burr backward without any additional maneuvers during or after the rotablation of a coronary lesion. Angiographic and procedural details were reviewed in the identified cases of entrapped rotablator burr, details of maneuvers used to retract the burr was documented. We further analyzed the literature using PubMed search using the keywords "entrapment of rotablator burr", "stuck rotablator" and "rotablation complications". All the articles with entrapped rotablation burr were identified and scrutinized for the techniques used for percutaneous retrieval. **Results:** Out of the total 5780 Percutaneous coronary intervention (PCI) procedures, RA was performed in 75 patients and RA burr entrapment was confirmed in two cases. Both the cases were seen in patients with angulated and heavily calcified lesions. The cases were managed percutaneously by endovascular maneuvers. A total of 8 techniques were identified by analysis of available literature for burr retrieval with surgery being the favored one. Using the experience of our center and available literature we propose a simplified working algorithm towards systematic management of this complication. **Conclusion:** RA burr entrapment is rare, but a life-threatening complication, and the operator should be prepared with strategies for successful retrieval of stuck burr. Percutaneous retraction maneuvers should be used as the first-line management for retrieval of stuck burr followed by surgical referral. Using the proposed algorithm this rare complication can be managed systematically and effectively.

**Key words:** Rotational atherectomy; Stuck burr; Entrapment; Rotablator

## INTRODUCTION

Percutaneous coronary intervention (PCI) is the most commonly used treatment modality for obstructive coronary artery disease.<sup>1</sup> Over the past four decades, there have been significant advances in PCI, despite its severe coronary calcification remains a challenge for successful PCI.<sup>2</sup> Upto 20% of patients undergoing PCI are estimated

to have coronary calcification which has an inadvertent effect on the procedure and its outcome.<sup>3,4</sup>

Calcified lesions are difficult to tackle in PCI as they are difficult to dilate even with high-pressure inflations with non-compliant balloons.<sup>5</sup> Angioplasty balloons are prone to asymmetric expansions and dog-boning around the calcified lesion increasing the risk of coronary

### Access this article online

#### Website:

<http://nepjol.info/index.php/AJMS>

DOI: 10.3126/ajms.v12i2.32181

E-ISSN: 2091-0576

P-ISSN: 2467-9100

Copyright (c) 2021 Asian Journal of Medical Sciences



This work is licensed under a Creative Commons Attribution-NonCommercial 4.0 International License.

### Address for Correspondence:

Dr. Ajay Pratap Singh, Senior Resident, Department of Cardiology, Atal Bihari Vajpayee Institute of Medical Sciences (ABVIMS) & Dr. Ram Manohar Lohia Hospital, New Delhi 110001, India. **Mobile No:** +91-9532832762. **E-mail:** [ajayaps04@gmail.com](mailto:ajayaps04@gmail.com)

dissections.<sup>6</sup> Calcified lesion impedes the delivery of stents and has an inherent chance of stent under expansion and malapposition.<sup>7</sup> With the advent of intravascular ultrasound (IVUS) imaging which has provided details for the mechanism of stent failure and highlighted the importance of plaque modification before stent implantation.<sup>8</sup>

Rotational atherectomy has been shown to have a high success rate when dealing with complex calcified lesions<sup>9,10</sup> with complications up to 2% such as no/slow flow, large dissection, and coronary perforation.<sup>10</sup> One of a rare but life-threatening complication is a stuck rotablator burr which can be defined as the entrapment of burr in or around the lesion with an impossibility of retrieval without any additional intervention which can be surgical or percutaneously assisted. This study aims to present our experience and summarize the techniques for percutaneous retrieval of stuck rotablator burr.

## MATERIALS AND METHODS

Out of the total 5780 PCI procedures, RA was performed in 75 patients in the time frame of August 2018 to August 2020. An entrapped rotablator burr was defined as an inability to move the burr backward without any additional maneuvers during or after the rotablation of a coronary lesion.

Angiographic and procedural details were reviewed in all the identified cases of entrapped rotablator burr, details of maneuvers used to retract the burr or referral to surgery were documented. Written informed consent was taken from all the patients before PCI and data collection was approved by the institutional ethical board.

We further analyzed the literature using PubMed search using the keywords “entrapment of rotablator burr”, “stuck rotablator” and “rotablation complications”. All the articles with entrapped rotablation burr were identified and scrutinized for the techniques used for percutaneous retrieval.

## RESULTS

During the timeframe of August 2018 to August 2020 total of 75 RA procedures were done at our center and rotablation burr entrapment was confirmed in two cases. These cases were performed by two operators and all the cases of burr entrapment were managed by percutaneous maneuvers. A comparison of baseline characteristics and key procedural aspects are compared with overall

**Table 1: Characteristics of two patients with rotablator burr entrapment compared with the total population of rotablation procedures at our center**

Characteristic	Stuck Rotablator (n=2)	Total Rotablation (n=75)
Age, years	58.76±8.3	63.76±17.8
Male Gender	2 (100%)	56 (74.6%)
Diabetes Mellitus	2 (100%)	39 (52%)
Presentation	ACS	1 (50%)
	Angina	1 (50%)
Burr Size (Mm)	1.5	1.36±0.4
Burr To Artery Ratio	0.57±0.2	0.52±0.4
Angiographic Lesion	LM	0
	LAD	1 (50%)
	LCx	0
	RCA	1 (50%)
		7 (9.3%)
		42 (56%)
		11(14.6%)
		15 (20%)

ACS= acute coronary syndrome; LM= left main coronary artery; LAD= left anterior descending artery; LCx= left circumflex; RCA= right coronary artery

populations is shown in Table 1. Both cases are briefly described below.

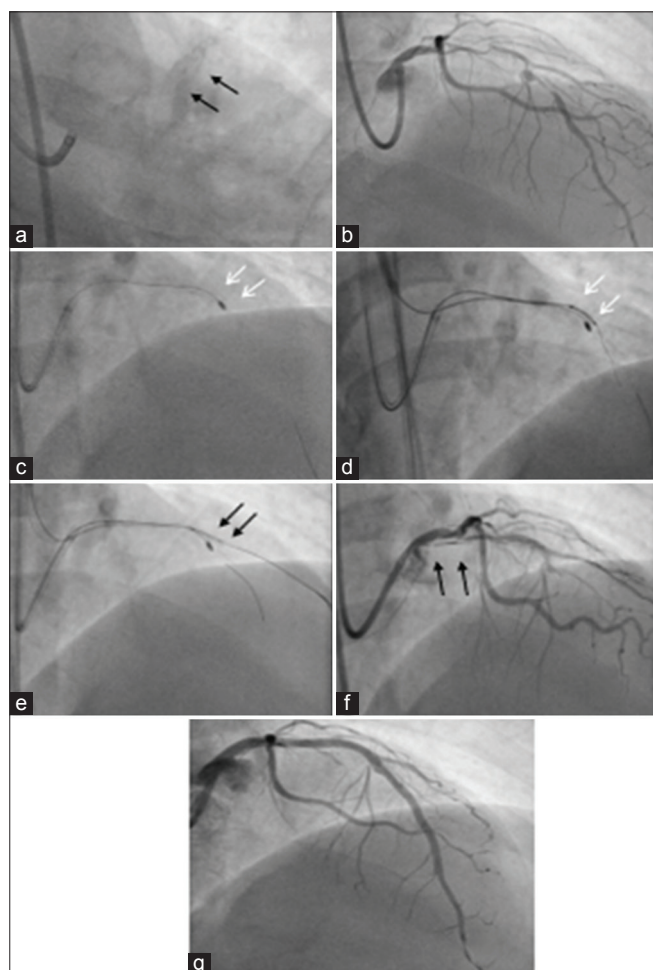
Here we have described in detail, the two endovascular maneuvers used at our center for retrieval of the stuck RA burr.

### Retrieval of stuck burr using the novel side branch dilation method

A 56-year male was referred to our center with a diagnosis of unstable angina, coronary angiography revealed stenosis of mid LAD with severe calcification. A pre-procedure intravascular ultrasound (IVUS) was done which revealed a 90 – 95% stenosis with severe calcification (>270°) calcium in the proximal segment with medina (1,1,0) lesion at the diagonal bifurcation with calcification. We selected a 7 Fr Extra Backup (EBU) guiding catheter (Medtronic, Minneapolis, MN, USA) and a Hi-torque BMW wire (Abbott Vascular, Abbott Park, IL) was used initially to cross the lesion, but due to severe calcification and tortuosity, it could not be passed. Because of calcification, we decided to debulk the lesion using (RotaLink Plus 1.5 mm, Boston Scientific, Marlborough, MA), the ROTAWire Extra Support Guide Wire (Boston Scientific, Marlborough, MA) was negotiated across the lesion and sequential balloon dilatation with the non-compliant balloon of size 2.5\*15mm and 3.0\*12 mm (NC-TREK, Abbott Vascular, Abbott Park, IL). The burr negotiated the lesion but was stuck distal to the lesion and could not be retrieved.

There was no decrease in coronary perfusion (Thrombolysis In Myocardial Infarction [TIMI III]) but the patient suffered from severe anginal pain. Through a second contralateral transfemoral access, we introduced an additional 7 Fr guiding catheter and tried to wire the distal LAD negotiating the stuck burr but despite

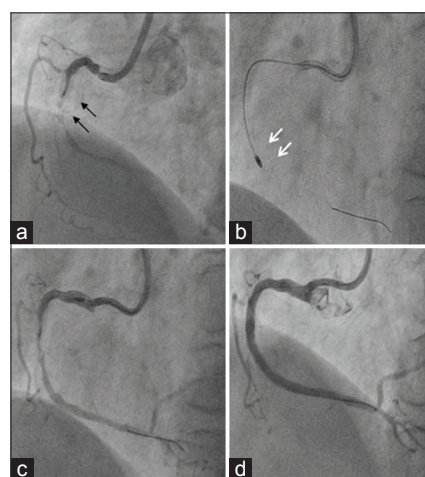
escalating wire to FIELDER XT, FC, and Gaia First guidewire (all Asahi Intecc, Nagoya, Japan) and multiple attempts, we were not able to wire distal LAD. As the entrapment of the rotablator burr was at 2<sup>nd</sup> diagonal bifurcation we were able to negotiate the diagonal and using a MINI-TREK semi-compliant balloon was placed at its ostium and dilated at high pressure sequentially with 1.5, 2.2, and 3.0 mm balloon. This enabled retrieval of burr with some force but there was an extensive dissection of left main and proximal LAD which was stented under IVUS guidance with 3 drug-eluting stents with TIMI III flow and good angiographic results as shown in Figure 1.



**Figure 1:** Case 1. a) Baseline plain fluoroscopic view showing dense calcium around proximal LAD and LM. b) RAO cranial view showing obstructive lesion (90-95%) from proximal to mid LAD. c) 1.5 mm rotablator burr stuck (white arrows) distal to the lesion in distal LAD. d) Using opposite arterial access another GW was passed negotiating the stuck burr and a small balloon (2.0\*8 mm MINI-TREK, Abbott Vascular,) was inflated (white arrows), but the burr could not be retrieved. e) Another balloon (2.0\*8 mm MINI-TREK, Abbott Vascular, Abbott Park, IL) was placed at the ostium of the side-branch (2<sup>nd</sup> diagonal) due to proximity to the stuck burr and inflated. f) Due to manipulation maneuvers there was an extensive dissection of the LM artery (black arrows). g) Good angiographic results with TIMI III flow was achieved after stenting with 3 DES from LM to distal LAD

### Retrieval of stuck RA burr using the combined approach of pharmaceutical dilatation of vessel and manual traction

A 64-year female with a diagnosis of chronic stable angina was referred for coronary angiography which revealed a heavily calcified, 90% obstructive lesion of the mid-right coronary artery (RCA). The patient was planned for PCI with a debulking strategy using rotablation, 7 Fr Judkins Right (JR) guiding catheter (Medtronic, Minneapolis, MN, USA), and a Hi-torque BMW wire (Abbott Vascular, Abbott Park, IL) was used initially to cross and the lesion was pre-dilated with a non-compliant balloon of 3.0\*15mm (NC-TREK, Abbott Vascular, Abbott Park, IL). Following that using a 135 cm Corsair microcatheter (Asahi Intecc, Nagoya, Japan) the BMW wire was exchanged with the ROTAWire Extra Support Guide Wire (Boston Scientific, Marlborough, MA) was negotiated across the lesion. Rotablation with RotaLink Plus 1.5 mm burr size (Boston Scientific, Marlborough, MA) was planned, but after negotiating the burr across the lesion it got stuck and could not be retrieved. The first manual traction for removal was tried but the burr was deeply engaged in the lesion making it difficult to apply traction force without the deep engagement of the guiding catheter. Following that an intracoronary bolus injection of nitroprusside (100 micrograms) and verapamil (1 mg over 1 minute) was given, and manual traction was tried which moved the burr, but full retrieval was not possible. After that, we increased the rotation speed and advanced it further distally in RCA and applied manual traction, and were finally able to retrieve the burr in the guiding catheter. RCA was stented using 2 DES with good angiographic results as shown in Figure 2.



**Figure 2:** Case 2. a) Baseline angiography showing heavily calcified 99% (black arrows) obstructive lesion of the proximal right coronary artery. b) A 1.5 mm rotablator burr got stuck at the distal edge of the calcified lesion (white arrows). c) Post pharmacological treatment (intracoronary nitroprusside and verapamil) with simultaneous mechanical pull back the burr was retrieved in the proximal RCA with long dissection of RCA. d) RCA is stented with a drug-eluting stent (DES) with good angiographic TIMI III flow



## PUBLISHED EXPERIENCE

Screening the result from our search on PubMed we shortlisted in total 8 techniques reported in different case series and case reports used for retrieval of entrapped rotablator burr by the endovascular maneuver. In literature surgical removal of stuck burr was frequent but due to the invasive nature of the surgery, time in shifting the hemodynamically unstable patients from catheterization lab to operation theater, and the non-availability of a hybrid Cath lab makes this job difficult. But surgery remains an ultimate option if percutaneous methods fail or create complications that could not be managed percutaneously like avulsion of coronary artery requiring reimplantation or reconstruction. Here in Table 2, we have enumerated and briefly discussed a few methods of percutaneous retrieval of entrapped rotablator burr.

## DISCUSSION

The main utilization of RA is for the modification of severely calcified lesions and preparing them for subsequent angioplasty and stenting. Although it's using does not alter any long-term ischemic events,<sup>23,24</sup> but its use has shown to be associated with greater acute diameter gain, less final stenosis, and a greater luminal cross-sectional area gain when compared with the non-atherectomy approach.<sup>23</sup>

RA has a high procedural success rate<sup>10</sup> but due to inherent risks and complications, its use is frequently underutilized. Entrapment of rotablator burr is a serious complication, but its incidence is an exceedingly rare phenomenon, which can be avoided with proper selection of lesion and easily managed with endovascular manipulations which are the principal conclusion of this study.

### Mechanism of burr entrapment

Entrapment of burr is a complication due to the intrinsic flaws of RA burr design. A burr is olive-shaped with a distal diamond-studded ablating edge and proximal half, which is smooth and non-ablating, which may be a cause of entrapment in non-compliant lesions when pulling back the burr. Another factor that can be synergistic in entrapment is that while moving forward burr is aligned to the outer curve of the vessel wall while it is aligned to the inner curve when we withdraw and in the eccentric calcified lesion, it can lead to burr entrapment.<sup>13</sup>

Most of the expert opinion on the matter of optimal burr to vessel ratio suggests using a burr to vessel ratio of 0.4-0.6.<sup>25</sup> There is no definition for small or large burr

for a given procedure. The entrapment can occur in small or large burr procedure. The mechanism appears to differ in both cases.

### Small RA burr (Kokesi phenomenon)<sup>22</sup>

Small burr gets advanced beyond heavily calcified lesion before sufficient ablation. This appears mainly when ablation is done at exceedingly high speed with a small burr. During high-speed rotation, frictional resistance is low, and locally produced heat enlarges the space between the plaques. This led to the advancement of burr beyond the calcific lesion without ablation and debulking proximal lesion.

### Large RA burr

Large burr entrapment occurs when they are forced against angulated and long calcific lesions without sufficient pecking motion. A significant drop in RPM (rotations per minute) precedes such entrapment.

Lesion characteristics that are prone to burr entrapment, like eccentric severely calcified lesion, lesion angulation  $>45^\circ$ , and lesion length  $>25$  mm<sup>26,27</sup> freshly implanted under expanded stent,<sup>13</sup> large burr to artery ratio,<sup>13</sup> and old reendothelized stent.

## MANAGEMENT OF STUCK ROTABLATOR BURR

The most used method in the literature was surgical removal followed by coronary bypass grafting. Percutaneous endovascular interventional approaches for entrapped rotablator burr can be divided into two groups:

- I. Dilatation of the stuck burr site with a balloon (key point is to cross the stuck burr site with a coronary wire such as Fielder FC, XT, XT-R guidewire, Gaia First guidewire, and Conquest Pro guidewire (all AsahiIntecc, Nagoya, Japan))
- II. Facilitated removal of burr using deep intubation of catheters so as the tractional force can be directed directly to the burr. (using a Heartrail II (Terumo, Japan) "mother in child catheter", 5F Guideliner (Vascular Solutions, Inc., Minneapolis, Minnesota), Kiwami straight catheter (4 Fr, Heartrail II, Terumo, Tokyo, Japan) or a GUIDEZILLA II (Guide Extension Catheter, BostonScientific))

To remove a stuck burr usually after the failure of manual mechanical traction and drugs (nitroprusside/verapamil), it is advised to gain additional arterial access and use a second guiding catheter for facilitating interventional maneuvers. Another reason for additional arterial access is the limitation of space in the rotablation

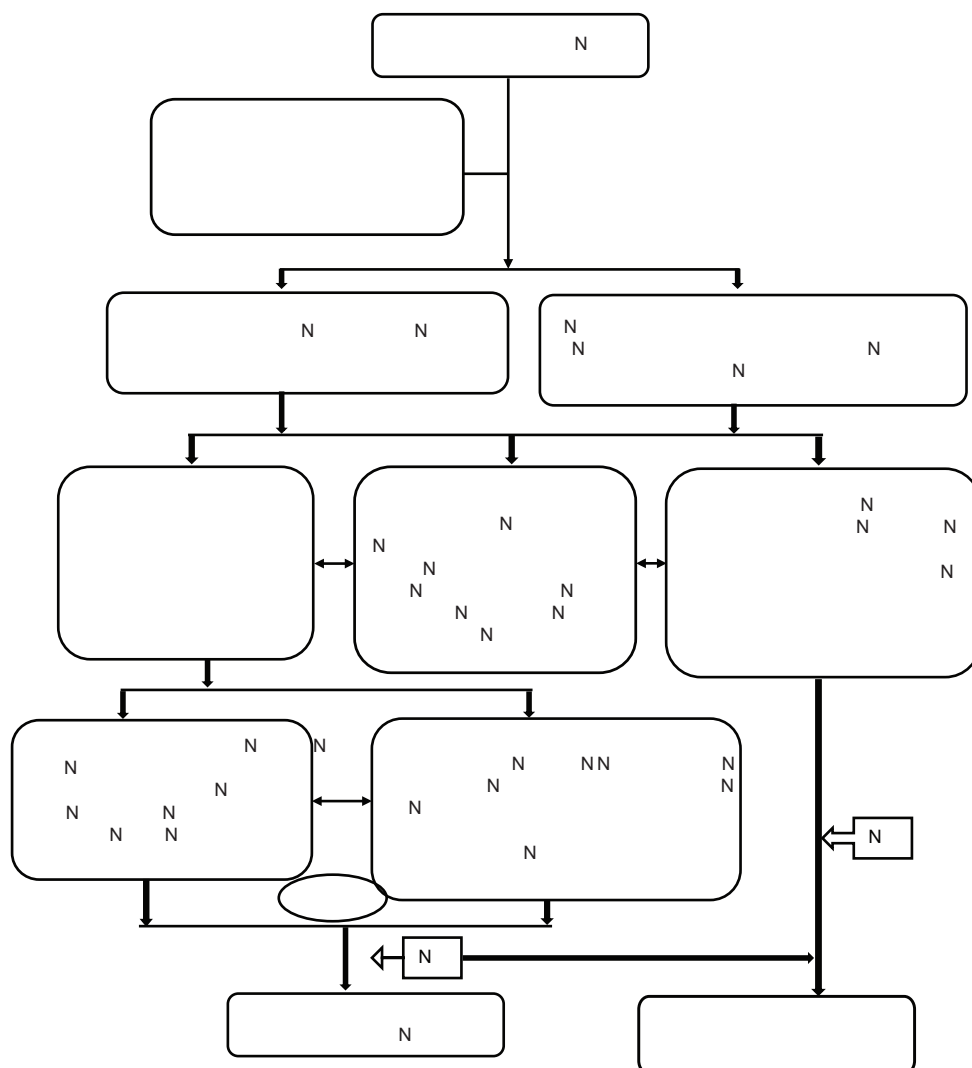
**Table 2: Different techniques for removal of entrapped rotablator burr**

Serial no	Strategic method	Mechanism	Comment
1	Intracoronary nitroglycerin and/or verapamil <sup>11,12</sup>	Relieves spasm	Effective if rotaglide®/vasodilator solution is not used due to specific contraindication, additive to other mechanisms, not possible in a hemodynamically unstable patient.
2	Manual traction <sup>13</sup>	Pull back pressure	Should be graded, simultaneous traction on the guide as well as a burr to avoid deep guide intubation leading to the dissection of the proximal vessel or LM, Perforation, proximal vessel injury, and avulsion
3	Increase the speed of rotation and advance distally <sup>12</sup>	Increase to $\geq 2,00,000$ r/min	Risk of perforation, distal vessel injury, try in small burr to vessel procedures.
4	Second GW beyond the entrapped burr (hydrophilic-coated wire, stiffer wire) <sup>14,15</sup>	Balloon dilatation cracks the plaque between the burr and vessel wall	Difficulty in crossing, perforation (due to hard wire as well as a balloon). Wiring through the same guide is difficult requires dis-assembling or Cutting of ROTA hub outside the guide. Ping pong guide technique through another access (repeated engaging maneuvers increases chances of LM dissection, in absence of distal vessel flow presences of wire in true lumen could not be confirmed (may require retrograde injection (3 <sup>rd</sup> access)
5	Snare retrieval <sup>16</sup>	locally concentrated traction force at burr	Dis-assembling or Cutting of ROTA hub is necessary, simultaneous traction on guide, snare, and burr to avoid deep guide intubation proximal injury, LM injury
6	Mother and child catheter/ 5 Fr guiding catheter <sup>17,18</sup>	locally concentrated traction force at burr	Dis-assembling or Cutting of ROTA hub required. Postulated to protect the proximal vessel from injury, taking mother and child to burr can be a difficult job in calcified, tortuous, or dissected artery. Proximal vessel dissection is possible.
7	Guideliner/guide catheter extension <sup>19</sup>	locally concentrated traction force at burr	Dis-assembling or Cutting of ROTA hub required. Postulated to protect the proximal vessel from injury, taking guideliner to burr can be a difficult job in calcified, tortuous, or dissected artery
8	Kiwami Straight Catheter <sup>20</sup>	locally concentrated traction force at burr	Dis-assembling or Cutting of ROTA hub required. Postulated to protect the proximal vessel from injury, taking Kiwami catheter to burr can be a difficult job in calcified, tortuous, or dissected artery
9	Mini STAR/modified STAR technique <sup>21</sup>	Sub-intimal tracking and reentry technique followed by balloon dilatation to modify plaque at stuck burr site.	Difficulty in crossing, perforation (due to hard wire as well as a balloon), Wiring through the same guide is difficult requires dis-assembling or cutting rota outside the guide and remove the coating in it, ping pong guide technique through another access (repeated engaging maneuvers increases chances of LM dissection, in absence of distal vessel flow presences of wire in true lumen could not be confirmed(may require retrograde injection(3 <sup>rd</sup> access)
10	Surgical <sup>22</sup>	Direct removal	Invasive. Increased mortality with a hemodynamically unstable patient May require vessel reconstruction or reimplantation (more complex than putting a graft)
11	Side branch dilatation and burr squeezing technique (a newer novel technique)	Balloon dilatation modifies the main branch plaque by carinal shift and plaque squeeze at the site of stuck burr.	Wiring through the same guide is difficult requires dis-assembling or cutting the ROTA shaft outside the guide and remove the coating in it, ping pong guide technique through another access. Burr should be stuck in the proximity of the side branch, acute angle between the main vessel and side branch, it is easy to wire side branch and safe to dilate reduces the risk of perforation

LM= left main coronary artery; GW= guidewire; Fr= French

sheath (4.6 Fr) which makes it difficult to manipulate additional devices for stuck burr retrieval. To overcome and avoid an additional arterial access dis-assembly of rotablation can be done outside which helps in utilizing

the same guide for maneuvers. Deep intubation with guiding catheters with subsequent pullback can be useful to focus the force on the burr and to protect the rest of the coronary artery.



**Figure 3:** Algorithm for management of entrapped rotator burr.

We, therefore, propose a working algorithm based on our experience and the database search as shown in Figure 3.

### PREVENTION OF BURR ENTRAPMENT

Appropriate selection of lesion characteristics, prior planning, and appropriate hardware selection is always a key to success for any intervention procedure.

1. Selection of lesion: Rotablation is mainly done for a severe intimal calcific lesion which does not allow hardware delivery, stent placement, and opposition. But it is very crucial not to select lesion which increased the risk of burr entrapment.
  - a) Freshly implanted under expanded stent
  - b) Eccentric calcified lesion and angulated lesions
  - c) Focal tandem calcific lesion
  - d) Intravascular imaging: intracoronary imaging like IVUS (intravascular ultrasound) or OCT (optical

coherence tomography) helps to verify the location of calcium superficial or deep. A deeper and more circumferential calcium ring is resistant to balloon dilatation

2. Appropriate hardware selection and proper technique of ablation: to prevent entrapment during the procedure if the lesion appears at risk of entrapment one can use the following technique<sup>25</sup>
  - a) Appropriate burr to artery ratio (0.4-0.6)
  - b) Peeking motion during rotablation
  - c) Short runs (up to 20 sec)
  - d) The rotational speed of 140 000 to 150 000 rpm, with higher speeds reserved for cases in which burr cannot cross lesion despite the optimal technique
  - e) Avoidance of deceleration of >5000 RPMs

### Limitations of the study

Our study lacks formal statistical analysis as the number of stuck burr cases were very less and the algorithm proposed

is based on single-center experience and its application on the general population requires larger studies.

## CONCLUSION

Rotational atherectomy burr entrapment is rare, but a life-threatening complication, and the operator should be prepared with strategies for successful retrieval of stuck burr. Percutaneous retraction maneuvers should be used as the first-line management for retrieval of stuck burr followed by surgical referral. Using the proposed algorithm this rare complication can be managed systematically and effectively.

## REFERENCES

- Généreux P, Madhavan MV, Mintz GS, Akiko M, Tullio P, Laura L, et al. Ischemic outcomes after coronary intervention of calcified vessels in acute coronary syndromes. Pooled analysis from the HORIZONS-AMI (Harmonizing Outcomes With Revascularization and Stents in Acute Myocardial Infarction) and ACUITY (Acute Catheterization and Urgent Intervention Triage Strategy) TRIALS. *J Am Coll Cardiol*. 2014;63(18):1845-1854.  
<https://doi.org/10.1016/j.jacc.2014.01.034>
- Bourantas CV, Zhang YJ, Garg S, Iqbal J, Valgimigli M, Windecker S, et al. Prognostic implications of coronary calcification in patients with obstructive coronary artery disease treated by percutaneous coronary intervention: a patient-level pooled analysis of 7 contemporary stent trials. *Heart*. 2014 Aug;100(15):1158-1164.  
<https://doi.org/10.1136/heartjnl-2013-305180>
- Barbato E, Shlofmitz E, Milkas A, Shlofmitz R and Azzalini L, Colombo A. State of the art: evolving concepts in the treatment of heavily calcified and undilatable coronary stenoses - from debulking to plaque modification, a 40-year-long journey. *Euro Intervention*. 2017;13(6):696-705.  
<https://doi.org/10.4244/EIJ-D-17-00473>
- Lee MS, Yang T, Lasala J and Cox D. Impact of coronary artery calcification in percutaneous coronary intervention with paclitaxel-eluting stents: Two-year clinical outcomes of paclitaxel-eluting stents in patients from the ARRIVE program. *Catheter Cardiovasc Interv*. 2016;88(6):891-897.  
<https://doi.org/10.1002/ccd.26395>
- Moussa I, Di Mario C, Moses J, Reimers B, Francesco LD, Martini G, et al. Coronary stenting after rotational atherectomy in calcified and complex lesions. *Angiographic and clinical follow-up results*. *Circulation*. 1997;96(1):128-136.  
<https://doi.org/10.1161/01.CIR.96.1.128>
- Shimony A, Zahger D, Van Straten M, Gilutz H, Llia R and Cafri C. Incidence, risk factors, management and outcomes of coronary artery perforation during percutaneous coronary intervention. *Am J Cardiol*. 2009;104(12):1674-1677.  
<https://doi.org/10.1016/j.amjcard.2009.07.048>
- Fitzgerald PJ, Ports TA and Yock PG. Contribution of localized calcium deposits to dissection after angioplasty. An observational study using intravascular ultrasound. *Circulation*. 1992;86(1):64-70.  
<https://doi.org/10.1161/01.CIR.86.1.64>
- Witzenbichler B, Maehara A, Weisz G, Franz-Josef Neumann FJ, Rinaldi MJ, Metzger DC, et al. Relationship between intravascular ultrasound guidance and clinical outcomes after drug-eluting stents: the assessment of dual antiplatelet therapy with drug-eluting stents (ADAPT-DES) study. *Circulation*. 2014;129(4):463-470.  
<https://doi.org/10.1161/CIRCULATIONAHA.113.003942>
- Dill T, Dietz U, Hamm CW, R Küchler, Rupprecht HJ, Haude M, et al. A randomized comparison of balloon angioplasty versus rotational atherectomy in complex coronary lesions (COBRA study). *Eur Heart J*. 2000;21(21):1759-1766.  
<https://doi.org/10.1053/euhj.2000.2242>
- Rheude T, Toelg R, Byrne RA, Allali A, Wiebe1 J, Sulimov DS, et al. Outcomes of rotational atherectomy versus modified balloon angioplasty in severely calcified coronary lesions based on target lesion location: a post hoc analysis of the PREPARE-CALC randomised trial. *EuroIntervention*. 2020;16(4):e322-e324. Published 2020 Jul 17.  
<https://doi.org/10.4244/EIJ-D-19-00488>
- Grise MA, Yeager MJ and Teirstein PS. A case of an entrapped rotational atherectomy burr. *Catheter Cardiovasc Interv*. 2002;57(1):31-33.  
<https://doi.org/10.1002/ccd.10263>
- De Vroey F, Velavan P, El Jack S and Webster M. How should I treat an entrapped rotational atherectomy burr?. *EuroIntervention*. 2012;7(10):1238-1244.  
<https://doi.org/10.4244/EIJV7110A197>
- Sulimov DS, Abdel-Wahab M, Toelg R, Kassner G, Geist V and Richardt G. Stuck rotablator: the nightmare of rotational atherectomy. *EuroIntervention*. 2013;9(2):251-258.  
<https://doi.org/10.4244/EIJV912A41>
- Hyogo M, Inoue N, Nakamura R, Tokura T, Matsuo A, Inoue K, et al. Usefulness of conquest guidewire for retrieval of an entrapped rotablator burr. *Catheter Cardiovasc Interv*. 2004;63(4):469-472.  
<https://doi.org/10.1002/ccd.20232>
- Sakakura K, Ako J and Momomura S. Successful removal of an entrapped rotablation burr by extracting drive shaft sheath followed by balloon dilatation. *Catheter Cardiovasc Interv*. 2011;78(4):567-570.  
<https://doi.org/10.1002/ccd.22957>
- Prasan AM, Patel M, Pitney MR and Jepson NS. Disassembly of a rotablator: getting out of a trap. *Catheter Cardiovasc Interv*. 2003;59(4):463-465.  
<https://doi.org/10.1002/ccd.10611>
- Kimura M, Shiraishi J and Kohno Y. Successful retrieval of an entrapped Rotablator burr using 5 Fr guiding catheter. *Catheter Cardiovasc Interv*. 2011;78(4):558-564.  
<https://doi.org/10.1002/ccd.22995>
- Cunnington M and Egred M. GuideLiner, a child-in-a-mother catheter for successful retrieval of an entrapped rotablator burr. *Catheter Cardiovasc Interv*. 2012;79(2):271-273.  
<https://doi.org/10.1002/ccd.23032>
- Chiang CH and Liu SC. Successful Retrieval of an Entrapped Rotablator Burr by Using a Guideliner Guiding Catheter and a Snare. *Acta Cardiol Sin*. 2017;33(1):96-98.  
<https://doi.org/10.6515/ACS20160404A>
- Kanazawa T, Kadota K and Mitsudo K. Successful rescue of stuck rotablator burr entrapment using a Kiwami straight catheter. *Catheter Cardiovasc Interv*. 2015;86(5):942-945.  
<https://doi.org/10.1002/ccd.25903>
- Tanaka Y and Saito S. Successful retrieval of a firmly stuck rotablator burr by using a modified STAR technique. *Catheter Cardiovasc Interv*. 2016;87(4):749-756.  
<https://doi.org/10.1002/ccd.26342>

22. Kaneda H, Saito S, Hosokawa G, Tanaka S and Hiroe Y. Trapped Rotablator: kokesi phenomenon. *Catheter Cardiovasc Interv.* 2000;49(1):82-85.  
[https://doi.org/10.1002/\(SICI\)1522-726X\(200001\)49:1<82::AID-CCD18>3.0.CO;2-X](https://doi.org/10.1002/(SICI)1522-726X(200001)49:1<82::AID-CCD18>3.0.CO;2-X)
23. Abdel-Wahab M, Richardt G, Joachim Büttner H, Toelg R, Geist V, Meinertz T, et al. High-speed rotational atherectomy before paclitaxel-eluting stent implantation in complex calcified coronary lesions: the randomized ROTAXUS (Rotational Atherectomy Prior to Taxus Stent Treatment for Complex Native Coronary Artery Disease) trial. *JACC Cardiovasc Interv.* 2013;6(1):10-19.  
<https://doi.org/10.1016/j.jcin.2012.07.017>
24. de Waha S, Allali A, Büttner HJ, Toelg R, Geist V, Neumann FJ, et al. Rotational atherectomy before paclitaxel-eluting stent implantation in complex calcified coronary lesions: Two-year clinical outcome of the randomized ROTAXUS trial. *Catheter Cardiovasc Interv.* 2016;87(4):691-700.  
<https://doi.org/10.1002/ccd.26290>
25. Sharma SK, Tomey MI, Teirstein PS, Kini AS, Tomey MI, Teirstein PS, et al. North American Expert Review of Rotational Atherectomy. *Circ Cardiovasc Interv.* 2019;12(5):e007448. doi:10.1161/CIRCINTERVENTIONS.118.007448  
<https://doi.org/10.1161/CIRCINTERVENTIONS.118.007448>
26. Kawamoto H, Latib A, Ruparelina N, Boccuzzi GG, Pennacchi M, Sardella G, et al. Planned versus provisional rotational atherectomy for severe calcified coronary lesions: Insights From the ROTATE multi-center registry. *Catheter Cardiovasc Interv.* 2016;88(6):881-889.  
<https://doi.org/10.1002/ccd.26411>
27. Iannaccone M, Barbero U, D'ascenzo F, Latib A, Pennacchi M, Rossi ML, et al. Rotational atherectomy in very long lesions: Results for the ROTATE registry. *Catheter Cardiovasc Interv.* 2016;88(6):E164-E172.  
<https://doi.org/10.1002/ccd.26548>

**Author's Contribution:**

**AR** - Investigation, conceptualization, and review and editing; **RKN** - Investigation, supervision, and review and editing; **APS** - Concept and design of the study, writing - original draft; **NP** - Formal analysis and supervision; **AKT, SVK** - review and editing.

**Work Attributed to:**

Atal Bihari Vajpayee Institute of Medical Sciences (ABVIMS) & Dr. Ram Manohar Lohia Hospital, New Delhi, India.

**Orcid ID:**

Dr. Ajay Raj - <https://orcid.org/0000-0002-8297-3409>  
Dr. Ranjit Kumar Nath - <https://orcid.org/0000-0002-8258-0445>  
Dr. Ashok Kumar Thakur - <https://orcid.org/0000-0001-6502-5717>  
Dr. Ajay Pratap Singh - <https://orcid.org/0000-0003-3127-6539>  
Dr. Neeraj Pandit - <https://orcid.org/0000-0001-9772-1338>  
Dr. Sripad Vasant Khairnar - <https://orcid.org/0000-0001-8081-5207>

**Source of funding:** None, **Conflict of Interest:** None.