

A cadaveric study on the variations of the profunda femoris artery in South India



Anne George¹, Maheswary Thampi Santhakumary²

¹Associate Professor, ²Assistant Professor, Department of Anatomy, Government Medical College Kottayam, Kerala, India

Submission: 27-09-2020

Revision: 23-11-2020

Publication: 01-02-2021

ABSTRACT

Background: The knowledge of the variations in the branching patterns of the arteries in the femoral triangle is important to avoid iatrogenic injury to the vessels during clinical procedures. **Aims and Objectives:** The study was designed to explore the varying positions of the origin of the profunda femoris artery from the femoral artery. **Materials and Methods:** We have dissected the thighs of 60 embalmed bodies. The midpoint between the anterior superior iliac spine and the pubic symphysis was marked (midinguinal point). The distance of the point of origin of profunda femoris artery (PFA) from the femoral artery (FA) to the midinguinal point (MIP) was measured by black silk thread and scale. The relation of PFA to FA at its origin was noted. **Results:** In the majority of the cases, the PFA was found to arise posterolaterally from the FA. In 63.3% of the cases, PFA was found to arise posterolaterally from the FA, while in 21.5% of cases it took origin laterally from it. In majority of the cases, the PFA arose at a distance of 3-6 cms from midinguinal point while a considerable number originated more distally. **Conclusion:** PFA exhibits significant variations. Posterolateral origin from FA was the most common mode of origin.

Key words: Cadaveric; Profunda femoris artery; Midinguinal point; Postereolateral

Access this article online

Website:

<http://nepjol.info/index.php/AJMS>

DOI: 10.3126/ajms.v12i2.31547

E-ISSN: 2091-0576

P-ISSN: 2467-9100

Copyright (c) 2021 Asian Journal of Medical Sciences



This work is licensed under a Creative Commons Attribution-NonCommercial 4.0 International License.

INTRODUCTION

Profunda femoris artery (PFA) is the largest branch of femoral artery (FA). It is also called the deep femoral artery. It arises from the posterolateral aspect of the FA 3.5cm distal to midinguinal point (MIP). It spirals posterior to the FA and femoral vein between pectineus and adductor longus muscles. It gives muscular branches, medial and lateral circumflex femoral arteries, and four perforating arteries described in relation to adductor brevis the key muscle of the adductor compartment.¹

Clinicians name the FA above the origin of PFA as the common femoral artery and that below the origin of the profunda femoris artery as the superficial femoral artery.^{2,3} The PFA supplies muscles of extensor, flexor and adductor compartments, also the head and neck of femur.⁴ The FA and PFA are usually used for catheterization in various

diagnostic procedures. Due to the relation of PFA with the femur and the hip bone there may be chances of development of aneurysms after penetrating injuries during internal and external fixation of hip bone, and during catheterization.⁵⁻⁸ The main aim of the present study was to identify the varying positions of origin of PFA from FA and to compare the results of these variations in South Indian population with those of other studies.

MATERIALS AND METHODS

A descriptive study was conducted on 60 cadaveric specimens of lower limbs (30 right and 30 left) available in the department. The midpoint of the inguinal region (MIP) was marked using skin marker pen. Using surgical scalpel a skin incision was made from the anterior superior iliac spine to the pubic tubercle and a vertical incision 15cm long down from the MIP. The skin was reflected and the

Address for Correspondence:

Dr. Maheswary Thampi Santhakumary, Assistant Professor, Department of Anatomy, Government Medical College, Kottayam, Kerala, India.

Mobile No: +91-9446314553. **E-mail:** drsmthampi@gmail.com

inguinal ligament and femoral vessels were exposed by dissection. The PFA was identified and its site and mode of origin were noted. The distance between the origin of PFA from the FA and the mid inguinal point (MIP) was measured using black silk thread and scale (Figure 1). The relation of profunda femoris artery to FA at its origin was noted. The mode of origin and pattern of origin of PFA from the femoral artery were also noted.

According to a study⁹ on the variations in PFA and its branches, the authors have found an incidence of 62.5% for the origin of PFA from the posterolateral aspect of FA. The formula for calculating the sample size in a descriptive study given below was used.

$$N = \frac{3.84PQ}{D^2}$$

Where P is the incidence in previous study, Q is 100-P and D 20% of P. Here, P=62.5%, Q=37.5.97%, D is 12.5 and N is the sample size and N =56.25. So, we have taken 60 as the sample size.

Ethical approval

Permission was obtained from institutional review board on 15th March 2019, with IRB number 101/2018.

Statistics

Continuous variables are expressed as means and standard deviations and categorical variables are stated as numbers and percentages.

RESULTS

Site of origin of profunda femoris artery

The observations in Figure 2 show the origin of PFA from various aspects of femoral artery. On the right side we found 7 cases where PFA arose from the lateral aspect of FA (ie 23.3% of total right cases), 2 cases from the posterior aspect (ie 6.67% of total right cases), 1 case from the medial aspect (ie 3.33% of total right cases), 1 case from anterolateral aspect (ie 3.33% cases of total right cases), 1 case from the posteromedial aspect (ie 3.33% cases of total right cases) and 18 cases from the posterolateral aspect (ie 60% cases of total right cases).

On the left side we found 6 cases arose from the lateral aspect of FA.(ie 20% of total left cases), 2 cases from the posterior aspect (ie 6.67% of total left cases), 1 case from the medial the aspect (ie 3.33% of total left cases) 1 case from the posteromedial aspect (ie 3.33% cases of total left cases) and 20 cases from the posterolateral aspect (ie 66.67% cases of total left cases). We could not find any

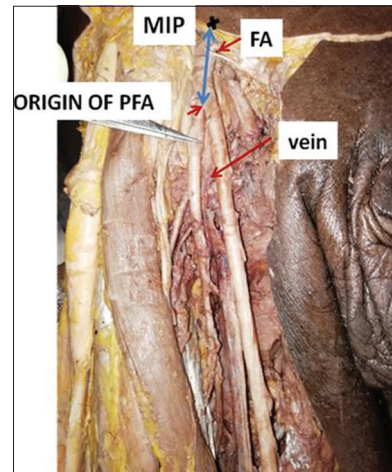


Figure 1: Showing the PFA and the distance of its origin from MIP measured

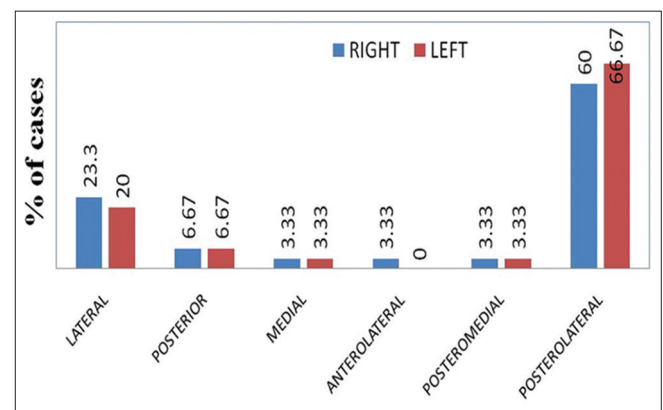


Figure 2: Origin of PFA from various aspects of femoral artery

cases arising from the anterolateral aspect. Thus of the total cases, we obtained a mean of 21.65% of cases arising from lateral aspect of FA, 6.67% of cases from the posterior aspect, 3.33% of cases from the medial aspect, 1.67% of cases from the anterolateral aspect, 3.33% of cases from the posteromedial aspect, 63.33% of cases from the posterolateral aspect. The most common position was posterolateral on both the right and left sides.

Distance of origin of PFA

Figure 3 show the distances of origin PFA from MIP. Most commonly PFA arises 3 to 6 cm from MIP. However, in 9 cases on the right side PFA arose at 9 to 12cms from MIP. On the left side we found 7 cases of PFA arising 0 to 3 cms from MIP.

Pattern of origin of profunda femoris artery

Figure 4 shows the pattern of origin of PFA from the FA. In 3.33 % of cases on the left side PFA arose as a common trunk with MCFA and in 6.67 % PFA originated as a common trunk with LCFA. However, in one case a trifurcation was noted that PFA originated from femoral

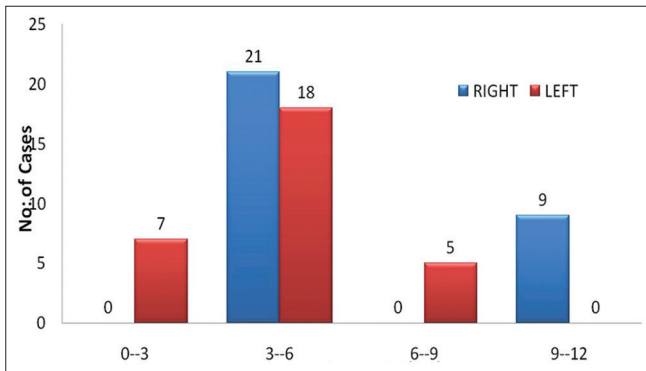


Figure 3: Distances of origin PFA from MIP

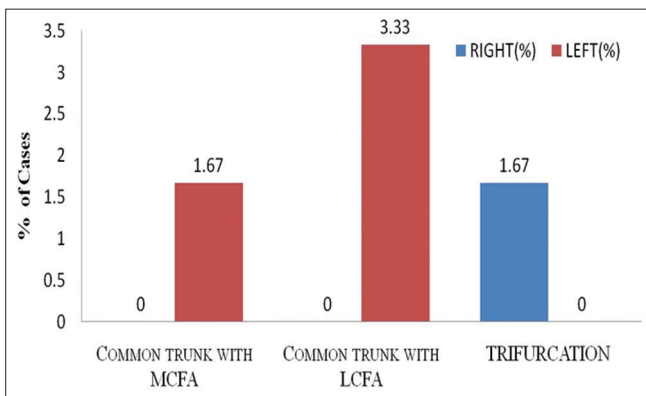


Figure 4: Pattern of origin of profunda femoris artery

artery with both circumflex arteries from a common point.

DISCUSSION

In literature, in the majority of the cases studied, the PFA is seen to take origin from the posterolateral aspect of the femoral artery (60%) while in 20% cases they arose laterally from it. Other origins even though fewer in numbers were also noted: posterior 7%, medial 2%, anterolateral 2% and posteromedial 3%.

Our study revealed that the PFA arose from the lateral aspect in 21.67 % (13 cases), from the posterior aspect in 6.67 % (4 cases), from the medial aspect in 3.33 % (2 cases) from the anterolateral aspect in 1.67 % (1 case), posteromedial aspect 3.33% (2 cases) and from posterolateral 63.33% (38 cases).

In a study by Prakash et al. in 50% of cases the mode of origin of the PFA was from the posterolateral aspect whereas Anjankar et al. found it to be 47.5% cases.^{10,11} A study on varying patterns of the origin of PFA in Thais was conducted by Thitilertdech et al.¹² Nagpal et al. also studied the varying patterns of the origin of PFA.⁹ Variations in the pattern of PFA and its branches are clinically very

important for procedures done in femoral triangle, to reduce the chances of intraoperative haemorrhages, post-operative complications, and for diagnostic imaging procedures. When the superficial femoral artery is occluded the PFA forms effective collaterals between the iliofemoral segment and popliteal artery and its branches.

Origin of PFA from the lateral aspect of FA was reported by Samarawickrama et al.¹³ Bergman et al. pointed out that if PFA arises from the medial aspect of FA, then FA may split into three vessels of almost equal caliber that are PFA, FA and lateral circumflex arteries.¹⁴

A rare and dangerous variation in which the PFA passed in front of the femoral vein in the left lower limb of a 43-year-old male cadaver has been reported by Sahinet al.¹⁵ This type of variation was also observed in 5 limbs by Dixit et al.¹⁶ The origin of PFA from the medial aspect from FA was 10.5% as observed by them. The branching pattern of PFA was classified by Kumar and Muralimanju¹⁷ into three types: type 1, type 2 and type 3. In type 1 both circumflex femoral arteries arose from PFA. In type 2 one of the circumflex arteries arose from PFA and the other from femoral artery. When both circumflex femoral arteries arose from the femoral artery it was classified as type 3. They reported that type 1 branching pattern was observed in 56.2% cases, type 2 in 39.6% cases and type 3 in 4.2% cases.

Shanahan et al. reported that the medial circumflex femoral artery was the main artery that supplies the femoral head and neck.¹⁸ The arterial supply of the femoral head was usually compromised after femoral neck fractures.

It was reported by Valdatta et al. that the branches of lateral circumflex femoral artery were used in anterolateral thigh flaps for reconstruction and by Sugawara et al. for aortopopliteal bypass.^{19,20} Chitra et al. reported that PFA was used for arteriography, ultrasound and doppler imaging, digital subtraction angiography and magnetic resonance imaging.²¹ Therefore clinicians, interventional radiologists and surgeons should be familiar with the variations of PFA and its branches. PFA is an important vessel for collateral circulation when femoral artery is occluded. For this function PFA should have a large caliber. The knowledge of the branching patterns of the arteries in the femoral triangle is important in avoiding iatrogenic injury to the vessels and helps in preventing femoral arteriovenous fistula when performing femoral artery puncture.²² An ultrasound examination of the upper thigh is advised by Sahn et al. before performing catheterization of femoral vessels and upper thigh surgical procedures. This will provide structural information about the femoral vessels and will be helpful in planning the catheterization.²³

In majority of the cases, the PFA arises at a distance of 3-6 cms from MIP while a considerable number arise more distally. In our study the distance of origin of PFA from MIP was 3-6cm in 21 cases on the right side and 18 cases on the left side. PFA arose as a common stem with MCFA in 3.3% cases and with LCFA in 6.67% cases on the left side. PFA was found to arise with LCFA and MCFA as a common trunk (trifurcation) in 3.33% cases on the right side. The average distance was 5.64 cm from MIP on right side and 4.8 cm on left side which gives an overall average of 5.22 cm.

Nagpal et al. reported that PFA arises from the lateral side of FA in 10% of cases.⁹ An incidence of 21.43% was reported by Thitilertdech et al. which is in agreement with our study.⁹ Our study gave an incidence of 3.33% for medial origin while 2.5% was reported by Nagpal et al., 3% by Rajani et al. and 10.55% by Sahin et al.^{9,15,24} In our study 63.33% (38 cases) PFA arose from the posterolateral aspect of FA. This is in agreement with other findings which reported incidences of 50% and 47.5%.^{9,11} In 3.33% cases PFA arose from the posteromedial aspect. Other studies reported 5% incidence for this type of origin.

For the distance of origin from MIP, in our study 21 cases on the right side and 18 cases on the left side PFA was found to arise between 3 and 5cm from MIP. A study reported the distance of origin of PFA from MIP on the right side to be between 41 and 52 mm whereas on the left side to be between 46 and 54mm¹⁵. The average distance of the origin of PFA from midpoint of inguinal ligament as reported by Dixit et al. was 47.5mm where as 35mm and 40mm was reported respectively by Williams et al. and Snell.^{25,26} The variations in the level of origin of PFA ranging from 10-30mm proximally to 60-70cm distally from MIP have been observed.²⁷

Arthroplasty of hip joint and many clinical procedures are done in the femoral triangle. Knowing the level and mode of origin of PFA is therefore of utmost clinical importance. Knowledge of variations in the level of origin of PFA is pertinent to prevent iatrogenic complications and severe haemorrhage. For cannulation of femoral artery the site of puncture is usually PFA or sometimes the superficial femoral artery. For reconstruction of lower limb and head and neck different types of flaps based on the perforators of PFA and the even the fourth perforator which is the continuation of PFA are used. In all these surgeries the variations in the level and mode of origin of PFA helps to plan the flaps to be used. PFA is used for cardiac catheterization, transarterial chemoembolization for the treatment of malignancy, arteriography in peripheral vascular diseases, doppler imaging, ultrasonography, angiography and magnetic resonance imaging. Good

knowledge of the course and branching patterns of the vessels in the femoral triangle are thus very important for surgeons and interventional radiologists.

CONCLUSIONS

Variations exist in the mode and pattern of origin of PFA. Our results are in agreement with those of previous studies. Posterolateral origin from PFA was the most common mode of origin.

ACKNOWLEDGEMENTS

We acknowledge Dr Shana Baby, Dr Margaret William postgraduates and Dr. Anju George Assistant Professor, Department of Anatomy, Government Medical College Kottayam, Kerala India for the technical support. Thanks are due to Dr. Hanna J Maria of Mahatma Gandhi University for helpful discussions in preparing the manuscript.

REFERENCES

1. Manjappa T and Prasana LC. Anatomical Variations of the Profunda Femoris Artery and Its Branches-A Cadaveric Study in South Indian Population. *Indian J Surg.* 2014; 288-292. <https://doi.org/10.1007/s12262-012-0677-3>
2. Standing S. Pelvic girdle, gluteal region and hip joint, Profunda femoris artery. *Gray's Anatomy, The anatomical basis of clinical practice.* 40th ed. Elsevier Churchill, Livingstone. 2008:1379-1380.
3. Hollinshead HW. *Anatomy for surgeons Vol 3.* 3rd ed, Harper and Row, Philadelphia,; 1974.407. <https://doi.org/10.1097/00006534-196812000-00020>
4. Moore K. Dalley. 2nd AF. *Clinically oriented anatomy.* 5ed. Lippincott Williams and Wilkins, Philadelphia, PA, USA: 2006:603-605. <https://doi.org/10.1111/j.1469-7580.2006.00537.x>
5. Kaplan JL and Allen RJ. Cost-based comparison between perforator flaps and TRAM flaps for breast reconstruction. *Plast Reconstr Surg.* 2000; 943-948. <https://doi.org/10.1097/00006534-200003000-00017>
6. Singh S, Arora S, Thora A, Mohan R, Sural S, Dhal A. Pseudoaneurysm of profunda femoris artery following dynamic hip screw fixation for intertrochanteric femoral fracture. *Chinese Journal of Traumatology.* 2013;16:233-6.
7. Keçeci B, Küçük L, Parıldar M, Özkayın N, Aktuğlu K. Pseudoaneurysm of arteria profunda femoris following the surgery of proksimal femur fracture: a case report. *Cumhuriyet Medical Journal.* 2013;35:250-4.
8. Massoud TF, and Fletcher EWL, 1997. Anatomical variants of the profunda femoris artery: an angiographic study. *Surgical and Radiologic Anatomy,* 19(2), pp.99-103.
9. Nagpal H, Chauhan R and Kalra S. Variations in the Origin of Profunda Femoris Artery and its Branches – A Cadaveric Study. *Int J Curr Res.* 2017; 63678-63681.
10. Kumar PJ, Bhardwaj AK, Jose BA, Yadav SK and

- Singh G. Variations in the origins of the profunda femoris, medial and lateral femoral circumflex arteries: a cadaver study in the Indian population, *Rom J Morphol Embryol.* 2010;51(1):167-167.
11. Anjankar VP, Panshewdikar PN, Thakre G, Mane U and Tekale V. Morphological study on branching pattern of Femoral artery: A Cadaveric study. *Asian J Biomed Pharm.* 2014;4(28):34.
 12. Thitilertdecha S, Rungruang T and Voraphattropas C. The origin of profunda femoris artery in Thais. *Siriraj Med J.* 2012; 34-36.
 13. Samarawickrama MB, Nanayakkara BG, Wimalagunaratna KW, Nishantha DG and Walawage UB. Branching pattern of the femoral artery at the femoral triangle: a cadaver study. *Galle Med J.* 2009; 14:31-34.
<https://doi.org/10.4038/gmj.v14i1.1169>
 14. Bergman RA, Afifi AK and Miyayichi R. Compendium of human anatomic variations. Urban & Schwarzenberg, Baltimore-Munich 1988:86-87.
<https://doi.org/10.1002/ca.21292>
 15. Sahin B, Uzun A, Emirzeoglu M, Kosif R and Bilgic S. A deep femoral artery passing in front of the femoral vein. *Folia Morphol.* 2003;62(2):143-146.
 16. Dixit D, Kubavat DM, Rathod SP, Patel MM and Singel TC. A study of variations in the origin of profunda femoris artery and its circumflex branches. *Int J Biol Med Res.* 2011; 1084-1089. Corpus ID: 3851734
 17. Kumar V and Murlimanju BV. Variability in the Origin of Lateral and Medial Circumflex Femoral Arteries: An Anatomical Study In South Indians. *Int J Anat Res.* 2014;2(4):692-696.
<https://doi.org/10.16965/ijar.2014.528>
 18. Shanahan D and Jordan RK. Rare origin of the inferior epigastric artery from an anomalous medial circumflex femoral artery. *The Journal of Anatomy.* 1997; 611-613.
<https://doi.org/10.1046/j.1469-7580.1997.19140611.x>
 19. Valdatta L, Tuinder S, Buoro M, Thione A, Faga A and Putz R. Lateral circumflex femoral arterial system and perforators of the anterolateral thigh flap: an anatomic study. *Ann Plast Surg.* 2002; 145-150.
<https://doi.org/10.1097/0000637-200208000-00006>
 20. Sugawara Y, Sato O, Miyata T, Kimura H, Namba T and Makuuchi M. Utilization of the lateral circumflex femoral artery as a midway outflow for aorto-popliteal grafting: Report of a case. *Surg Today.* 1998; 967-970.
<https://doi.org/10.1007/s005950050264>
 21. Chitra R. A rare variational anatomy of the profunda femoris artery. *Folia Morphol.* 2008; 67:157-158.
 22. Vaas F. Some considerations concerning the deep femoral artery. *Archivumchirurgicum Neerlandicum.* 1975 :25-34. PMID: 1155954
 23. Sahn DJ, Goldberg SJ, Allen HD, Valdes-Cruz LM, Canale JM, Lange L, et al. A new technique for non-invasive evaluation of femoral arterial and venous anatomy before and after percutaneous cardiac catheterization in children and infants. *Am J Cardiol.* 1982; 349-355.
[https://doi.org/10.1016/0002-9149\(82\)90512-4](https://doi.org/10.1016/0002-9149(82)90512-4)
 24. Rajani SJ, Ravat MK, Rajani JK and Bhedi AN. Cadaveric study of profunda femoris artery with some unique variations. *J Clin Diagn.* 2015; AC01- AC03.
<https://doi.org/10.7860/JCDR/2015/13913.5876>
 25. Williams PL, Bannister LH, Berry MM, Collins P, Dyson M, Dussek JE, et al. *Anatomy GS. The anatomical basis of medicine and surgery.* Gray's anatomy, 38th Edn. Churchill Livingstone, London. 1995:19-1995622.
<https://doi.org/10.1002/bjs.1800761258>
 26. Snell RS. *Clinical anatomy for medical students.* Little, Brown Medical Division; 1995.
<https://doi.org/10.1002/ca.980060313>
 27. Kulkarni SP and Nikade V. A Study of Branching Pattern of Femoral Artery in Femoral Triangle in Cadavers. *Int J Mod Trends Sci Technol.* 2013:53-201355.

Author's Contribution:

AG - Concept and design of the study, interpretation of results, reviewed the literature and manuscript preparation, revision of the manuscript; **MTS** - Concept and design of the study, statistical analysis and interpretation, prepared first draft of the manuscript and review of literature.

Work attributed to: Department of Anatomy, Government Medical College, Kottayam, Kerala, India.

Orcid ID:

Dr. Anne George - <https://orcid.org/0000-0001-8055-4529>

Dr. Maheswary Thampi Santhakumary - <https://orcid.org/0000-0002-6754-2766>

Source of funding: None, **Conflict of Interest:** None.