

Acute abdomen due to epiploic appendagitis



Submitted: 18-04-2019

Revised: 22-04-2019

Published: 01-05-2019

Dear Editor,

As you are aware, epiploic appendagitis is a rare cause of acute abdomen, and can mimic other pathologies for abdominal pain. It results from torsion and inflammation of an epiploic appendix, thereby leading to localized abdominal pain. Due to its vague presentation, the diagnosis can often be challenging.

A 24 year old male, with no known comorbidities, presented to Medicine department with severe left lower abdominal pain since morning. The pain was acute on onset and progressive with no other associated symptoms. On abdominal palpation, he had severe left iliac tenderness with no radiation. His vitals and other systemic examinations were normal. His blood investigations like complete blood counts, renal and liver functions, electrolytes and calcium were normal. Urine microscopy did not show any pus cells. Ultrasound imaging of the abdomen revealed an echogenic lesion (27 x 18 mm) with ill-defined margins adjacent to the distal descending colon, suggestive of epiploic appendagitis (Figure 1). He was given oral non-steroidal anti-inflammatory drugs (mefenamic acid) and paracetamol, following which his pain got relieved. He was advised contrast enhanced computed tomography of the abdomen, but due to financial restrains it was decided to do if his symptom persists. He continued the tablets for 2 days and stopped. On review after 5 days, he did not have any further episodes of abdominal pain.

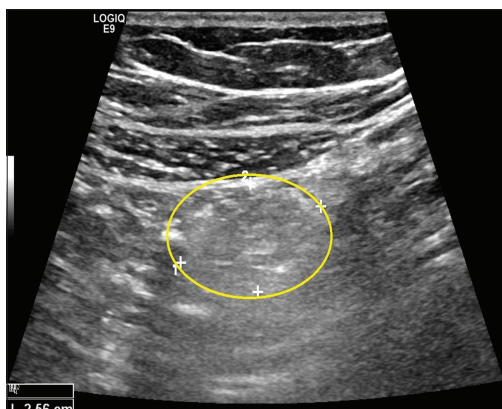


Figure 1: Ultrasound abdomen showing echogenic lesion in the left iliac fossa suggestive of epiploic appendagitis

Access this article online

Website:

<http://nepjol.info/index.php/AJMS>

DOI: 10.3126/ajms.v10i3.23656

E-ISSN: 2091-0576

P-ISSN: 2467-9100

Epiploic appendagitis refers to inflammation of one or more of the appendices epiploicae, which are small, serosa-covered fat pads attached to the outer surface of the colonic wall, measuring from 0.5 cm to 5 cm in length and 1 to 2 cm in width. There are nearly 100 appendages scattered throughout the peritoneal cavity.^{1,2} They are distributed along the rectosigmoid junction (57%), ileocecal region (26%), ascending colon (9%), transverse colon (6%) and descending colon (2%).³⁻⁵ The condition can occur at any age, with incidence being slightly higher in males.⁶ The pathogenesis is either due to torsion of the large and pedunculated appendix epiploicae, or spontaneous thrombosis in the venous flow, resulting in ischemia, and necrosis.³ The patients usually presents with acute onset lower abdominal pain, left or right, which is aggravated by movements. Abdominal examination reveals localized tenderness with guarding. Blood investigations may show an elevated leukocyte count.^{7,8} Imaging modalities such as abdominal ultrasound or computed tomography scan aid in the diagnosis. The condition is self-limiting, and patients recover spontaneously within 1 week to 1 month time. Oral non-steroidal anti-inflammatory drugs are the standard line of management once the diagnosis is confirmed.¹ Antibiotics are rarely warranted. Surgical interventions are indicated only in case of complications such as secondary abscess, intestinal occlusions or inflammation-induced adhesions, and in cases of recurrence of symptoms with the conservative management.^{6,9}

To conclude, epiploic appendagitis is an uncommon cause of acute abdomen, and can mimic other conditions like appendicitis, cholecystitis and diverticulitis.¹⁰⁻¹² An awareness of this condition is essential in order to avoid unnecessary surgery and hospitalization.

Keywords: Epiploic appendagitis; acute abdomen; abdominal pain

**Robin George Manappallil¹, Della Harigovind²,
Unnikrishnan Vijayamukundan³**

¹Consultant, ²Resident, Department of Internal Medicine, Baby Memorial Hospital, Calicut, Kerala, India, ³Senior Consultant, Department of Radio Diagnosis and Imaging, Baby Memorial Hospital, Calicut, Kerala, India

Address for Correspondence:

Dr. Robin George Manappallil, Department of Internal Medicine,
Baby Memorial Hospital, Calicut - 673 009, Kerala, India.

Tel.: 0091-8547753396.

E-mail: drrobingeorgempl@gmail.com

REFERENCES

1. Ozdemir S, Gulpinar K, Leventoglu S, Uslu HY, Turkoz E, Ozcay N, et al. Torsion of the primary epiploic appendagitis: A case series and review of the literature. *Am J Surg* 2010; 199:453-458.
2. Sangha S, Soto JA, Becker JM and Farraye FA. Primary epiploic appendagitis: An underappreciated diagnosis. A case series and review of the literature. *Dig Dis Sci* 2004; 49:347-350.
3. Boardman J, Kaplan KJ, Hollcraft C and Bui-Mansfield LT. Radiologic-pathologic conference of Keller Army Community Hospital at West Point, the United States Military Academy: Torsion of the epiploic appendage. *AJR Am J Roentgenol* 2003; 180:748.
4. Thomas JH, Rosato FE and Patterson LT. Epiploic appendagitis. *Surg Gynecol Obstet* 1974; 138:23-25.
5. Rioux M and Langis P. Primary epiploic appendagitis: Clinical, US, and CT findings in 14 cases. *Radiology* 1994; 191:523-526.
6. Sand M, Gelos M, Bechara FG, Sand D, Wiese TH, Steinstraesser L, et al. Epiploic appendagitis - Clinical characteristics of an uncommon surgical diagnosis. *BMC Surg* 2007; 7:11.
7. Choi YU, Choi PW, Park YH, Kim JI, Heo TG, Park JH, et al. Clinical characteristics of primary epiploic appendagitis. *J Korean Soc Coloproctol* 2011; 27:114-121.
8. Vinson DR. Epiploic appendagitis: A new diagnosis for the emergency physician. Two case reports and a review. *J Emerg Med* 1999; 17:827-832.
9. Singh AK, Gervais DA, Hahn PF, Sagar P, Mueller PR and Novelline RA. Acute epiploic appendagitis and its mimics. *Radiographics* 2005; 25:1521-1534.
10. Ejaz T, Saad E, Nabil A and Slattery J. Caecal Epiploic Appendagitis Masquerading Clinically as an Acute Appendicitis: A Case Report and Brief Literature Review. *Case Reports in Surgery* 2019; vol. 2019, Article ID 6508642, 3 pages.
11. Chan E, El-Banna A. A case report of epiploic appendagitis as a mimic of acute cholecystitis. *Int J Surg Case Rep* 2018; 53:327-329.
12. Plummer R, Sekigami Y, Chen L and Yoo J. Epiploic Appendagitis Mimicking Recurrent Diverticulitis, Case Reports in Surgery 2018; vol. 2018, Article ID 1924067, 3 pages.

Authors Contribution:

RGM- Concept and design of case report, reviewed the literature, manuscript preparation and treating Physician; **DH-** Critical revision of manuscript and Radiologist; **UV-** Resident in-charge.

Orcid ID:

Dr. Robin George Manappallil -  <http://orcid.org/0000-0003-3973-6800>

Source of Support: Nil, **Conflict of Interest:** None declared.