

Parkinsonism following basal ganglia infarction in Dengue fever



Robin George Manappallil¹, Pradeep Kumar V. G.², Apurva Rao K. S.³

¹Consultant, Department of Internal Medicine, ²Senior Consultant, Department of Neurology, ³Resident, Department of Internal Medicine, Baby Memorial Hospital, Calicut, Kerala, India

Submitted: 05-02-2019

Revised: 12-02-2019

Published: 01-03-2019

ABSTRACT

Dengue fever is an acute febrile viral illness characterized by severe headache, myalgia, arthralgia, rashes, leucopenia and thrombocytopenia. Patients may face haemorrhagic complications like gastrointestinal bleeding, intracranial haemorrhage, menorrhagia, hematomas, hematuria and massive epistaxis. Ischemic stroke in dengue fever is a rare scenario; and Parkinsonism following basal ganglia infarction in dengue fever, to the best of our knowledge, has not been reported yet.

Key words: Dengue fever; Parkinsonism; Basal ganglia; Infarction; Vasculitis

Access this article online

Website:

<http://nepjol.info/index.php/AJMS>

DOI: 10.3126/ajms.v10i2.22614

E-ISSN: 2091-0576

P-ISSN: 2467-9100

INTRODUCTION

Dengue fever (DF), according to the WHO, is the most rapidly spreading viral infection in the world. It is an acute febrile illness caused by 5 distinct subgroups of dengue viruses (DEN 1-5) and transmitted by *Aedes aegypti* mosquitoes. Patients present with headache, retro-orbital pain, arthralgia/myalgia, rash and haemorrhagic manifestations.¹ Neurological complications like ischemic strokes are uncommon. Parkinsonism is a clinical syndrome characterized by bradykinesia, tremors, rigidity and postural instability. It may be idiopathic (Parkinson's disease) or secondary to drugs, toxins, tumours, vascular events or infections.² The case being reported is of a middle aged male with DF who developed Parkinsonism following basal ganglia infarction.

CASE PRESENTATION

A 48 year old male, fisherman by occupation, presented with 5 days history of high grade fever and myalgia. He was not a known case of any comorbid condition and was not on any medications. On examination, he was conscious, oriented and febrile (101°F). His heart rate was 100/minutes and regular, blood pressure 120/70 mmHg

and respiratory rate 20/minute with saturation 98% in room air. His systemic examinations were normal. His blood investigations showed leucopenia (2500 cells/cumm with neutrophils 40% lymphocytes 56% eosinophils 4%), thrombocytopenia (90,000 cells/cumm) and elevated liver enzymes (SGOT 224 U/L and SGPT 110 U/L). Serum Dengue NS1 antigen and IgM were positive. Smear for malaria, Weil Felix, viral markers (HIV, HBsAg, anti HCV) and leptospirosis serology were negative. Renal functions, electrolytes, HbA1c, PT/INR, APTT and urine microscopy were normal. Chest X-ray and ECG were also normal.

Over the next 2 days he had a further decline in platelet counts with no bleeding manifestations. On day 4 of admission, he had an acute onset of delirium and became mute. He was afebrile with stable vitals. Neurological examination revealed bilateral upper limb resting tremors, cogwheel rigidity and bradykinesia. He had brisk deep tendon reflexes and bilateral extensor plantars. His thrombocytopenia worsened (15,000 cells/cumm), hemoconcentration was present (Hb 18.2 g/dL, PCV 53.4%) and APTT was mildly prolonged (test 38.6 seconds, control 23.3 seconds). MRI of brain revealed microinfarcts involving the basal ganglia (Figure 1). CSF analysis was normal (WBC 3, protein 35 mg/dL, glucose 60 mg/dL), with Dengue IgM, AFB stain, Gram stain and culture, India

Address for Correspondence:

Dr. Robin George Manappallil, Consultant, Department of Internal Medicine, Baby Memorial Hospital, Calicut, Kerala 673004, India.

Tel: 0091-8547753396. E-mail: drrobingeorgeempl@gmail.com

© Copyright AJMS

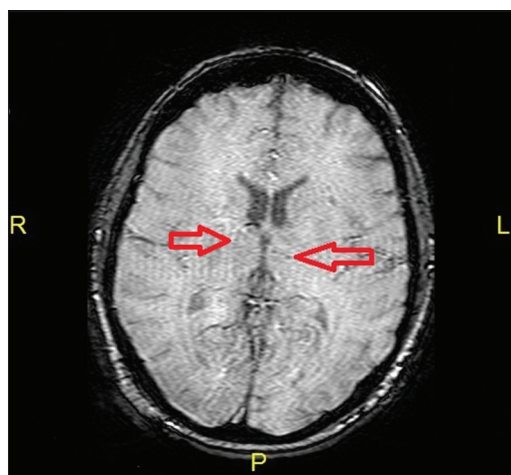


Figure 1: MRI brain showing microinfarcts in the basal ganglia

ink, ADA, JEV RNA PCR and HSV 1 & 2 DNA PCR being negative. Blood cultures were sterile. Serum ammonia and electrolytes were normal, and ANA profile was negative.

Initially, he was managed symptomatically with intravenous fluids, paracetamol, folic acid supplements and pantoprazole. Following the development of Parkinsonism, he was started on intravenous dexamethasone (8mg q6h) which was continued for 5 days. Levodopa 100 mg with carbidopa 10 mg was given at thrice daily frequency. Platelet and fresh frozen plasma transfusions were given. Intravenous fluids and other supportive measures were continued.

By day 9 of admission, he became conscious and oriented. His tremors disappeared and limb rigidity started decreasing. His hemoconcentration improved, and platelet counts and liver enzymes started normalizing. By day 14, he was stable and discharged on levodopa 100 mg and carbidopa 10 mg (thrice daily) and tapering doses of oral prednisolone. Diabetic diet was advised. On review after 3 weeks, he was asymptomatic. His complete blood count and liver functions were normal. Fasting lipid profile showed mild dyslipidemia. Blood glucose levels and TSH were normal. Prednisolone was stopped. Antiparkinsonism medications were continued with addition of rosuvastatin (5 mg at night). His review was scheduled after 1 month; but he was lost for follow up.

DISCUSSION

DF comprises of 3 phases. Fever, headache, myalgia and leucopenia are seen during the initial febrile phase, which lasts for 2 to 7 days. This is followed by the critical phase, where patients are afebrile and face hemoconcentration, capillary leakage and systemic complications. This phase lasts for 24 to 48 hours; following which there is a gradual resorption of the fluid from the extracellular compartment,

rising trend in platelet counts and stabilisation of haematocrit levels. This is called the recovery phase.¹

Over the recent past, DF has been associated with several neurological complications like brachial neuritis, encephalopathy, Guillain Barre syndrome, hypokalemic paralysis, myositis, Opsoclonus-myoclonus syndrome, acute disseminated encephalomyelitis and cerebellar ataxia.^{3,4} Oligoclonal bands have been noticed in the CSF of patients with viral encephalitis, suggesting an immune-mediated mechanism.^{5,6} Viral Parkinsonism may resemble idiopathic Parkinson's disease, but these patients are unlikely to respond to antiparkinsonism medications like levodopa and dopamine agonists.⁷ Immunosuppression with steroids may be required in selected cases. Parkinsonism in DF is uncommon, and may be a consequence of post-infectious immune-mediated response.

Basal ganglia infarcts can present with speech, memory, motor and/or sensory abnormalities. Behavioural changes like abulia, apathy, akinesia, amnesia, disinhibition and hemineglect have also been reported.⁸⁻¹²

Intracranial hemorrhages can occur in DF due to thrombocytopenia; but ischemic stroke is a rare complication.¹³⁻¹⁵ A probable mechanism for the development of ischemic stroke in DF is meningovascularitis.¹³ Moreover, a transient hypercoagulable state which occurs during DF may also cause ischemia. In our patient, the development of Parkinsonism was following infarction in the basal ganglia, which could have been the result of vasculitis. He was treated with steroids and antiparkinsonism medications, following which he recovered. Antiplatelets were avoided.

CONCLUSION

DF usually presents with bleeding manifestations. Ischemic stroke in DF is uncommon; and occurs probably due to meningovascularitis or due to development of a transient hypercoagulable state. Parkinsonism in DF due to microinfarcts involving the basal ganglia is an unreported scenario.

REFERENCES

1. WHO. Dengue: guidelines for diagnosis, treatment, prevention and control. New edition. Geneva: World Health Organization; 2009.
2. Olanow CW, Schapira AHV and Obeso JA. Parkinson's Disease and Other Movement Disorders. In: Kasper, Fauci, Hauser, Longo, Jameson, Loscalzo eds. Harrison's Principles of Internal Medicine. 19th ed. McGraw Hill education 2015. pp. 2609-2618.
3. Verma R, Sharma P, Garg RK, Atam V, Singh MK and Mehrotra HS. Neurological complications of dengue fever: Experience from a tertiary center of north India. *Annals of Indian Academy of Neurology* 2011; 14(4):272-278.

4. Karunarathne S, Udayakumara Y and Fernando H. Epstein-Barr virus co-infection in a patient with dengue fever presenting with postinfectious cerebellitis: a case report. *J Med Case Rep* 2012, 6: 43.
5. Blunt SB, Lane RJM, Turjanski N and Perkin GD. Clinical features and management of two cases of encephalitis lethargica. *Mov Disord* 1997; 12:354-359.
6. Dale RC, Church AJ, Surtees RAH, Lees AJ, Adcock JE, Harding B, et al. Encephalitis lethargica syndrome: 20 new cases and evidence of basal ganglia autoimmunity. *Brain* 2004; 127:21-33.
7. Jang H, Boltz DA, Webster RG and Smeyne RJ. Viral parkinsonism. *Biochimica et Biophysica Acta (BBA) - Molecular Basis of Disease* 2009; 1792:714-721.
8. Bhatia KP and Marsden CD. The behavioral and motor consequences of focal lesions of the basal ganglia in man. *Brain* 1994; 117: 859-876.
9. Mendez MF, Adams NL and Skoog-Lewandowski K. Neurobehavioral changes associated with caudate lesions. *Neurology* 1989; 39: 349-354.
10. Kumral E, Evyapan D and Balkir K. Acute caudate vascular lesions. *Stroke* 1999; 30: 100-108.
11. Caplan LR. Caudate infarcts. *Arch Neurol* 1990; 47: 133-143.
12. Wagner SJ and Begaz T. Basal ganglion stroke presenting as subtle behavioural change. *BMJ Case Reports* 2009; <http://dx.doi.org/10.1136/bcr.10.2008.1139>.
13. Liou LM, Lan SH and Lai CL. Dengue fever with ischemic stroke: A case report. *Neurologist* 2008; 14:40-42.
14. Mathew S and Pandian JD. Stroke in patients with dengue. *J Stroke Cerebrovasc Dis* 2010; 19:253-256.
15. Manappallil RG. Ischemic stroke following Dengue fever: A case report. *Asian Journal of Medical Sciences* 2015; 7(2): 107-108.

Authors Contribution:

RGM - Concept and design of case report, reviewed the literature with critical revision, manuscript preparation and treating physician; **VGPK**- Critical revision of manuscript and treating Neurologist; **ARKS**- Resident in charge.

Work attributed to:

Department of Internal Medicine, Baby Memorial Hospital, Calicut, Kerala 673004, India.

Orcid ID:

Dr. Robin George Manappallil - <http://orcid.org/0000-0003-3973-6800>

Source of Support: Nil, **Conflict of Interest:** None.